

## Immediate implant– An esthetic rescue- Case series

S. Gopalakrishnan<sup>1\*</sup>, Gomathi G.D<sup>2</sup>, G. Kanimozhi<sup>3</sup>, W.R. Gnanasagar<sup>4</sup>

<sup>1</sup>Professor, <sup>2</sup>Post Graduate, <sup>3</sup>General Dentist (Private Practitioner), <sup>4</sup>Senior Lecturer, <sup>1,2,4</sup>Dept. of Periodontics, <sup>1,2,4</sup>Thai Moogambigai Dental College and Hospital, Chennai, Tamil Nadu, India

### Abstract

Extraction followed by placement of immediate implant has become a reliable and time saving method of esthetic and functional rehabilitation of a patient. Achieving good primary stability with preservation of hard and soft tissue is the key to successful placement of immediate implant. With the advent of immediate single-stage implant placement and immediate prosthesis fabrication, the edentulous patients can walk out of the clinic with “Teeth within a day”. Refining clinical protocols, applying sound biomechanical principles, improving implant design, with new implant surfaces have resulted in the increased use of immediate implant. However there are chances of implant failure due to greater crestal bone loss around the healing implants resulting from traumatic extraction. This could be minimized or prevented by atraumatic extraction procedure. Many clinical trials reported survival rates of immediately loaded implants similar to that of two-stage unloaded healing approaches. This article throws a light on atraumatic extraction & various techniques of atraumatic extraction, advantages, disadvantages and success criteria for immediate implant loading. Three cases with different techniques of atraumatic extraction of tooth and immediate implant rehabilitation is reported.

**Keywords:** Atraumatic extraction, Techniques, Immediate implant loading, Advantages and disadvantages of immediate implant loading.

### Introduction

Immediate replacement of missing teeth is what people demand now-a-days. Immediate implants are placed into freshly extracted sockets following extraction. The placement of implants in extraction sockets was first described by Schulte & Heimke. (1976) Schulte et al (1978) referred this procedure as ‘immediate implant’. Loss of single tooth in the esthetic region is the most common indication for immediate implant placement.<sup>1</sup> Extraction followed by immediate implant placement not only improves esthetics but also preserves bone. Placing two-stage implant in the aesthetic zone is a challenging task to the clinician as it is time consuming and involves secondary surgical exposure. Tooth loss not only results in bone resorption but also causes loss of soft-tissue which must be evaluated carefully before treatment planning. Severe bone loss requires ridge augmentation which is a time consuming procedure. Exposure of alveolar bone causes alteration of the biologic width that has to be reestablished. Traumatic extraction of teeth results in damage to the periodontium leading to loss of hard and soft tissues. This will eventually lead to failure of implant. Atraumatic extraction of the teeth plays a key role for successful placement of immediate implants which refers to a process of tooth removal with minimal damage to the periodontal tissues. In contrast, placing immediate implant with a provisional restoration may have some negative consequences. According to patient’s view, the losing tooth in the esthetic region is often traumatic. Esthetics and phonetics is compromised during the traditional two-stage placement. Healing period more demanding both surgically and prosthetically compared to

the conventional placement technique. However, waiting period (4-6 months) for osseointegration and the prosthesis fabrication following a two stage surgery were the biggest disadvantage. With the advent of immediate single stage implant placement and immediate prosthesis fabrication, the edentulous patients can receive the replacement in the same appointment. Refining clinical protocols, applying sound biomechanical principles, improving implant design, with new implant surfaces have resulted in the increased use of immediate implant.

### Immediate loading

Immediate loading of implants reduces secondary surgery and aids in providing temporary restoration at the same visit for the patient. Immediate loading on reduced surface area implants increases soft-tissue interface between bone and implant that has better clinical survival.<sup>2</sup> A direct bone-implant interface when developed, had survival for more than 20 years.<sup>3</sup> Tarnow et al<sup>4</sup> reported success of immediately loaded threaded implants with a fixed prosthesis in 10 consecutive cases over 5 years. However uncontrolled systemic conditions like diabetes, patients with oral para-functional habits and heavy smoking are absolute contraindication for immediate implant. A study on 23 periodontally compromised patients suggested that immediate loading implant is a predictable technique with a higher survival rate for provisional and permanent prosthesis<sup>6</sup>

\*Corresponding Author: S. Gopalakrishnan, Dept. of Periodontics, Thai Moogambigai Dental College and Hospital, Chennai, Tamil Nadu, India

Email: [gopalakrishnan\\_perio@ymail.com](mailto:gopalakrishnan_perio@ymail.com)

<http://doi.org/10.18231/j.aprd.2019.019>

### Selection criteria for immediate implants

Proper selection of the case determines the success of the immediate implant. Ideal case selection is dependent on the clinician's view and patient's preferences.

#### Inclusion criteria

1. Vertical fracture of the tooth.
2. No periapical pathology or inflammation at implant site.
3. Adequate bone density and height for primary stability.
4. The healthy patients with good oral hygiene.
5. Good gingival contour

#### Exclusion criteria

1. Grossly decayed tooth that is infected.
2. Periapical pathology or inflammation at the site of the implant placement.
3. Periodontally compromised teeth.
4. Severe hard and soft tissue defect.
5. Patients with para-functional habits

#### Criteria for successful implants (Salama et al.<sup>9</sup>)

1. Good bone quality in the area of the implant (anterior area of the mandible)
2. The use of implants with rough surfaces (e.g. TPS coating, microstructuring / microinterlock)
3. If possible bi-cortical fixation of the inserted implants for improved stabilization
4. Avoidance or reduction of extensions in the case of provisional restorations
5. An occlusion concept for axial loading as far as possible

#### Atraumatic tooth removal/extraction

Atraumatic Extraction is the process of extracting a tooth in the most delicate and conservative technique which refers to removal of tooth from the socket with no or minimal damage to the surrounding periodontal structures. Extraction of anterior tooth results in significant loss of hard and soft tissue volume (bucco-lingual and mesio-distal directions) that compromises the esthetic results of prosthesis. Extraction techniques causing minimal or no trauma to the remnant tissues followed by immediate implant placement minimizes the changes that occurs after extraction. Bone volume, density, osteotomy technique will influence the level of stability of the implant.s.

#### Various AIDS in atraumatic surgical removal

1. Using surgical Drills (Yalcin S et al)<sup>10</sup>
2. Using Periotome (Babbush CA)<sup>11</sup>

Tabale 1:

Author	Type to Study	No. Patients	No. Implants loaded	Follow up Years	Lost Implants	Survival Rate%
Ericsson et al	Prosp	14	14	1	2	86%
Hui	Prosp	24	24	1-15 Month	0	100%
Calandriello et al	Prosp	44	50	6-12 Month	0	100%

3. Using X-Trac System- The Easy X Trac systems consists of 3 different sized drills and 4 different sized screws along with a specially designed extractor and protector plates designed to lift the tooth from the socket without any rotary or tilting movement.

#### Clinical presentation

The following clinical presentations illustrate the different techniques of atraumatic surgical removal of root stumps and placement of immediate implants.

#### Case Report-1

A male patient aged 22 years reported with the fractured clinical crown at the level of cemento enamel junction (Fig. 1,2) Since the patient wanted immediate replacement for his teeth, the treatment plan included extraction of root stump followed by implant placement and provisional crown. Initially airtor was used to drill the orifice of the root stump (Fig. 3) and later by using surgical drill the root stump was removed (Fig. 4,5).The extracted socket was filled with osseograft bone graft material (Fig. 6) and immediate implant was placed and healing cap given(Fig. 7,8). After three months permanent restoration was done.

#### Case Report-2

In the second case a female patient aged 18 years reported with the complaint of mobility in the tooth after trauma. The tooth was removed using a periotome (Fig. 9,10) and the patient was facing embarrassing because the tooth gap was visible when she smiled. She requested an immediate esthetic solution with fixed restoration. So immediate single piece implant was placed (Fig. 11) and temporary provionalisation was done using adora system (Fig. 12).

#### Case Report-3

In the third case, similar to the first case a male patient of age 30 years reported with complaint of fractured anterior tooth at cement-enamel junction. (Fig. 13,14).As we decided to preserve the soft and hard tissue and to have good subgingival emergence profile which can be of significant benefit in providing stability to perimplant soft tissues, the root stump was planned to remove atraumatically. The root stump was removed using Xtrac system (Fig. 15,16), the immediate implant placement was done (Fig. 17) and ceramic crown placed (Fig. 18).

#### Case 1

Rocci et al	Retro	27	27	3	5	81.5%
Lorenzoni et al	Retro	12	12	1	0	100%
Degidi et al	Retro	111	111	5	5	95%
Ostman et al	Prosp	14	14	1	0	100%
Total		246	252	-	-	
Published articles on immediate loading of single-tooth maxillary and mandibular restoration						

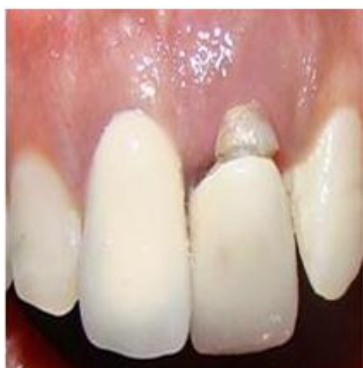

Fig. 1: Fractured crown in relation to I1

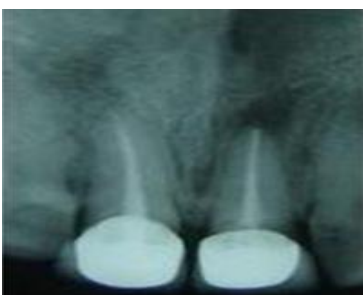

Fig. 2: Radiograph showing fracture at cemento-enamel junction

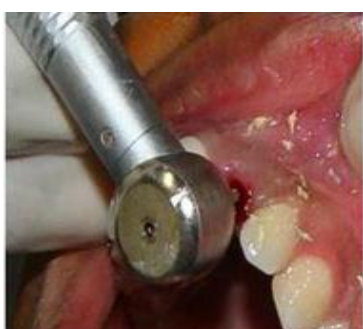

Fig. 3: Airrotor drilling the orifice of the root stump

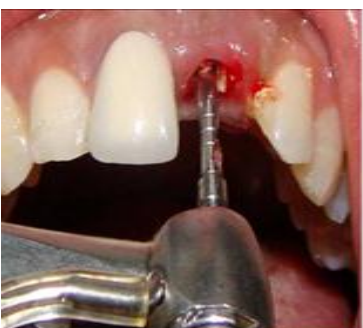

Fig. 4: Implant drill to remove the root stumps

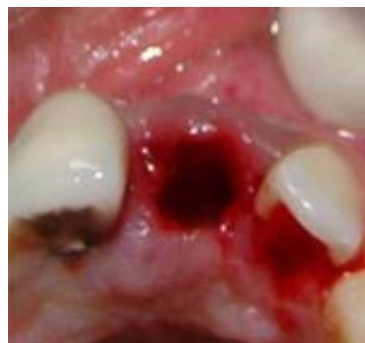

Fig. 5: Clinical picture of extracted socket

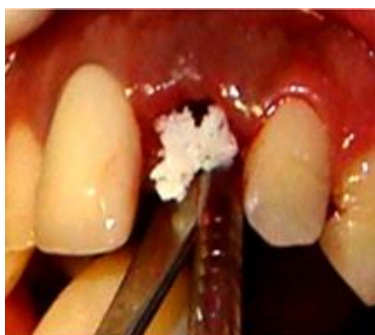

Fig. 6: Osseograft used for filling the socket

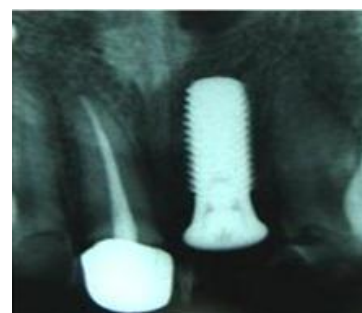

Fig. 7: Radiograph showing immediate implant

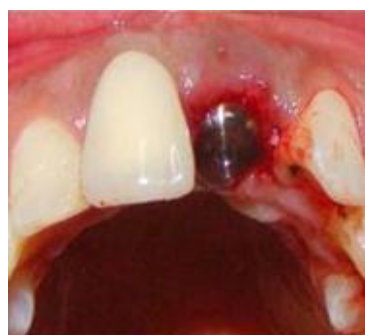
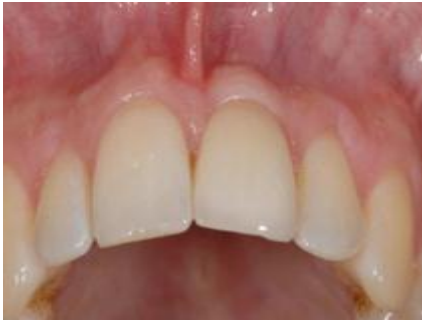
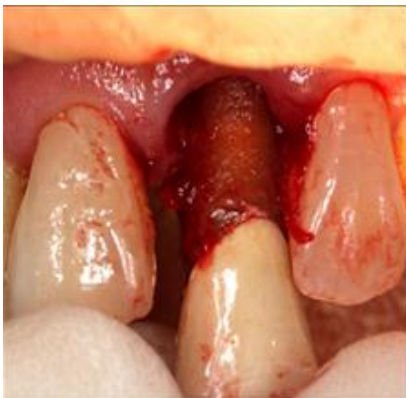Fig. 8: Clinical picture showing heading cap

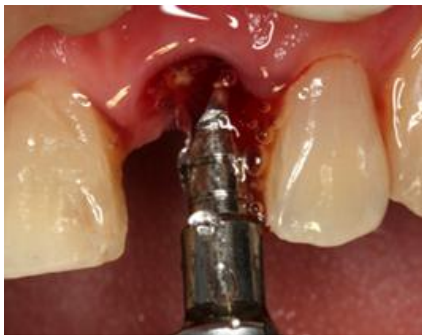

**Fig. 8a:** Final restoration with ceramic crown

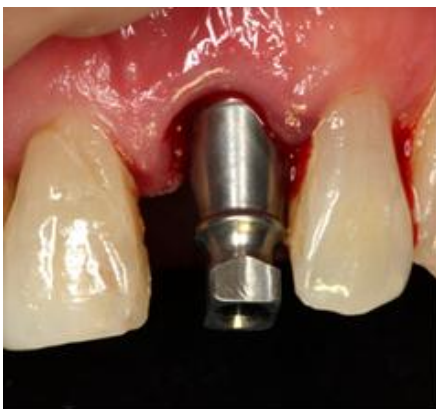**Case 2**



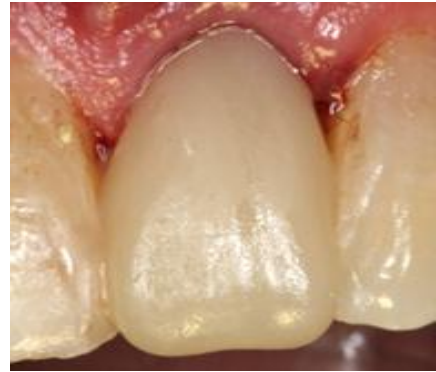**Fig. 9:** Tooth removed using periosteal elevator



**Fig. 10:** Implant drill widening the socket

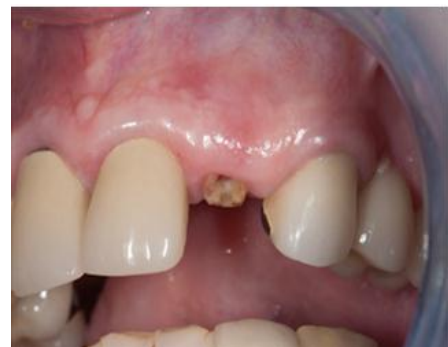

**Fig. 11:** Placement of single piece implant

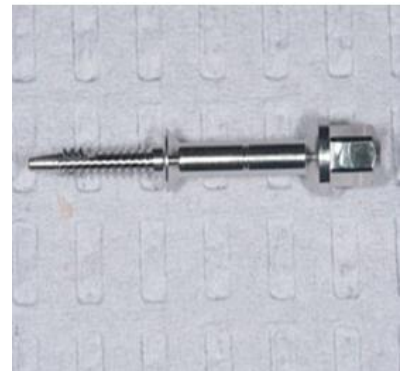


**Fig. 12:** Final restoration using adora crown

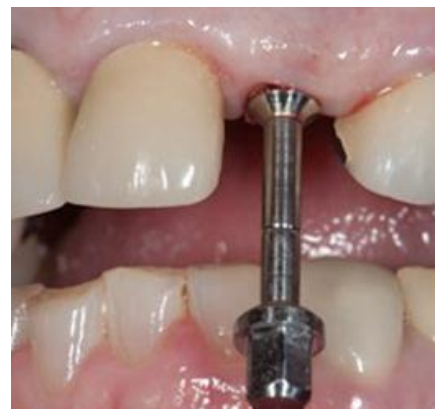**Case 3**



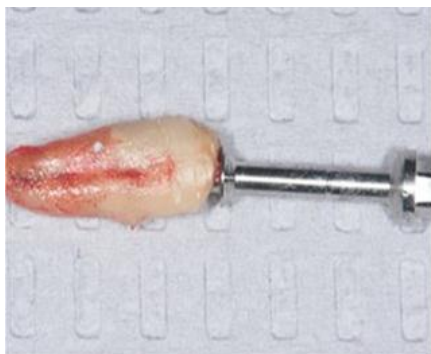**Fig. 13:** Clinical picture showing root stumps



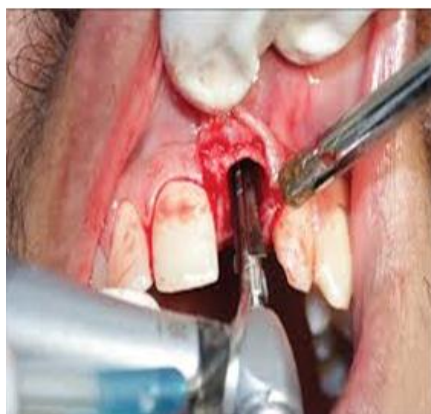**Fig. 14:** Xtrac system



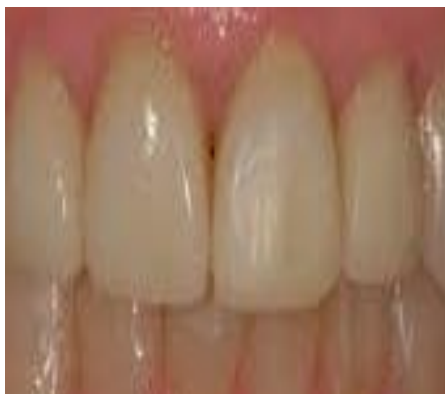**Fig. 15:** Removing root stump using xtrac system



**Fig. 16:** Removed root stump



**Fig. 17:** Implant placed



**Fig. 18:** Final restoration with ceramic crown

### Clinical relevance

Sound bone and sufficient soft tissue are the main criteria for long term stability of implant. Previous studies have provided evidence for success of immediate implants than conventional two staged implant. Immediate loading provides the patient with functional, aesthetic, and psychological expectation, and helps to maintain the soft and hard tissue.

### Discussion

For the long term success of immediate implants, an appropriate diagnosis and treatment plan is essential. Clinical and radiographic analysis of the proposed implant sites should be done prior to implant placement. The

immediate implant has become popular among patients with increased acceptance because of the reduction in the number of surgical procedures. Implants placed in the fresh extracted sites reduce the need for angled abutments and guides the clinician to place final restoration in the same location without affecting the esthetics. Osseointegration is much better in immediate implants as the width and height of the alveolar bone are preserved. Immediate implants are predictable,<sup>5,12</sup> but are also associated with the risk of greater crestal bone loss around the healing implants.<sup>13</sup> The immediate loading was found to interfere with the healing of necrotic bone that was created by the surgical trauma in the course of new bone formation. Hence successful implants with greater than 5-mm soft tissue pockets may be more often a result of immediate loading. The non-functional immediate transitional restoration provided in the above cases reduces the biomechanical risk of overload.<sup>14</sup> Ideally, the bone density should be D1, D2, or D3 so the strength, bone contact, and modulus of elasticity are great enough to accept the initial load.<sup>5,9,15</sup> Many clinical reports revealed similar survival rates of healing between immediately implants and conventional implants<sup>16-18</sup>. However, these findings are not enough to prove that conventional two staged implants are no longer necessary. Moreover immediate implant is highly technique sensitive that require better clinician's skill.

### Conclusion

Most advanced way to replace missing teeth is dental implant which replicates the natural tooth root. Based on the literature, immediate implant placement with immediate loading could be a valuable option for patients requiring restoration in the esthetic area. "Though an eye for an eye is considered brutal, a tooth for a tooth is what people want today". Immediate implant placement helps to fulfill patient's needs.

### Source of Funding

None.

### Conflict of Interest

None.

### References

1. Cornelini R, Cangini F, Covani U. Immediate loading of implants with 3-unit fixed partial dentures: a 12- month clinical study. *Int J Oral Maxillofac Implants* 2006;21(6):914-8.
2. Misch CE. Non-functional immediate teeth in partially edentulous patients: A pilot study of 10 consecutive cases using the Maestro™ Dental Implant system. *Compendium* 1998(spl. Issue);19:25-36.
3. Linkow LI, Donath K, Lemons JE. Retrieval analysis of a blade implant after 231 months of clinical function. *Implant Dent* 1992;1:37-43.
4. Tarnow DP, Emtiag S, Classi A. Immediate loading of threaded implants at stage one surgery in edentulous arches. Ten consecutive case reports with 1 to 5 year data. *Int J Oral Maxillofac Implants* 1997;12:319-24.
5. Misch CE. Non-functional immediate teeth in partially edentulous patients: A pilot study of 10 consecutive cases

- using the Maestro™ Dental Implant system. *Compendium* 1998;(spl. Issue);19:25-36.
6. Alves CC, Correia AR. Immediate Implants and Immediate Loading in Periodontally Compromised Patients—A 3-Year Prospective Clinical Study. *Int J Periodontics Restor Dent* 2010;30:447-55
  7. Weber HP, Buser D, Fiorellini JP. Radiographic evaluation of crestal bone levels adjacent to non submerged titanium implants. *Clin Oral Implants Res* 1992;3:181-8.
  8. Gotfredson K, Hjorting-Hansen E. Histologic and histomorphometric evaluation of submerged and non submerged titanium implants. In: Laney WR, Tolman DE (eds): Tissue integration. *Oral, Orthop Maxillofac Reconstr* Chicago, Quintessence 1990; 31-40
  9. Salama H, Rose LF, Salama M et al. Immediate loading of bilaterally splinted titanium root form implants in fixed prosthodontics. A technique re-examined: two case reports. *Int J Periodontics Restor Dent* 1995;15:344-61.
  10. Yalcin S, Aktas I, Emes Y, Kaya G, Aybar B, Atalay B. A technique for atraumatic extraction of teeth before immediate implant placement using implant drills. *Implant Dent* 2009;18(6):464-72
  11. Babbush CA. A new atraumatic system for tooth removal and immediate implant restoration. *Implant Dent* 2007;16(2):139–145. doi: 10.1097/ID.0b013e3180581656.
  12. Fabbro MD, Testori T, Francetti L. Systematic review of survival rates for immediately loaded dental implants. *Int J Periodontics Restor Dent* 2006;16:249-63.
  13. Chang TL, Raoumanas ED, Klokkevold PR, Beumer J. Biomechanics, Treatment planning and prosthetic considerations. In Newman MG, Takei HH, Klokkevold PR, Carranza FA (eds). *Clinical Periodontology*. Saunders, Louis 10th edition 2006 p.1167-1181.
  14. Misch C.E. A bone quality-based implant system: first year of prosthetic loading. *J Oral Implantol* 1999;25:185-97.
  15. Misch CE, Degidi M. Immediate loading implants with fixed prosthesis in the completely edentulous patient. *J Clin Implant Res* 2003;5:100-203.
  16. Schenk RK, Buser D. Osseointegration: a reality. *Periodontol* 2000. 1998;17:22-35.
  17. Khorshid HE, Hamed HA, Aziz EA. The effect of two different immediate loading protocols in implant supported screw-retained prostheses. *Implant Dent* 2011; 20: 157-166
  18. Nkenke E, Lehner B, Fenner M, Roman FS. Immediate versus delayed loading of dental implants in the maxillae of minipigs: follow-up of implant stability and implant failures. *Int J Oral Maxillofac Implants* 2005;20:39-47.
  19. Cannizzaro G, Leone M. Restoration of partially edentulous patients using dental implants with a microtextured surface: a prospective comparison of delayed and immediate full occlusal loading. *Int J Oral Maxillofac Implants* 2003;18:512-2.

**How to cite this article:** Gopalakrishnan S, Gomathi GD, Kanimozhi G, Gnanasagar WR. Immediate implant– An esthetic rescue- Case series. *Ann Prosthodont Restor Dent* 2019;5(3):80-5.