

Immediate Overdenture

Parag Bhojar¹, Suryakant C. Deogade^{2,*}

¹Assistant Professor, ²Associate Professor, ^{1,2}Dept. of Prosthodontics, Government Dental College and Hospital Nagpur, Maharashtra, India

***Corresponding Author: Suryakant C. Deogade**

Email: dr_deogade@yahoo.co.in

Abstract

Partially edentulous patients are often planned for prosthetic replacement on the basis of their poor economy rather than actual indicated treatment strategy. Immediate overdenture is one of such strategic planning where patients are rehabilitated with combination of two conventionally different complete dentures. Preventive prosthodontics believes in preservation of residual alveolar ridge at all levels, wherein; remaining natural teeth are saved, restored and used as abutments for complete denture ultimately preserving the bone. One such approach in the form of case report is presented where the patient was treated with mandibular immediate complete denture which was supported by few remaining natural teeth after undergoing root canal therapy.

Keywords: Overdenture, Immediate denture, Extraction, Template.

Introduction

Edentulousness resulting from multiple extractions of teeth usually causes psychological and social problems to the concerned patient. Immediate denture enables such patients to continue in engaging the social routine without undergoing the period of edentulous state.¹ Other benefits of immediate dentures are that it prevents tissue collapse and protects extraction sites by acting as matrix or scaffold, thus reducing bleeding and post-extraction pain.² This option of treatment helps in reducing alveolar ridge resorption, thus forming smooth, well rounded ridges and resilient soft mucosa.³⁻⁵ Lip and cheek support is retained so that esthetics of the face is more easily restored and patient finds it easier for adjusting phonetics.² However, patient undergoing immediate denture therapy must function without posteriors in occlusion until the ridges have crossed initial healing phase and the prosthesis has been fabricated.⁶ Maxillomandibular jaw relation becomes little difficult to record in absence of posterior teeth. Even the final treatment outcome cannot be predicted before the completion of the prosthesis as it may not achieve its original esthetics.⁷ Multiple extractions required for immediate denture may cause trauma, pain and swelling that further deteriorate the patient's adaptation to new denture.⁸ Adjusting the prosthesis in a bloodied area develops an unpleasant experience for the operator. Interim relining after 2-3 months becomes cumbersome. Number of visits for maintenance may hike the cost of the entire treatment.⁸

Preventive prosthodontic stresses on preservation of remaining natural root or roots so that these can be utilized as abutments for overdenture. Such overdenture improves retention and stability of the prosthesis, improves proprioception and offers feeling of naturalness to the patient. In esthetically conscious patients, immediate dentures can also be planned so that their social activities are not restricted. Different treatment options such as overdenture, immediate denture and implant-supported denture have their own indications and contraindications.⁹⁻¹² Overdentures fulfil more of the biological aspects whereas

immediate dentures have more of functional as well as psychological importance.

Immediate overdenture fulfills both the aspects of importance as served by overdenture and immediate denture individually. Immediate denture can be planned by removing all the affected teeth or by preserving a few teeth to be used as overdenture abutment. When both these concepts are applied i.e. immediate overdenture, it offers additional benefits such as temporomandibular joint proprioception is maintained, residual alveolar bone is preserved.¹³⁻¹⁵ However, several disadvantages associated with this combined approach are the same as that of immediate dentures. Overall treatment cost is increased due to involvement of endodontic treatment of remaining potential overdenture abutments. Overcontouring of denture is the most common disadvantage of this combined approach. This approach often needs tissue conditioning or rebasing.¹⁶

The main aim of this clinical report was to discuss all the laboratory and clinical steps that are used to restore a partially edentulous mouth with the combined approach of immediate denture and overdenture i.e. immediate overdenture. The metal copings were planned over selected overdenture abutments that were treated earlier endodontically.

Case Report

A male patient, aged 47 years, visited the department of prosthodontics for his disliking of his own existing dental status. His complaints were foul smelling mouth, and inability to chew the food. He also complained about his unsatisfactory esthetics and constantly lodging food debris in between his teeth. Intraorally, missing mandibular central incisors was noted. Extraoral examination revealed his square-tapered face with convex profile. Remaining teeth showed generalized mobility (Grade III) of all mandibular except left second and right first premolars (Fig. 1).

After thorough investigations (including radiographs) (Fig. 2) treatment plan was decided and discussed with the

patient. Treatment plan included metal copings with selected overdenture abutments (mandibular left first premolar and right second premolar) followed after endodontic treatment. Preliminary impressions were made with irreversible hydrocolloid and the casts were poured with type II gypsum product. Mandibular final impression was obtained in zinc oxide eugenol impression paste and pick-up was done using irreversible hydrocolloid (Fig. 3). The final impression was poured in type III gypsum and the record base was fabricated in self-cured acrylic resin. The metal copings were cemented on the respective selected overdenture abutments (Fig. 4). The maxillomandibular relationship was recorded and transferred to a semi-adjustable Hanau Wide-vue articulator. Before processing the final prosthesis, an overimpression of mandibular master cast was done to fabricate the surgical template. This template was fabricated in clear acrylic self-cured resin (Fig. 5). Teeth arrangement was done and the final prosthesis was processed in heat-cured acrylic resin. The denture was finished and polished. Patient called for next appointment, at which the mandibular teeth except selected overdenture abutments were extracted. Using surgical template, necessary modifications was done in the post-extraction bone contour (Fig. 6). After suture placement, the patient was sent back to home with proper instructions regarding care and maintenance of mandibular immediate overdenture (Fig. 6). He was recalled as per the protocol and after 3-months the prosthesis was relined.

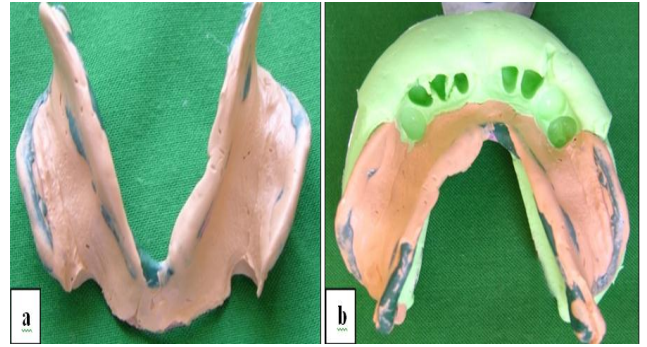


Fig. 3: (a & b): Final and pick-up impression

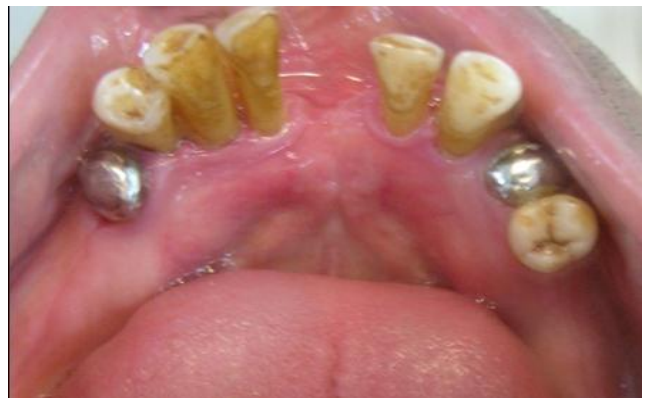

Fig. 4: Metal copings cemented over selected overdenture abutments

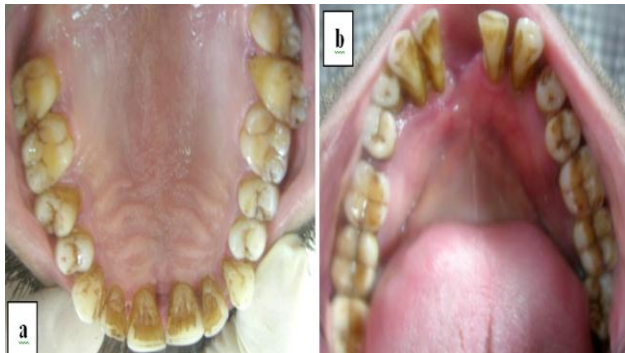

Fig. 1: (a & b). Intra oral view of maxillary and mandibular dentition



Fig. 5: Duplicated cast for fabricating clear acrylic surgical template

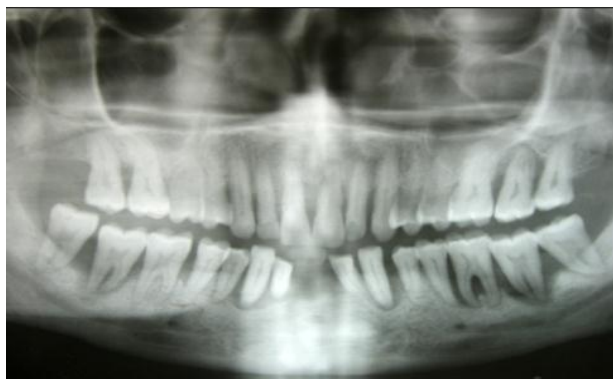

Fig. 2: Orthopantogram

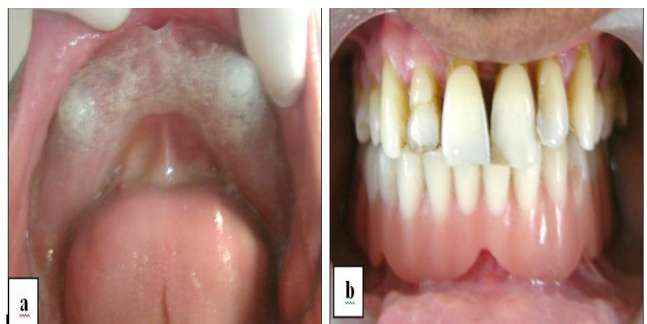


Fig. 6: (a & b): Clear acrylic surgical template in patient's mouth and denture in patient's mouth

Discussion

Overdenture approach have several benefits that include preservation of bone, enhanced masticatory function, and feel good psychology.¹⁷⁻²¹ Immediate denture concept allow the patient not to be exposed socially when their all the teeth are undergoing extractions. Immediate overdenture combines the concept of immediate denture and overdenture and thus offers the significant advantages of both the concepts. This approach defers the edentulism state as long as one can.

Selection of overdenture abutment plays an important role in minimizing the destructive effects of lateral/oblique forces on the residual alveolar ridge. The abutments selected for mandibular immediate overdenture offer more stability to denture.^{22, 23} Maintenance after delivering immediate overdenture plays a crucial role in fulfilling the objective of this combined approach. Negligence of proper care by the patient, as instructed by the clinician, can lead to the failure of the entire treatment offered to the patient.²⁴ In the discussed case report, the selected overdenture abutments were not in ideal location; however it was only mandibular immediate overdenture opposing maxillary natural dentition where the forces exerted by single denture were quite less. Therefore, this situation would not impede the stability of lower single denture. Preserving mandibular left first and right second premolars provided the significant benefits of psychological comfort and also reduced the resorption of bone.

Clinical Limitations

This procedure could not avoid the trauma of multiple extractions and procedural error accompanied with the insertion and adjustment of the prosthesis in the bloodied area. Rather other techniques¹⁶ can be preferred where a try-in of anterior teeth enables esthetic modifications making the final outcome of the denture more predictable.

Conclusion

Immediate overdenture is the better option in partially edentulous patients facing compromised state of dentition. Similar case is described here mentioning clinical and laboratory procedures followed in rehabilitating partially edentulous mouth. Patient was given mandibular immediate denture where few teeth received metal copings serving as overdenture abutments. Such treatment alternatives provide the patient with increased retention and stability of the prosthesis and psychological comfort as well.

Conflict of Interest: None.

References

1. Sharry JJ: Complete Denture Prosthodontics, (ed 3). New York, NY, McGraw-Hill, 1974, p. 295.

2. Seals RR, Kuebker WA, Stewart KI: Immediate complete dentures. *Dent Clin North Am* 1996;40:151-167.
3. Loo W: Ridge preservation with immediate dentures. *J Prosthet Dent* 1968;19:5-11.
4. Kelly EK, Sievers RF: The influence of immediate dentures on tissue healing and alveolar ridge form. *J Prosthet Dent* 1959;9:738-42.
5. Johnson K: A clinical evaluation of immediate denture procedures. *J Prosthet Dent* 1966;16:799-810.
6. Lavere AM, Krol AJ: Immediate denture service. *J Prosthet Dent* 1973;29:10-5.
7. Wyatt CCL: Immediate dentures. In MacEntee MI: The Complete Denture. A Clinical Pathway. Chicago, IL, Quintessence, 1999, p. 99.
8. Waltz ME: Considerate postoperative care for immediate denture patients. *J Prosthet Dent* 1966;16:822-827.
9. Glossary of prosthodontic terms. *J Prosthet Dent* 94(1):10-92.
10. Brewer AA, Morrow RM. Overdentures made easy, 2nd Ed, The C. V. Mosby Co, St. Louis, 1980.
11. Preiskel-Overdentures Made Easy. Chapter 2 Chapter 3, pp. 21-43, pp.45-65.
12. Renner RP, Levy M. Preventive prosthodontics- Overdenture service. *NY State Dent J* 1977;43:17.
13. Pacer FJ, Bowman DC. Occlusal force discrimination by denture patients. *J Prosthet Dent* 1975;33:602-609.
14. Mushimoto E. The role in masseter muscle activities of functionally elicited periodontal afferents from abutment teeth under overdentures. *J Oral Rehabil* 1982;8:441-5.
15. Van Waas MA, Jonkman RE, Kalk W, Van't Hof MA, Plooi J, Van Os JH. Differences two years after tooth extraction in mandibular bone reduction in patients treated with immediate overdentures or with immediate complete dentures. *J Dent Res* 1993;72(6):1001-4.
16. Gilboa I, Cardash HS. An alternative approach to immediate overdenture. *J Prosthodont* 2009;18:71-5.
17. Morrow R, Feldman E, Rudd K, Trovillion H. Tooth supported complete dentures: An approach to preventive prosthodontics. *J Prosthet Dent* 1969;21:512.
18. Crum, R, Rooney G. Alveolar bone loss in overdentures. *J Prosthet Dent* 1978;40:610.
19. Rissin L, House J, Manly R, Kapur K. Clinical comparison of masticatory performance and electromyographic activity of patients with complete dentures, overdentures, and natural teeth. *J Prosthet Dent* 1978;39:508.
20. Morrow R, Powell J, Jameson W, Jewson L, Rudd K. Tooth supported complete dentures: Description and clinical evaluation of a simplified technique. *J Prosthet Dent* 1969;27:414.
21. Reitz P, Weiner M, Levin B. An overdenture survey: Preliminary report. *J Prosthet Dent* 1977;37:246.
22. Fenton A, Hahn N. Tissue response to overdenture therapy. *J Prosthet Dent* 1978;40:492.
23. Renner RP, Foerth D, Pesserillo E. Maintenance of root integrity and periodontal health under overdentures-A pilot study. *Dent* 1978;26:42.
24. Rantantanen T, Makila E, Yli-Uspo A, Siirila H. Investigations of the therapeutic success with dentures retained by precision attachments. *Suom HammaslZik Toim* 67:356.

How to cite this article: Bhojar P, Deogade SC, Immediate Overdenture, *Ann Prosthodont Restor Dent* 2019;5(1):20-22