

Prevention of conventional complete denture problems with tooth supported overdentures

Abhilasha Bhasin^{1,*}, Sneha Mantri², Monika Khatri³

¹Professor, ²Professor and HOD, ³Senior Lecturer, ¹⁻³Dept. of Prosthodontics and Crown and Bridge, ¹⁻³Hitkarini Dental College and Hospital, Jabalpur, Madhya Pradesh, India

***Corresponding Author: Abhilasha Bhasin**

Email: agr_bds@yahoo.com

Abstract

Preventive prosthodontics emphasizes the importance of those procedures that can delay or eliminate future prosthodontic problems. Resorption of the residual alveolar ridge is an unavoidable consequence of tooth loss seen in patients wearing conventional complete dentures after complete loss of teeth. In modern dental practice, multiple treatment modalities are available for the preservation of teeth and prevention of bone loss since both are said to be interrelated. Dentures fabricated over these retained tooth/teeth or roots of teeth are called overdentures, which is a part of “preventive prosthodontic therapy”. The article describes two cases treated by providing tooth supported overdentures.

Keywords: Telescopic denture, Overlay denture, Overdenture, abutment, Cast coping, Preventive dentistry.

Introduction

The architecture of maxilla and mandible is designed to house the roots of teeth and not to act as support for artificial dentures. Extraction of teeth eliminates the need for alveolar process and hence alveolar bone starts resorbing.¹ Alveolar bone loss is said to be progressive and irreversible following extraction of tooth or teeth.² The only reliable method known to prevent this is by maintaining functioning teeth within their sockets.³ This not only prevents bone resorption but also preserves the periodontal ligament of the tooth which is said to have proprioceptive receptors carrying impulses to the brain⁴.

It was in 1950, when health sciences began to apply the concept of “Prevention” in clinical medicine and dentistry.⁵ Preventive prosthodontics gives importance to those procedures that can delay or eliminate the future prosthodontic problems. It refers to the actions taken to prevent the factors which affect the normal oral function, comfort, health, appearance and general health of the patient. Out of the three levels of prevention, which are primary, secondary and tertiary, overdenture treatment options is considered under tertiary level of prevention.⁶

Overdentures are removable partial dentures or complete dentures that cover and rest on one or more remaining natural teeth, the roots of the natural teeth and or dental implants.⁷ They are also called as the overlay dentures, superimposed prosthesis, telescopic denture or hybrid denture. Overdentures are considered superior to conventional complete dentures in terms of retention and stability of a prosthesis, comfort and function such as chewing efficiency with increase control over mandibular movements by the patients.⁸ With overdenture therapy, the occlusal vertical dimension and centric relation are maintained at the same position when natural teeth were present and even facial and lip changes are minimized⁹. It also benefits the patients psychologically as few natural teeth are preserved beneath the denture base.¹⁰ The cases described in the article were provided with tooth supported

overdentures and cast metal, short copings on retained abutment teeth.

Clinical Case 1

A 65 years old male patient reported with completely edentulous mandibular arch and partially edentulous maxillary arch with retained six anterior teeth, which appeared periodontally compromised. Intraoral periapical radiograph revealed loss of alveolar bone support of central and lateral incisors. Canines had adequate bone support. Central and lateral incisors were planned for extraction, and maxillary overdenture was planned with canines as abutments. (Fig. 1) Canines were endodontically treated. Gutta-percha (DENTSPLY, Maillefer) was the material used to seal the canals. The teeth were reduced to a height of 1-2mm above the ridge. A chamfer finish line was prepared all around the teeth. Root canal was prepared to receive a post of around 2mm in the canal using peso reamer and xylene as Gutta-percha dissolvent. After preparation of abutment and post space, pattern for the short coping was prepared using pattern resin by direct method (Fig. 2) Ni-Cr alloy (Bellabond Plus, Bego, Bremen, Germany) was used to cast the copings. (Fig. 3) The copings were cemented using Type 1 glass ionomer cement (G C Corporation, Tokyo, Japan.) (Fig. 4) Once the copings were cemented, complete denture was fabricated by the conventional manner with heat polymerized acrylic resin (Trevalon HI, DENTSPLY India Ltd, Gurugaoan, and Haryana). (Fig. 5) During denture insertion, the maxillary overdenture was checked for pressure spots using pressure indicator paste. The area of the marginal gingiva and the coping was relieved to avoid gingival irritation.

Clinical Case 2

A 61 year old male patient reported to the department with edentulous maxillary arch with retained canines, and all mandibular teeth present (Fig. 6). Dental history revealed that the maxillary teeth were extracted due to periodontal involvement. Flap surgery was done in mandibular arch

with bone grafting and temporary splinting of mandibular teeth. Clinically, both the canines appeared periodontally sound. Intraoral periapical radiograph of maxillary left canine tooth revealed excessive bone loss so the tooth was extracted. Maxillary overdenture was planned for the patient with maxillary right canine as abutment. The abutment tooth was treated endodontically. The tooth was prepared to receive short cast coping with preparation of the canal to receive a post. Pattern of the coping was prepared using pattern resin. Ni-Cr alloy was used to cast the coping. Once the coping was cemented (Fig. 7) maxillary single denture was fabricated by conventional technique.(Fig. 8)

Overdenture maintenance

Patients were instructed for proper home care and hygiene maintenance of the removable prosthesis and placed on a regular recall programme. A correct brushing technique was taught to the patients for cleaning the prosthesis. Oral hygiene instructions for maintenance of abutment and copings were given. They were advised to use soft tooth brush around the coping and asked to leave the dentures out of the mouth, in a denture cleansing solution overnight.

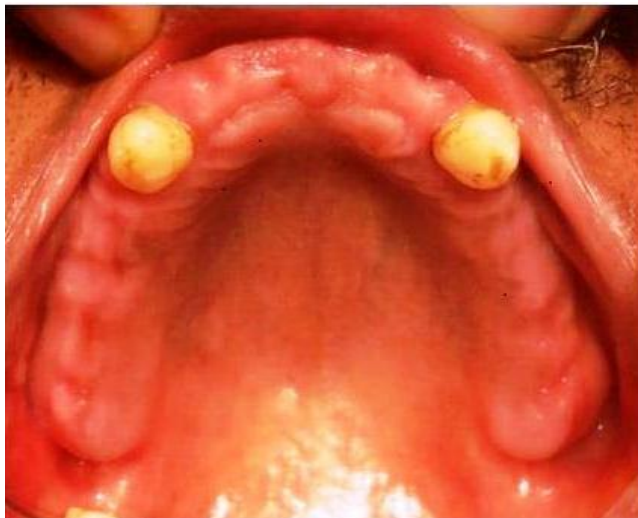

Fig. 1: Intraoral preoperative view

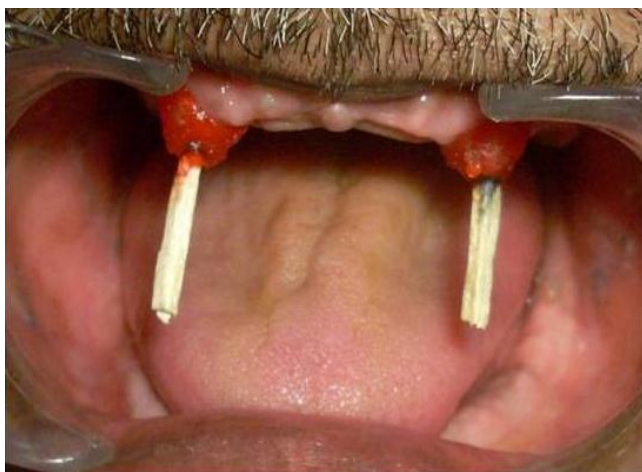


Fig. 2: Pattern fabricated by direct method



Fig. 3: Metal copings ready for cementation

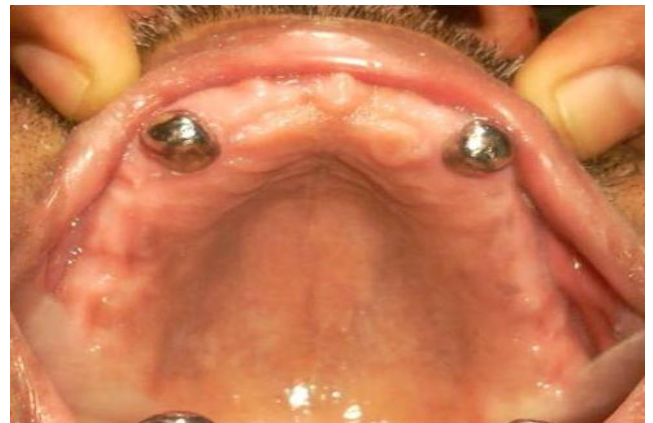

Fig. 4: Copings cemented over prepared canines

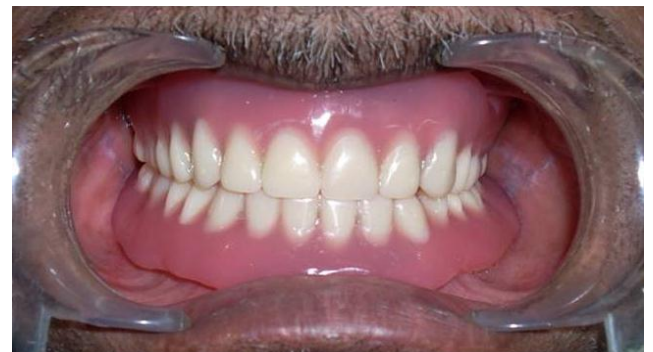

Fig. 5: Denture placed over abutments with copings.

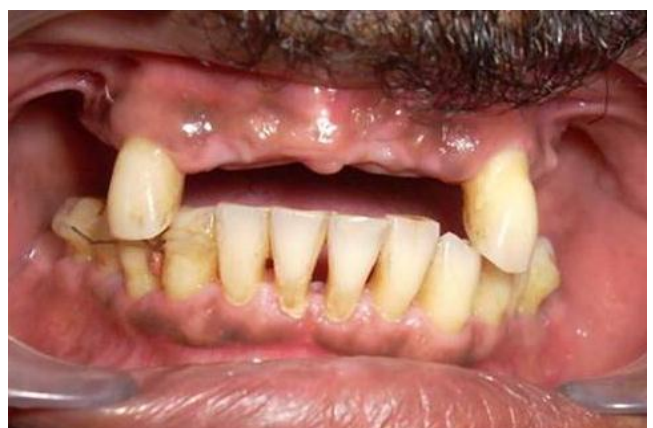

Fig. 6: Intraoral pretreatment view

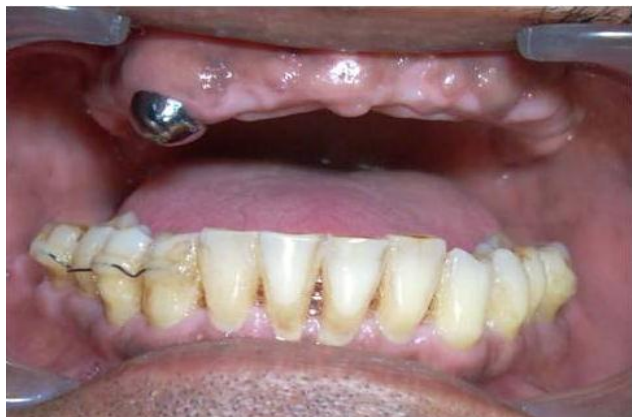

Fig. 7: Copings cemented

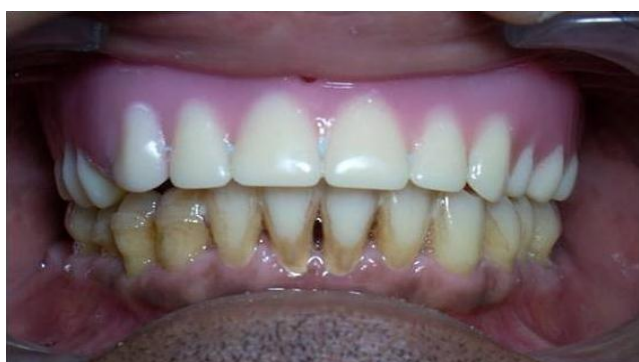

Fig. 8: Single maxillary denture placed opposing natural teeth

Discussion

Overdenture prosthesis constructed over existing teeth or tooth structure is not a new concept. The genesis of submerged root concept probably evolved from a root fractured and left behind during extraction, which were retained in the alveolar bone with no evidence of pathosis.¹¹ In 1861, Barker reported on “Surgical preparation of mouth for artificial dentures”. During Second World War, many dentists in military services used overdentures in the treatment of inadequate or mutilated dentitions. In 1958, Miller reported that retention of few teeth under the complete denture allowed the weak teeth to regain healthy status.¹ This foresight was of prime importance in convincing the profession that overdentures are a superior treatment modality. In 1968, Lord and Teel reported seven years following successful treatment with overdentures.¹²

From the physiologic view point, the teeth or roots of teeth preserved provide periodontal ligament, which attaches the tooth to the bone. It not only supports the teeth, but also provide directional sensitivity, tactile sensitivity to load; dimensional discrimination of food chewed between teeth and canine response.¹³

Various designs of abutment preparations are described in literature, which included short coping overdentures, which are round shaped copings 1 – 2mm above the gingiva, long coping overdentures and attachment coping overdentures¹⁴. Round dome shaped preparation permits the stresses of occlusion to be directed along the long axis of the

abutment teeth and allow some movement of the denture. The dentures were relieved around the copings which ensured that the abutments will not be overloaded at initial placement. The abutment tooth plays no role in retention of the denture but only acts as stabilizer.¹ To improve retention of overdentures, attachments are recommended. Magnetic attachments are also been used for added retention of overdentures.^{15,16} At present, there are several kinds of attachments that may be applied to implant supported overdentures. It includes the use of clip embedded in the denture with implant connecting bar¹⁷ or O-ring embedded in denture with snap-on ball attachment connected to implant.¹⁸

Overdenture is an outstanding treatment modality as compared to conventional dentures. Proper patient selection and motivation, basic prosthodontic principles, maintenance of oral hygiene, appropriate homecare and recall visits can ensure the successful outcome of overdenture therapy.

Conclusion

Unlike other parts of the body, teeth and supporting structures are not regenerative. There is no support for occlusion as adequate as the roots of natural teeth. Therefore, we, being physicians, surgeons, physiologists of the oral cavity should look forward to preserving what is present in the oral cavity. Preservation of few remaining teeth benefits the overdenture patients by improving neuromuscular performance thereby having an edge over his edentulous counterpart.

Conflict of Interest: None.

References

1. Miller P A. Complete denture supported by natural teeth. *J Prosthet Dent* 1958;8(6):924-928.
2. Atwood D A. Reduction of residual ridges: A major oral disease entity. *J Prosthet Dent* 1971;26:266-280.
3. Wical K. Swoope C. Studies of residual ridge resorption Part II. The relationship of dietary calcium and phosphorus to residual ridge resorption. *J Prosthet Dent* 1974;32:13-21.
4. Perel M L. Telescope Dentures. *J Prosthet Dent* 1973;29:151-156.
5. Zavanelli R A. Does a tooth supported overdenture still remain a prosthetic option. *Dentition* 2012;1(1): 38-43.
6. Last J M; A dictionary of epidemiology: Oxford university press. 1983
7. Glossary of Prosthodontic terminologies -8. The Academy of prosthodontics. *J Prosthet Dent* 2005;94(1):56.
8. Hong L, Ettinger RL. Invitro evaluation of fluoride varnish on overdenture abutments. *J Prosthet Dent* 2003;89:28-36.
9. Dodge C A. Prevention of complete denture problems by use of overdentures. *J Prosthet Dent* 1973;30:403-411.
10. Rathod CJ, Mantri SS, Jain P. Prosthodontic rehabilitation with access post overdenture. *Clin dent* 2012; 3:35-38.
11. Hiremath H P et al Endodontic treatment in submerged roots: A case report. *J Dent Res Dent Clin Dent Prospect* 2010;4(2):64-68.
12. Lord JL, Teel S. The Overdentures: Patient selection, use of copings and follow up evaluation. *J Prosthet Dent* 1974;32: 41-51.
13. Kalpana C, Prasad VK. Seeing the unseen: preventive prosthodontics: Use of overlay removable dental prosthesis. *Ann Essences dent* 2010;2(3):44-49.

14. Irving I Z. Overdentures- Theories and Techniques. *J Am Dent Assoc* 1973;86:853-857.
15. Takehiro F. Use of, new magnetic attachments for implant supported overdentures. *J Oral Implantology* 1998;24(3):147-151.
16. Allen P F. Strategic use of new dental magnet system to retain partial and complete overdentures. *Eur J Prosthodont Rest Dent* 2005;13(2):81-86.
17. Engquist B. Advanced osseointegration surgery: applications in the maxillofacial region. In: Worthington P, Branemark P-I, eds. Chicago: *Quintessence*;1992:233–247.
18. Donatsky O. Osseointegrated dental implants with ball attachments supporting overdentures in patients with mandibular alveolar ridge atrophy. *Int J Oral Maxillofac Implants* 1993;8:162–166.

How to cite this article: Bhasin A, Mantri S, Khatri M, Prevention of conventional complete denture problems with tooth supported overdentures, *Ann Prosthodont Restor Dent* 2019;5(1):12-15