

Full mouth rehabilitation: A noble endeavour towards a smile

Pulkit Chandra^{1,*}, Siddharth Mehta², Sadhana Gupta³, Sonika Mann⁴

^{1,2}Senior Lecturer, Dept. of Prosthodontics, ³Deputy Director, ⁴Consultant, ¹Jaipur Dental College, Jaipur, Rajasthan, ²Bapuji Dental College and Hospital, Davangere, Karnataka, ³Zanana Hospital, Jaipur, Rajasthan, ⁴Phoenix Polyclinic and Dental Care

***Corresponding Author:**

Email: Chandra.pulkit@gmail.com

Abstract

Rehabilitation of a mutilated dentition is one of the most challenging task for a prosthodontist. Reorganization of occlusion may be required in treating severely worn out dentitions, developmental anomalies, acquired defects, ill fitting, long span fixed partial dentures and TMJ disorders. Vertical dimension of occlusion, centric relation, occlusal contact pattern, aesthetics and phonetics all have a major role and need to be delicately and precisely balanced simultaneously for both anterior and posterior teeth during occlusal rehabilitations. Different schools of thoughts have been documented for rehabilitation of such cases and the choice of the treatment plan depends on the skill and experience of the clinician. This clinical report describes the full mouth rehabilitation of a severely worn out dentition, in functional harmony with the stomatognathic system.

Keywords: Full mouth rehabilitation, Attrition, Cross Bite, Smile Designing, Occlusion.

Introduction

The inevitable and necessary daily use of our teeth leads to the slow but regular deterioration of the occlusal surfaces of our teeth, however, exaggerated wear and tear can result in pulpal pathologies, disturbances in occlusion, functional impairment and esthetic disfigurement.¹ Tooth wear can be of varied type such as attrition, abrasion, and erosion depending on the causative factors. In the bulk of such cases, there exists a composite and complex effect of all these processes.² Therefore, it is critical to diagnose and analyse the causative factors that led to the excessive wear and gauge the loss in the Vertical Dimension of occlusion (VDO).³

In some cases as the teeth wear down, the alveolar bone undergoes an adaptive process and compensates for the loss of tooth structure to maintain the VDO. Tooth eruption and Alveolar bone growth together maintain the vertical dimension of occlusion and prevent the facial disfigurement due to loss in Vertical Dimension (VDO). Therefore, VDO evaluations and adjustments should be very precise and changed using proper analysis and techniques.⁴ Improper planning and raising the vertical dimension in bruxers can put excessive loads on the teeth and restorations which might lead to TMJ problems, destruction of the teeth or the restorations themselves.⁴

Rehabilitation of a mutilated dentition with fixed or removable therapy requires a highly sensitive and skilled set of hands and minds. A critical analysis of the prevailing condition and the patient's expectations followed by an ethical and comprehensive treatment plan is a must in every case. It is imperative to collect important information from Diagnostic mountings and wax-ups for the better planning and execution of the treatment. Removable Splints or Provisionals/Temporaries are the most suited aid to verify the acceptance of a change in the vertical dimension of occlusion in a patient.⁵

In this particular case report we take look at a full

mouth rehabilitation along with the practical limitations wherein, the vertical dimension of occlusion was raised and verified by monitoring his adaptation to a removable overlay splint and provisional crowns over a two month period, following which the final cementations were done.^{6,7}

Case Report

A 72-year-old man who visited for the treatment of his severely worn dentition complained of his inability to eat and specifically bite anything, also the patient expressed his grief about not being able to smile and converse confidently with people due to the excessive wear of his front teeth.

A detailed dental, medical and social history was obtained. The patient's general medical history was insignificant, he had no sign/symptoms of TMDs or pain in the masticatory muscles.

Extra-oral examination - showed a reduction of the lower facial height and protuberant lips, wrinkles, drooping and over-closure of the commissures caused by the loss of vertical dimension.

Intraoral examination - The general standard of oral hygiene and gingival situation were unsatisfactory and revealed a generalized loss of dental hard tissues that was greater in the maxillary anteriors with maxillary right lateral incisor and canine worn to the gingival level.

The anterior teeth had sharp enamel edges, dentinal craters, and attritional wear due to the loss of posterior support. A severe loss of vertical dimension was observed and upper incisors were severely eroded and in contact with the lower incisal edges in a partial class III/I situation with 43 situated in crossbite. A bridge was present involving 25 and 27, with 26 as pontic, the patient also had an implant retained crown wrt 46 which was in infra-occlusion wrt to the current occlusion, the patient however did not want them to be changed (limitations of clinical practice).

Numerous factors in this case gave an indication about the loss in vertical dimension^{1,8,9}:

- a. Patient's inability to pronounce letters such as "S" because of the increased distance between the palatal surfaces of the maxillary anterior teeth and the incisal edges of the mandibular anterior teeth (ideally it should be around 1mm).
- b. Generalized old appearance of the face due to wrinkling and drooping commissures of the mouth.
- c. Excessive wear involving the occlusal surfaces of the teeth which in all probability outpaced the compensatory tooth eruption to maintain the loss in vertical dimension. This along with loss of posterior teeth support in the fourth quadrant where in the teeth (46 onwards) were in infra occlusion, led to an increased inter-occlusal space which was 5-6 mm greater than the normal range of 2-4 mm.

Posterior teeth interferences in centric and eccentric contacts, parafunction, diet and ill advised eating habits and most importantly disregard towards one's dental health could be the probable causes of such a mutilated state of dentition.

The treatment options were described to the patient. He did not accept the replacement of the crown wrt 46 and the bridge wrt 25, 26, 27. Also the patient did not want to get multiple crown lengthening procedures, which come under the limitations of clinical practice however the patient did agree for endodontic and prosthetic treatments from 16 to 24 in the maxillary arch and 37 to 45 in the mandibular arch. (so as to get the patient to a minimum acceptable functional and esthetic state within the limitations).

The patient's casts were mounted on a semi-adjustable articulator using a face-bow record and an inter-occlusal record that was made with the aid of a Lucia jig and PVS occlusal registration material.

To minimize the treatment time and patient discomfort the endodontic work was completed for all the teeth after oral prophylaxis and then the required post and core were done for 11,12.

The new VDO was raised by 2 mm initially and later by another 3 mm (5mm in total) in the incisal guidance pin of the articulator. The removable overlay splint ensured bilateral simultaneous contacts of the posterior teeth in centric relation and the excursive movement guides were also incorporated for the anterior teeth, to ensure the Christenson's Phenomenon.

With no signs of muscle tenderness and temporomandibular discomfort over a 1 months period patient's acceptance to the raised VDO was verified. Once the desirable VDO for the fixed interim prostheses was established using the removable overlay splint, CR records using Lucia jig and wax were made and diagnostic wax-up was performed for fabricating the provisional crowns.

Bis-acrylic resin provisional crowns were fabricated using a vacuum formed matrix that was fabricated with

the help of the diagnostic wax-up. Initial crown preparations were done, 11 and 12 were built up with a post and core each, following which the provisional fixed restorations were cemented with temporary cement and the patient's adaptation was monitored.

For a month, interim restorations were adjusted for esthetics and centric and excursive interferences following which they were used as a guide for the definitive oral rehabilitation. During this period, the patient's condition and functions, such as muscle tenderness, discomfort of TMJ, mastication, range of the mandibular movements, swallowing and speech, were evaluated. Improvement in mastication, speech and facial esthetics confirmed the patient's tolerance to the new mandibular position with the restored VDO.

Final preparations were refined and definitive impressions were made with PVS impression material. Bite registration was taken using provisional crown and wax by half and half method. Porcelain fused to metal restorations were cemented with GIC and zirconia crowns were cemented after treatment with silane coupling agents using resin cement. The prostheses were designed using mutually protected occlusion. The anterior teeth protected the posterior teeth from excursive force and wear, and posterior teeth supported the bite force. Oral hygiene instructions and regular check-up were administered.

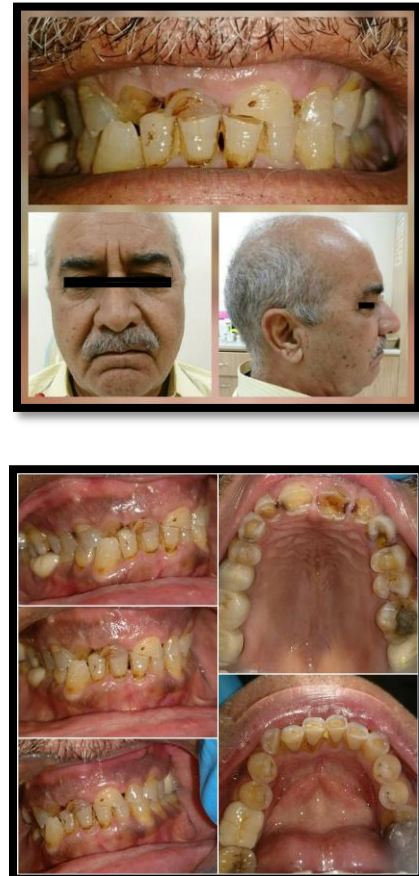


Fig. 1: Pre-op Images

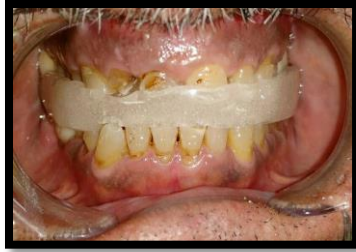

Fig. 2: Removable Bite Raising Splint

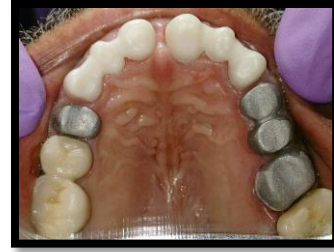

Fig. 7: Coping Try-in: Maxillary Arch

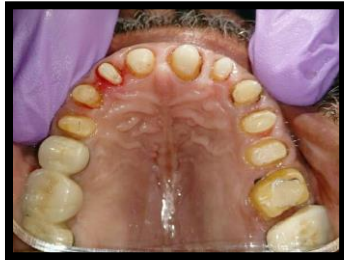

Fig. 3: Crown Preparations: Maxillary Arch

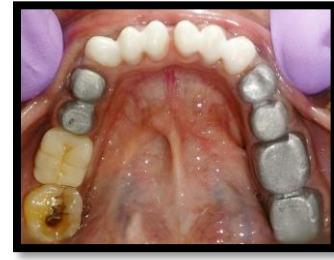

Fig. 8: Coping Try-in: Mandibular Arch

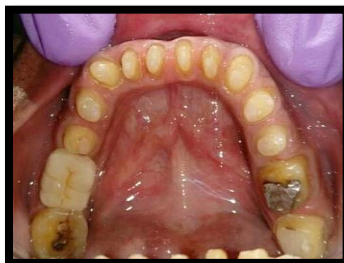

Fig. 4: Crown Preparations: Mandibular Arch

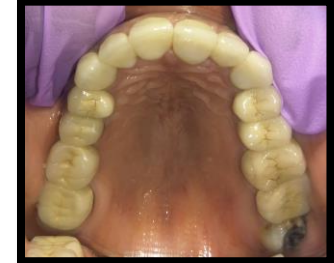

Fig. 9: Final Crowns: Maxillary Arch

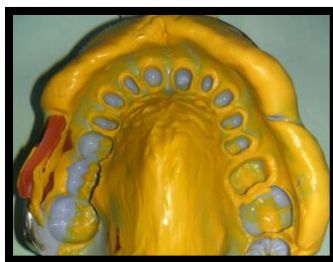
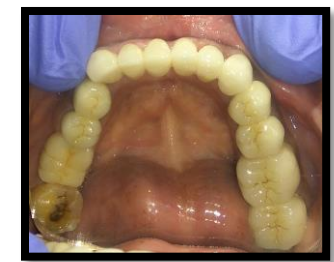
Fig. 5: Final Impressions: Maxillary Arch



Final 10: Final Crowns: Maxillary Arch

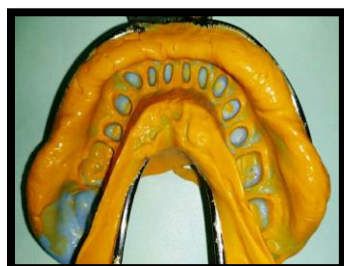

Fig. 6: Final Impressions: Mandibular Arch

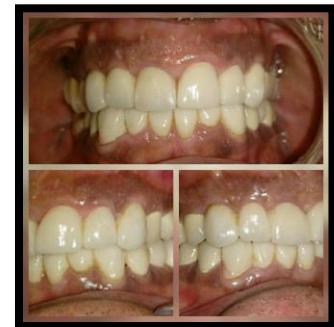

Fig. 11: Final crowns: Frontal, Left lateral and Right lateral views

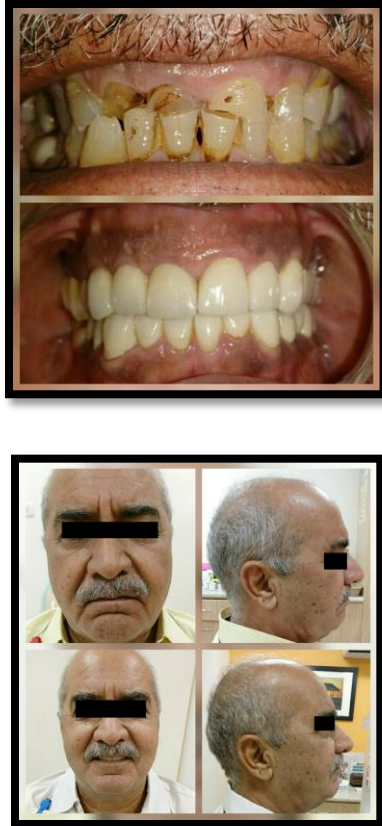

Fig. 12 & 13: Notice the change: When you make someone smile again!!!!

Discussion

Full mouth rehabilitation aims at preservation of health, restoring function and achieving aesthetics and patient comfort, it requires a systematic and integrated approach for a favourable and predictable prognosis.⁴

Since 1984 till date it is the Turner and Missirlan¹ classification, which classifies the cases of worn down dentitions based on the amount of loss of VDO and the space available to restore the dentition. However, due to the scarcity in the number of good cases and literature on long term outcomes of treatment methods, materials it causes great ambiguity and difficulty in clinical decision-making.¹⁰

One of the most common and complicated malocclusion to treat is "Deep bite".^{11,12} Patients with loss of VDO have some common clinical characteristics. The most common is a deep mento-labial sulcus,¹³ aging effect of poor profile on the patient, pressure of lower incisors on palatal aspects of the upper incisors and as a result an improper anterior guidance.¹⁴

Rehabilitation could be by combining surgical therapy with orthodontic treatment,^{14,15} and restorative procedures or orthodontic therapy followed by restorative procedure.¹⁴

Deep bite is the most difficult case to correct

orthodontically, since it often relapses following orthodontic treatment.¹⁶

Due to the time constraints and difficulties associated with surgical/orthodontic treatment patient was not inclined for them. Therefore, correction of dentofacial deformities had to be treated with restorative procedures only that included a trial overlay splint, provisional restoration, careful monitoring, and definitive prosthesis.

As earlier studies have indicated increasing the VDO, affects the facial esthetics and the peri-oral areas along with the whole face.¹⁷ However, it has also been indicated that changing VDO within a range of 2 to 6 mm may not be visually noticeable by some authors.¹⁸ However in this particular case, VDO increased with full-mouth restorations had a noticeable facial change on the patient's face and esthetics.

Even though a wide variety of VDO-evaluating methods have been described in the literature^{19,20} but there is no single specific scientific method to accurately determine the correct VDO for a patient^{21,22}, therefore a combination of some methods is best suited for clinical determination.²² In the present report, among the techniques, facial soft tissue contours and assessment of the VDR were used to evaluate the VDO clinically. In addition, the golden rule, profile, contour of the lips, and old photographs were accepted as criteria for evaluating OVD.

There is an abundance of literature and case reports advocating "Ideal timelines" for provisional crowns/removable splints for determining the acceptance of the raised VDO,^{6,7} however in this case the timelines have been modified to an ethical extent as a part of the limitations in clinical practice also before finalizing the new VDO it was ensured that there were no discomfort, wear/breakage of provisionals or muscle tenderness/fatigue. The new VDO was established based on both esthetic and functional harmony.

Studies have also stated problems such as joint or muscle pain, instability of altered OVD, impaired muscle activity, and altered phonetics due to increasing OVD incorrectly.²¹ The upper limit of raising the vertical dimension is impossible to determine but in general an increase of 5mm is sufficient and more than this is very rarely required and indicated.²³ Moreover, minimizing the increase in OVD is beneficial to avoid complexity of the prosthodontic treatment.²⁴ In the present report, OVD was increased 5 mm in the anterior region and 3 to 4 mm in the posterior region. In addition, the patient adapted well and was satisfied with the results.

Keeping in mind the greater stresses expected in anterior and posterior areas due to raised VDO and tension in the facial and masticatory muscles as expected in a deep bite case, PFM restorations were chosen for the posterior teeth and Zirconia restorations for the anterior teeth, to avoid the disadvantages associated with the pfm crown esthetics in the anterior

teeth (esp. the greyish discolouration along the margins).

Conclusion

Along with the esthetic and functional expectations of the patient in a full mouth rehabilitation case, the overall health of the stomatognathic system has to be given the utmost importance. Especially in clinical practice some limitations such as patient age, attitude and cooperation to different dental treatments along with economics are other important factors that influence the overall treatment plan and its execution.

Funding: No funding sources.

Conflict of interest: None declared.

References

1. Turner KA, Missirlian DM. Restoration of the extremely worn dentition. *J Prosthet Dent* 1984;52:467-74.
2. Smith BG. Toothwear: aetiology and diagnosis. *Dent Update* 1989;16:204-12.
3. Prasad S, Kuracina J, Monaco EA Jr. Altering occlusal vertical dimension provisionally with base metal onlays: a clinical report. *J Prosthet Dent* 2008;100:338-42.
4. Dawson PE. Functional Occlusion - From TMJ to smile design. 1st ed. New York: Elsevier Inc.; 2008. p. 430-52.
5. Hemmings KW, Howlett JA, Woodley NJ, Griffiths BM. Partial dentures for patients with advanced tooth wear. *Dent Update* 1995;22:52-9.
6. Yunus N, Abdullah H, Hanapiah F. The use of implants in the occlusal rehabilitation of a partially edentulous patient: a clinical report. *J Prosthet Dent* 2001;85:540-43.
7. Ganddini MR, Al-Mardini M, Graser GN, Almog D. Maxillary and mandibular overlay removable partial dentures for the restoration of worn teeth. *J Prosthet Dent* 2004;91:210-14.
8. Jahangiri L, Jang S. Onlay partial denture technique for assessment of adequate occlusal vertical dimension: a clinical report. *J Prosthet Dent* 2002;87:1-4.
9. Sato S, Hotta TH, Pedrazzi V. Removable occlusal overlay splint in the management of tooth wear: a clinical report. *J Prosthet Dent* 2000;83:392-95.
10. Johansson A, Johansson AK, Omar R, Carlsson GE. Rehabilitation of the worn dentition. *J Oral Rehabil* 2008;35:548-66.
11. Park HS, Kim JY, Kwon TG. Treatment of a Class II deepbite with microimplant anchorage. *Am J Orthod Dentofacial Orthop* 2011;139:397-406.
12. Parker CD, Nanda RS, Currier GF. Skeletal and dental changes associated with the treatment of deep bite malocclusion. *Am J Orthod Dentofacial Orthop* 1995;107:382-93.
13. Karlson AT. Craniofacial characteristics in children with Angle Class II div. 2 malocclusion combined with extreme deep bite. *Angle Orthod* 1994;64:123-30.
14. Lee RL, Gregory GG. Gaining vertical dimension for the deep bite restorative patient. *Dent Clin North Am* 1971;15:743-63.
15. Bell WH, Jacobs JD, Legan HL. Treatment of Class II deep bite by orthodontic and surgical means. *Am J Orthod* 1984;85:1-20.
16. Bergersen EO. A longitudinal study of anterior vertical overbite from eight to twenty years of age. *Angle Orthod* 1988;58:237-56.
17. Mohindra NK, Bulman JS. The effect of increasing vertical dimension of occlusion on facial aesthetics. *Br Dent J* 2002;192:164-68.
18. Gross MD, Nissan J, Ormianer Z, et al: The effect of increasing occlusal vertical dimension on face height. *Int J Prosthodont* 2002;15:353-57.
19. Rivera-Morales WC, Goldman BM. Are speech-based techniques for determination of occlusal vertical dimension reliable? *Compend Contin Educ Dent* 1997;18:1214-1215, 1219-23.
20. Al-Dhaher HA, AL-Huwaizi AF: Determination of the vertical dimension by cranio-facial measurement using clinical and cephalometric analysis (comparative study). *J Bagh Coll Dent* 2009;21:44-7.
21. Bachhav VC, Aras MA: Altering occlusal vertical dimension in functional and esthetic rehabilitation of severely worn dentition. *J Oral Health Res* 2010;1:2-8.
22. Millet C, Leterme A, Jeannin C, et al: Vertical dimension in the treatment of the edentulous patient. *Rev Stomatol Chir Maxillofac* 2010;111:315-30.
23. Abduo J: Safety of increasing vertical dimension of occlusion: a systematic review. *Quint Int* 2012;43:369-80.
24. Abduo J, Lyons K: Clinical considerations for increasing occlusal vertical dimension: a review. *Aust Dent J* 2012;57:2-10.

How to cite the article: Chandra P., Mehta S., Gupta S., Mann S. Full mouth rehabilitation: A noble endeavour towards a smile. *Ann Prosthodont Restor Dent* 2018;4(3):90-94.