

Prosthesis for mandibular guidance therapy – A case series

Ishan Roy Choudhury^{1,*}, Kritika Rajan², Jayanta Bhattacharyya³, Amit Ray⁴

¹Senior Lecturer, ²Post Graduate Trainee, ³Professor & HOD, Principal, ⁴Professor & HOD, ¹⁻³Dept. of Prosthodontics and Crown & bridge, ⁴Dept. of Oral and Maxillofacial Surgery, Guru Nanak Institute of Dental Sciences and Research, Kolkata, West Bengal, India

***Corresponding Author:**

Email: ishanr3@gmail.com

Abstract

This article shows the importance of an intra-oral guiding flange prosthesis in patients who have undergone resection of mandible due to an underlying pathology. The case series show how the use of a guidance prosthesis can re-educate the mandibular muscles and re-establish an occlusal relationship for the resected mandible. Fabrication of a Guiding flange prosthesis was done for patient's reporting to the department of Prosthodontics, with a significant deviation of mandible causing a deranged occlusion. Utilisation of various intra-oral prosthesis designs to overcome the deranged forces of the mandibular muscles have been shown. Basic designs used for fabricating the guidance prosthesis were buccal-based (maxillary based), palatal-based (maxillary based) and mandibular-based guidance. The re-establishment of the occlusal relationship was successful with the use, of any of the basic designs, of a guiding prosthesis. The patients could maintain a healthy occlusal relationship even after cessation of the therapy. This case series gives an insight as to how a Guidance prosthesis can be utilized either on an interim basis or as a part of definitive treatment too, although the success depends on the nature of surgical defect, patient's cooperation and early physiotherapy program.

Keywords: Guiding flange, Mandibular defect, Occlusal correction.

Introduction

Mandibular discontinuity defects due to surgical treatment of neoplastic lesions of the tongue, mandible, floor of the mouth and oral vestibule present a major challenge to the maxillofacial prosthodontist.¹ It destroys balance and symmetry which leads to the residual mandible deviating medially and superiorly producing altered mandibular movements.² The degree of deviation depends on the location, extension of the resection and the amount of soft tissue involvement.³ This deviation is more evident in edentulous situations than in dentulous patients who can give good inter-cuspatation.⁴

This shift is attributed to the uncompensated influence of the contra-lateral musculature, particularly the internal pterygoid muscle and the pull of the cicatricial tissue on the resected side. This, if left uncompensated, may produce functional loss and facial asymmetry.⁵

Two features dictate the uncoordinated action of the residual mandibular segment, Firstly, the remaining unilateral muscular activity is specific to the surgical resection and has a characteristic resting posture to the defect side with a diagonal movement on closure; Secondly, as healing progresses the surgical environment changes, and the patient's efforts to train movement during this healing period will help to maintain both position and movement range.³

A corrective device known as 'guide flange prosthesis' is indicated to limit this clinical manifestation and enable the movement during the healing period.¹ A guide flange prosthesis is used primarily as an interim training device.³ In the past many modalities have been used which includes inter-maxillary fixations, vacuum

formed PVC splints, guide flange prosthesis and a widened maxillary occlusal table with twin occlusion.⁵ Inter-maxillary fixation maintains the residual bone in the proper maxillo-mandibular position at the time of surgery but only works well when the discontinuity defects are small because the soft tissue is available to close the defects. In patients with large discontinuity defects, the use is limited.⁶

The main objective of using guidance prosthesis is to re-educate the mandibular muscles and to re-establish an occlusal relationship for the resected mandible.⁵ The earlier that mandibular guidance therapy is initiated during the treatment, the more successful is the patient's definitive occlusal relationship. There are varying basic designs to fabricating guidance prosthesis. These may be either buccal-based, palatal-based or mandibular-based guidance.⁴

Case Reports / Methods

The designs can be clearly explained through the following clinical reports of patients who reported for rehabilitation to the Department of Prosthodontics and Crown & Bridge, Guru Nanak Institute of Dental Sciences and Research, Kolkata; after undergoing surgical resection of a part of the mandible in the Department of Oral and Maxillofacial surgery in the same institution.

First, is a case of a 19 year old male reporting with a deviation of mandible following mandibular surgery on the left side two years ago following a diagnosis of ossifying fibroma. A palatal-based guiding flange prosthesis was fabricated on the non-defect (right) side. The retention was provided by the interdental clasps,

engaging the maxillary first premolars and molars. A palatal acrylic flange of sufficient length was attached on the unaffected side to serve as a guiding plane. (Fig. 1-3)

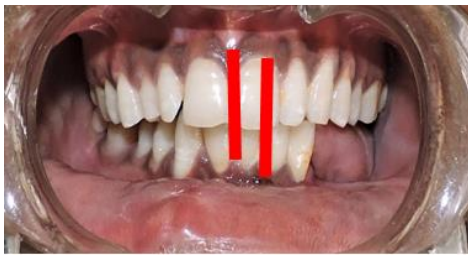


Fig. 1: Intra-oral view showing deviation of mandible

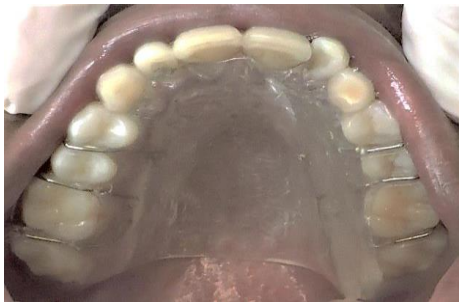

Fig. 2: Intra-oral view of prosthesis

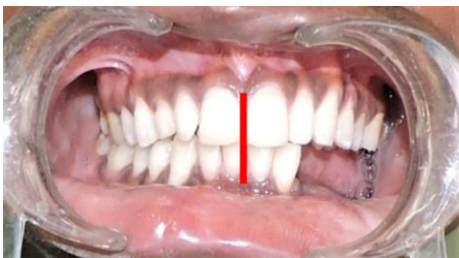


Fig. 3: Intra-oral view of teeth in occlusion after guidance therapy

Similarly, a second case of a 30 year old female reporting with a chief complaint of difficulty in opening the mouth for the past 3 months due to surgically stripping off of the masseter and medial pterygoid muscles and the removal of a wedge shaped bone from the posterior border of Ramus of mandible in order to treat a Sub-massetric space abscess. A palatal-based guidance prosthesis was fabricated as described previously.

Thirdly, a case of a 42 year old male reporting with asymmetry of the face on the right side due to surgery for ameloblastoma one year ago. A mandibular-based guidance prosthesis was fabricated on the non-defect (left) side. The design included the guidance flange from a mandibular removable partial denture prosthesis. The retention was provided by a cue-sil prosthesis since a considerable period of time had elapsed after the surgical procedure and scar tissue formation has occurred. (Fig. 4-6)

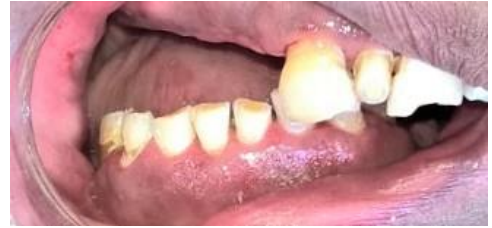

Fig. 4: Frontal view of patient

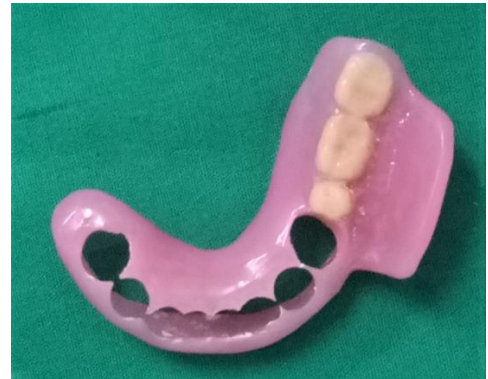

Fig. 5: Finished and polished cue-sil prosthesis

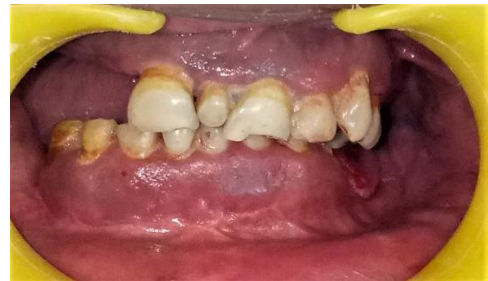

Fig. 6: Definitive intra-oral result

Next, is a case of a 36 year old male reporting with unilateral discontinuity mandibular defect due to an extensive resection of the mandible on the left side three years ago for follicular ameloblastoma. Defect was rehabilitated with a free-fibular bone graft. A buccal-based guidance flange prosthesis was planned on the non-resected side and retention was derived from C-clasps and Adam's clasps in the premolars and molars respectively. A ramp-like extension was made on the buccal aspect on the right side with heat-cure poly-methylmethacrylate. (Fig. 7, 8)

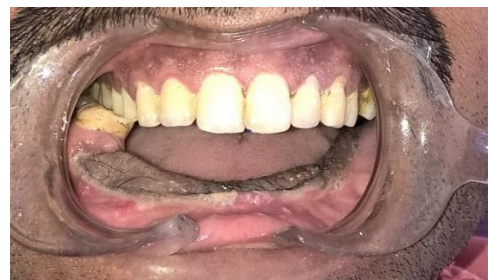

Fig. 7: Intra-oral view showing deviation of mandible towards the non-resected side

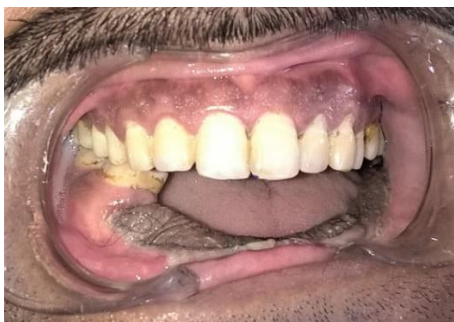

Fig. 8: Intra-oral view of correction of deviation after appliance therapy

For all the above cases, the guide flange was fabricated in such a way so that the cheek and tongue was effectively out of the path of closure.⁷ Mandibular exercises were suggested to aid in faster correction of mandibular deviation. Post treatment with a guide flange prosthesis, the patient was able to achieve the medio-lateral position of the mandible which corrected the deviation and facial asymmetry and was able to repeat this position for adequate mastication. Patients were instructed to maintain proper oral hygiene and care for their prosthesis.

For most of the patients the occlusion was stable after a period of wear of 8 – 10 weeks, with the prosthesis in place. Following this, the decrease of deviation and maintenance of occlusal equilibrium was consistent even when they were without the prosthesis in place. This showed, that a patient with a significant deviation of the mandible or with a deranged occlusion can be successfully treated to overcome the opposing muscular forces.

Discussion

Guidance prostheses are utilized on an interim basis but could be used as a part of definitive treatment too although the success depends on the nature of surgical defect, patient's cooperation and early physiotherapy program. For best results the prosthesis should be used along with an organized exercise program. The exercise program can be started 2 weeks post - surgically and consists of the patient grasping the chin and moving the mandible away from the surgical side. There is no specific direction as to duration of the program or other physiotherapy that could be performed.⁹

In edentulous patients it is easier to achieve a more normal mandibular movement, to facilitate mastication, and to improve facial appearance as compared to an edentulous patient. It is more difficult to retrain mandibular movement in edentulous patients, and many may never achieve proper maxillomandibular relationships for optimum mastication and appearance.⁹ Palatal guidance ramps or mandibular guide flange prostheses have been used with equal success for most types of cases.⁵ It becomes difficult to rehabilitate a

patient who has undergone radiation therapy, the tissues are friable, and the patient experiences xerostomia.⁹

For smaller defects, the best option is to restore the continuity of the mandible by going in for a secondary reconstructive surgery.⁶ But in cases of larger defects, a guide flange prosthesis fabrication becomes an adjunct to achieving this goal. Apart from the benefits of this appliance, it is cheap and utilises materials which are readily available. Patient acceptance has also been favourable.⁸

Conclusion

After a mandibulectomy procedure has been carried out, in most of the cases a deviation occurs. This leads to a deranged occlusion. Giving an intra-oral prosthesis to such a patient leads to an improper prosthetic rehabilitation. Such patients should be treated with a guiding prosthesis, which can be given as an interim prosthesis or a definitive prosthesis. This helps make the patients oral musculature and occlusion more conducive for rehabilitation procedures.

Funding: No funding sources.

Conflict of interest: None declared.

References

1. Aggarwal H, Jurel SK, Kumar P, Chand P. Rehabilitating Mandibular Resection with Guide Flange Prosthesis. *J Coll Physicians Surg Pak* 2014;24(2):135-37.
2. Pathak S, Deol S, Jayna A. Occlusal guiding flange prosthesis for management of hemimandibulectomy- a case report. *J Dent Specialities* 2015;3(2):192-94.
3. Srivastava R, Shrivastava R, Pathak V. Guiding Flange Prosthesis for a patient with mandibular deviation following Hemimandibulectomy defect: A Case Report. *JPFA* 2012;26:173-76.
4. Prencipe MA, Durval E, De Salvador A, Tatini C, Branchi Roberto. Removable Partial Prosthesis (RPP) with acrylic resin flange for the mandibular guidance therapy. *J Maxillofac Oral Surg* 2009;8(1):19–21.
5. Pradhan AV, Dange SP, Vaidy S. Mandibular repositioning in a hemimandibulectomy patient using guide flange prosthesis: A Case Report. *JAMDSR* 2014;2(2):161-65.
6. Desjardins RP. Occlusal considerations for the partial mandibulectomy patient. *J Prosthet Dent* 1979;41 (3):308-15.
7. Sahin N, Hekimoglu C, Yuvuz A. The fabrication of cast metal guidance flange prosthesis for a patient with a segmental mandibulectomy. *J Prosthet Dent* 2005;93:217-20.
8. Monaghan AM, Bear AS. A simple appliance to correct mandibular deviation following hemimandibulectomy. *Br J Oral Maxillofac Surg* 1999;26:418-20.
9. Schneider RL, Taylor TD. Mandibular resection guidance prosthesis: A literature review. *J Prosthet Dent* 1986;55(1):84-6.

How to cite the article: Choudhury I., Rajan K., Bhattacharyya J., Ray A. Prosthesis for mandibular guidance therapy – A case series. *Ann Prosthodont Restor Dent* 2018;4(3):79-81.