

Analysis of severity of ridge resorption in West Uttar Pradesh population

Rimsha Ahmed^{1,*}, Vibhuti Kaul², Rudra Kaul³, Subha Soumya Dany⁴, Shafait Ullah Khateeb⁵

¹Senior Lecturer, ²Registrar, ³Lecturer, ⁴Senior Resident, ⁵Assistant Professor, ¹Dept. of Prosthodontics and Crown & Bridge, Minority Dental College and Hospital, Darbanga, Bihar, ²Dept. of Oral Medicine and Radiology, Indira Gandhi Government Dental College and Hospital, Jammu, ³Dept. of Conservative Dentistry and Endodontics, Indira Gandhi Government Dental College and Hospital, Jammu, ⁴Dept. of Dentistry, VSS Institute of Medical Sciences and Research, Burla, Odisha, ⁵Dept. of Restorative Dentistry, King Khalid University College of Dentistry, Saudi Arabia

***Corresponding Author:**

Email: rimzahmed1989@gmail.com

Abstract

Edentulism is a debilitating disease and an irreversible condition historically considered as one of the most important global oral health burden. Once the teeth are lost, ridge resorption is inevitable. An increase in rate of resorption might lead to decrease in denture stability and hence problems in accepting future prosthesis. The aim of this study was to assess the severity of resorption in edentulous subjects in west Uttar Pradesh.

Keywords: Edentulism, Resorption, Bone loss, Stability.

Introduction

Several anatomic changes invariably take place within the alveolar processes of the jaws following dental extractions. Residual ridge resorption is a cumulative and irreversible process and differs from one individual to the other and also varies at different times and different sites. The edentulous ridges are characterized by high resorption rate following teeth extraction in the early period, followed by a remarkably slowing rate within the first year.⁽¹⁾ Also, once the teeth are extracted, the nature of forces being exerted on the alveolar ridge changes. The load is not directed towards the entire bone, but applied only to its surface and these compressive forces may lead to faster resorption followed by atrophy. This may result in insufficient bone to accept future prosthesis.

Several classifications of ridge resorption have been reported in the literature in order to describe the anatomical variations at different anatomic levels and estimation of the bone height and width and amount of basal bone to be used by the clinician for establishing a relational plan of treatment. Atwood emphasized the importance of considering the reduction of residual ridges as a major oral disease which should be studied with the use of epidemiologic methods and principles. Terms like low, flat or poor were used to describe the amount of resorption but no precise description was given.⁽¹⁾ Also, it is limited to anterior area only. Whereas, Wical and Swoope⁽²⁾ investigated the possibility of using the inferior border of the mental foramen as a reference point to estimate the original retrospective bone height of the edentulous mandible. They concluded that, in spite of increasing age or resorption of the residual ridge, the relationship of the mental foramen and lower border of the mandible remains relatively constant. According to them, the original height of mandible can be estimated by measuring the distance from the inferior border to the

lower edge of the mandible and using the approximate ratio of 3:1. The aim of this study was to assess the severity of resorption in edentulous subjects in west Uttar Pradesh using Wical and Swoop classification as the yardstick.

Materials and Method

2.1.1 Patients

This study was conducted on 300 completely edentulous patients excluding those suffering from disorders like diabetes and osteoporosis. These patients were divided into three groups according to Wical and Swoop's classification based upon the severity of alveolar ridge resorption (Wical and Swoop 1974).

- Group 1: Up to one third of the original vertical height lost
- Group 2: From one third to two thirds of the vertical height lost
- Group 3: Two thirds or more of the mandibular height lost

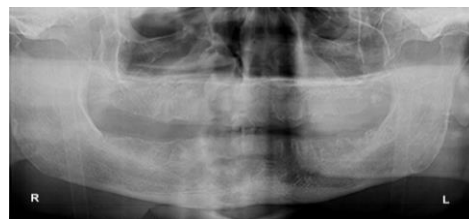


Fig. 1: Grade I Resorbed mandibular ridge

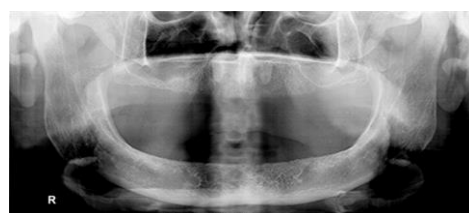

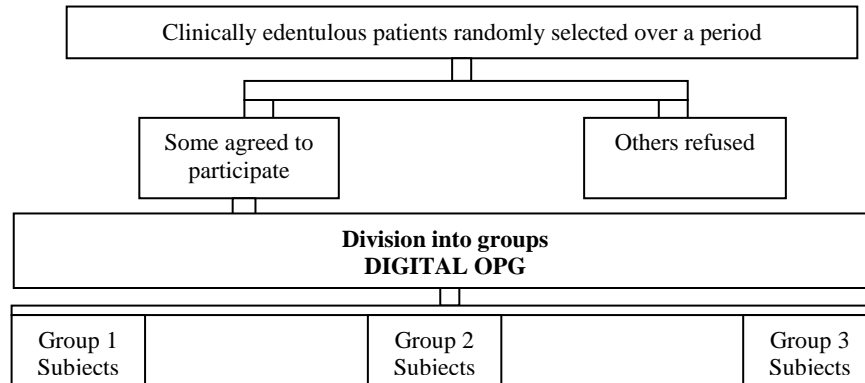
Fig. 2: Grade II Resorbed mandibular ridge

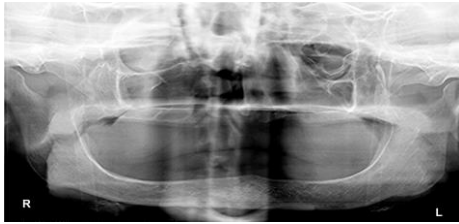

Fig. 3: Grade III Resorbed mandibular ridge

Methodology

Over a time period of 6 months, clinically edentulous patients were randomly selected and requested to contribute to the study as participants. Of all the subjects, some agreed to participate whereas others refused due to different reasons. A written consent was obtained from the selected patients.



For the purpose of division into groups, digital O.P.G was carried out for each patient and based on the degree of resorption, three groups were made. The distance between the lower border of mental foramen and lower and upper border of mandible was measured and recorded. Group 1 consisted of patients with up to one third of the original vertical height of the mandible lost whereas in Group 2 subjects, one third to two thirds of the vertical height was lost. GROUP 3 had two thirds or more of the mandibular height lost.

Results

According to the results of this study, in 30.4% of the patients upto one third of the original vertical height was lost (group 1), whereas in about 55.3% of patients one third to two thirds of the vertical height was reduced (group 2). Two thirds or more of the mandibular height was lost in 14.3% patients.

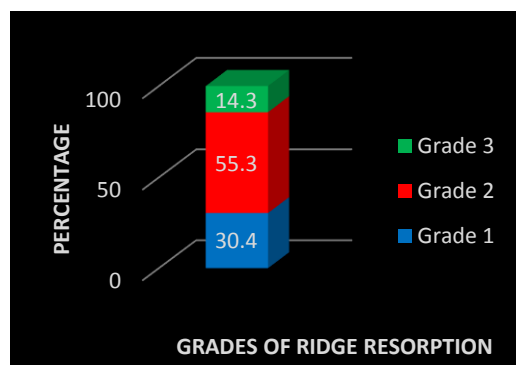


Fig. 1: Distribution of study subjects according to grade of ridge resorption

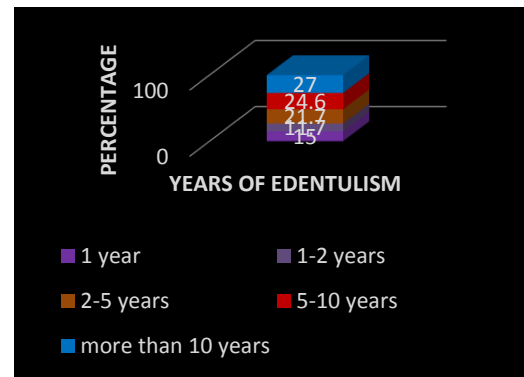


Fig. 2: Distribution of study subjects according to years of edentulism

Table 1: Distribution of subjects according to grade of ridge resorption and years of edentulism

	Years					Total
	1 year	1-2 years	2-5 years	5-10 years	more than 10 years	
Grade 1	44	26	12	8	1	91
Grade 2	1	9	53	62	41	166
Grade 3	0	0	0	4	39	43
Total	45	35	65	74	81	300

Pearson Chi-Square= 2.619E2^a, df=8, p=0.000

Discussion

Bone resorption is a chronic, progressive, irreversible and disabling disease of multifactorial origin. Various Anatomic, Metabolic; Functional and Prosthetic factors play a role in resorption of residual ridges which is a common occurrence after the extraction of teeth. The size, shape, and density of ridges, the thickness and character of the mucosal

covering, ridge relationships, and the number and depth of sockets are some of the anatomic factors playing a key role in Residual Ridge Resorption. Metabolic factors include all of the multiple nutritional, hormonal, and other factors influencing the relative cellular activity of osteoblasts and osteoclasts. The frequency, intensity, duration and direction of forces applied to bone are some of the functional factors contributing to the RRR. Prosthetic factors include the myriad of techniques, materials, concepts, principles, and practices which are incorporated into the prostheses.⁽³⁾

Loss of bone in the maxilla or mandible is not limited to alveolar bone; portions of the basal bone may also be resorbed, especially in the posterior aspect of the mandible, where severe resorption may result in more than 80% bone loss.⁽⁴⁾ An increase in resorption eventually leads to smaller maxillae and larger mandibular residual ridges due to shape of the basal bone. Thus the residual alveolar ridge crest changes its location in a buccolingual direction after resorption. In addition, the tongue has a tendency to enlarge in the edentulous mouth. These factors influence the buccolingual position of the neutral zone (NZ).⁽⁵⁾

Wical and Swoop concluded that the relationship of the mental foramen and lower border of the mandible remains relatively constant in spite of increasing age or resorption of the residual ridge above the mental foramen. Also, mental foramina are a permanent point of reference, no matter how much resorbed the ridge is.⁽⁶⁾ It is situated in premolar areas, so act as point of transition from anterior to posterior areas. So it's a much easier, convenient and reliable method of assessing ridge resorption.

In this study, using Wical and Swoop Classification, subjects were categorized into three groups and a comparison was made between them to assess the highest no. of resorption pattern. Group 2 had highest prevalence whereas group 3 had lowest. The results of the study showed that most prevalent type of resorption in the current study population was group 2.

Centre of the ridge is considered to be the most accepted position for placement of artificial teeth after all the teeth are lost.⁽⁷⁾ But the placement of artificial teeth should be in the same relative position to the musculature as the natural teeth.⁽⁸⁾ The term relative position rather than exact position is used because factors such as age, tonus, resorption modify or alter the denture space and neutral zone. So the artificial teeth do not necessarily need to be placed in the exact same position as natural teeth as the resorption increases. One should not be dogmatic regarding the placement of teeth over the crest or lingual or buccal to the ridge but the placement of teeth should be dictated by musculature. Positioning artificial teeth in neutral zone prevents interference of artificial teeth with normal muscle function and hence adds to the stability of the denture.

In addition, various anatomical and physiological factors affect mandibular complete denture fabrication with aging. Various changes occur in the mucosa, submucosa, musculature and the bone with the passage of time which in turn affects the mandibular denture. Reduction in the surface area of the oral mucosa along with its thinning occur as the human body ages. Prominent mylohyoid and internal oblique ridges covered by thin, movable, unattached mucosa are caused by continued atrophy of the posterior mandible eventually.⁽¹⁰⁾ Also, due to progressive resorption, the origin of buccinator muscle fibres lies upon the superior surface of the mandible. The superior genial tubercles eventually become the most superior aspect of the anterior mandibular ridge as the anterior residual alveolar process also continues to resorb. Also, the level of ridge crest falls below the former origin of the superior fibres of mentalis muscle. The muscle attachment folds over the resorbing alveolar ridge and comes to lie on its superior surface which results in the backward movement along with reduction of neutral zone anteriorly in order to maintain its area of origin.⁽¹⁰⁾ The movement and interaction of the lip and the tongue determine the position of the lower anterior teeth. The denture will be displaced posteriorly by the contraction of the lip, if lower anterior teeth are positioned too far labially. The ridge can also resorb to such an extent that the mentalis muscle displaces the neutral zone lingually and anterior tooth position becomes even more vital for the success of the denture. The Neutral Zone technique provides the correct tooth position to allow for the balancing of these muscular forces during function.

Also, greater the ridge loss, the smaller the denture bearing area and the lesser will be the influence the impression surface area on the stability and retention of the denture. As the area of the intaglio surface decreases and the anatomic surface area increases, tooth position and contour of the polished surface become more critical. In other words, denture stability and retention are more dependent on correct position of the teeth and contour of the external surfaces of the dentures whenever more of the alveolar ridge has been resorbed.⁽⁸⁾

Conclusion

The following conclusions were drawn from the present study:

- Most prevalent type of resorption in the current study population was grade 2 i.e. in most of the subjects; one third to two third of the original height of mandible was lost.
- Severity of resorption also increases with the increase in period of edentulism.

References

1. Atwood DA. Reduction of residual ridges: A major oral disease entity. *J Prosthet Dent*1971;26:266-79.
2. Wical KE, Swoope CC. Studies of residual ridge resorption. Part I. Use of panoramic radiographs for evaluation and classification of mandibular resorption. *J Prosthet Dent*1974.32(1):7-12.
3. Atwood DA. Some clinical factors related to rate of resorption of residual ridges. *J Prosthet Dent*12;1962: 441-450.
4. Misch CE. *Contemporary Implant Dentistry*. 3rd edition. Mosby. 2008:3-25;105-130.
5. Fahmi FM. The position of the neutral zone in relation to the alveolar ridge. *J Prosthet Dent*1992;67:805-9.
6. Gabriel A.C. *Journal of Anatomy*. Some anatomical features of the mandible.92(4):582-86.
7. Winkler S. *Essentials of complete denture Prosthodontics*. 2nd ed. St. Louis: Mosby;1988.22-38.102-103.
8. Fish EW. *Principles of full denture prosthesis*. 5th ed. London. 1952: Staples press limited;32-101.
9. Beresin VE, Schiesser FJ: *The Neutral Zone in Complete and Partial Dentures*. St Louis. The C.V. Mosby Co:1973;31-45.
10. Lammie GA. Aging changes in the complete lower denture. *J Prosthet Dent*1956;6:450-64.
11. Tuckfield WJ. The problem of the mandibular denture. *J Prosthet dent*1953;3(1):8-28.
12. Rinaldi P, Sharry J. Tongue force and fatigue in adults. *J Prosthet Dent*.1963;13(5):857-865.
13. Brill N, Tryde G, Cantor R. The dynamic nature of the lower denture space. *J Prosthet Dent*1965;15:401-18.
14. Baylink DJ, Wergedal JE, Yamamoto K, Manzke E. Systemic factors in alveolar bone loss. *J Prosthet Dent*1974;31(5):486-505.
15. Al Magaleh WR, Swelem AA, Shohdi SS, Mawsouf NM. Setting up of teeth in neutral zone and its effect on speech. *The Saudi Dental Journal*2012;24:43-48.