

Taurodontism of multiple deciduous teeth: A case report

Anshul^{1,*}, Arvind Kumar²

¹Professor, IDS, Bareilly, ²Professor, Dept. of Pedodontics & Preventive Dentistry, Buddha Dental College, Patna, Bihar

***Corresponding Author:**

Email: gangwaranshul2001@gmail.com

Abstract

Taurodont teeth are characterised by large pulp chambers at the expense of roots. An enlarged pulp chamber, apical displacement of the pulpal floor and no constriction at the level of the cement-enamel junction are the characteristic features of taurodont tooth. Permanent dentition is more commonly affected than deciduous dentition. This paper presents a case of multiple taurodontic deciduous molars and treatment of taurodontic carious mandibular deciduous second molar without its permanent successor using white mineral trioxide aggregate (MTA).

Keywords: Taurodontism, Deciduous molars, Pulpectomy, MTA obturation, Agenesis

Introduction

Taurodontism according to Stedman's Medical Spellchecker 2006 is a developmental anomaly involving molar teeth in which the bifurcation or trifurcation of the roots is very near the apex, resulting in an abnormally large and long pulp chamber with exceedingly short pulp canals.⁽¹⁾

The term taurodontism was first defined in 1913 by Sir Arthur Keith,⁽²⁾ although Gorjanovic-Kramberger in 1908 had first described this type of tooth.

As a dental anomaly, taurodontism is characterized externally as a bull-like heavily bodied tooth in which crown tends to enlarge at the expense of root. The enlargement of the pulp chamber may even reach the proximity of the root apex. This leads to the apical displacement of bifurcation/trifurcation of the roots. The crown thus lacks the constriction (cervix of tooth) at the level of the CEJ giving it a heavy rectangular shape.^(3,4) It was divide into three types, as hypotaurodontism, mesotaurodontism and hypertaurodontism, depending on the relative amount of apical displacement of the floor of the pulp chamber.⁽⁵⁾

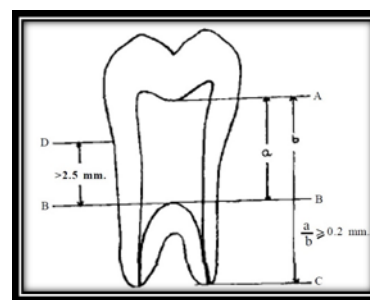
The exact cause of taurodontism is unclear. It has diverse possible causes which include, an unusual developmental pattern, a delay in the calcification of the pulp chamber floor, an odontoblastic deficiency, an alteration in Hertwig's epithelial root sheath, with an apparent failure of the epithelial diaphragm to invaginate at the normal horizontal level and "a delayed or incomplete union of the horizontal flaps of the epithelial diaphragm".^(6,7)

According to some authors, taurodontism is most likely the result of disrupted developmental homeostasis.⁽⁸⁾

Taurodontism appears most frequently as an isolated anomaly, but it has also been found to occur along with several well-known syndromes due to alterations of sex chromosomes, such as Klinefelter's syndrome, Trisomy 21 or Down's syndrome, Wolf-

Hirschorn syndrome and Trichodonto-osseous syndrome.⁽⁹⁾ Some recent reports have described an association between taurodontism, familial inheritance, and genetic malformations.⁽¹⁰⁾

Though there are many classification systems to determine the severity of taurodontism, the classification proposed by Shifman and Chanannel is the widely used system till now. In 1978, Shifman and Chanannel proposed the following criteria for determining the presence or absence of taurodontism. Taurodontism is present, if the distance (a) from the lowest point (A) at the occlusal end of the pulp chamber to the highest point at the apical end of the chamber (B), divided by the distance (b) from the occlusal end of the pulp chamber to the apex (C) is 0.2 mm or greater, that is, $a/b = 0.2$ mm and if the distance from the highest point of the pulp chamber floor to CEJ is more than 2.5 mm.⁽¹¹⁾ (Fig. 1)



A: pulp chamber roof B: pulp chamber floor C: apex

Fig. 1: Measurement used to determine taurodontism

The diagnosis of taurodontism is based on a subjective radiographic evaluation as the external morphology of the teeth is within normal configurations. The most important aspect of this rare dental anomaly is due to difficulties encountered in performing endodontic treatment.

The second premolar has the highest incidence (5%) of congenital absence after the third molar (22%). This problem is more highlighted by the need to save primary teeth with treatment that yield a more reliable result over the long term. At present, agenesis cases are managed through two options either to extract primary second molar and allowing the permanent first molar to drift mesially with a final orthodontic correction or maintaining the deciduous tooth until the patient is old enough for the implant or any prosthetic solution. It is well acknowledged that most of the cases with extraction will lead to arch length discrepancy and space loss. This would in turn require a longer period of orthodontic treatment in order to push the first molar back and provide sufficient space for implant placement. Therefore, it's advised to maintain the second primary molar in case of a missing successor.

Pulpectomy is indicated in primary teeth with carious pulp exposure. To date, several root canal filling materials have been introduced for primary teeth including: zinc oxide eugenol (ZOE), Kri paste, Maistopaste, vitapex, Endoflas and more recently MTA and CEM.

This case report documents MTA as root canal filling material in pulpectomy of a taurodontic deciduous mandibular second molar with no permanent successor.

Case Report

A healthy 6-year-old boy was reported with the complaint of a toothache in the right mandibular molar region. Clinical examination showed carious mandibular right second primary molar (85) to be symptomatic to percussion. Patient's mother gave the past dental history of extraction of 74,75,84 due to severe pain and pus discharge.

The intra oral radiographic findings were (Fig. 2) a) Unusually long pulp chamber which had no constriction at the cemento-enamel junction. b) No distinct roots were found but large canal openings, ending at the apex were observed. c) agenesis of follicle of second premolar.

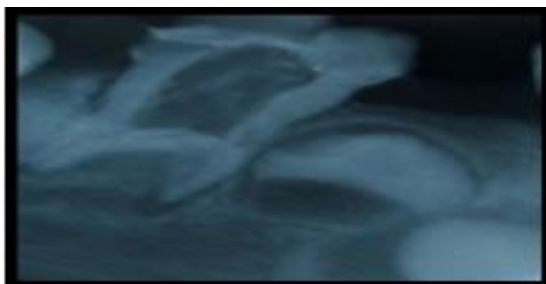


Fig. 2: Intra oral radiograph revealed taurodontics 85 and missing 45

From these radiographic findings, the tooth was diagnosed to be a hypertaurodontic.

Based upon clinical and radiographic examination, a diagnosis for the 85 was made of chronic irreversible pulpitis and no evidence of ankylosis or infra-occlusion.

According to the patient's mother, there was no family history of tooth agenesis and such anomaly.

An initial treatment plan was developed that aimed to avoid any future malocclusion by maintenance of the 85 for as long as possible. After evaluating treatment options, the decision was made to treat the 85 by pulpectomy using WMTA.

The treatment objectives were explained to his parents, who provided their written consent prior to treatment.

The tooth was anaesthetized, the access was opened and the remaining pulp tissue was extirpated. The pulp was voluminous, to ensure complete removal, 2.5% sodium hypochlorite and normal saline was used alternatively as an irrigant to soften the pulp. The pulp chamber was huge and the floor of the chamber could not be visualized. At the furcation area, four canal orifices were found: mesiobuccal, mesiolingual, distobuccal and distolingual.

After the chemomechanical preparation, the canals were dried with sterile paper points, and a white MTA mixture (ProRoot, Dentsply, Tulsa Dental, OK, USA) was prepared using sterile water according to the manufacturer's instructions. The WMTA mixture was condensed into the canals by using finger pluggers and adaptation was checked by digital radiography. After confirming placement of WMTA, obturation was done up to predetermined root canal length. Then, a cotton pellet moistened with sterile water was placed in the pulp chamber and sealed by temporary dressing. After 24 hrs patient was recalled and postendodontic restoration was done with glass ionomer cement followed by stainless steel crown.

An orthopantomograph (Fig. 3) was advised which revealed that all maxillary deciduous molars (54, 55, 64, 65) were non carious and with enlarged pulp chambers suggesting taurodontism and bilateral congenitally missing mandibular second premolar. Taurodontism could not be commented in permanent first premolars and molars due to early developmental stage.

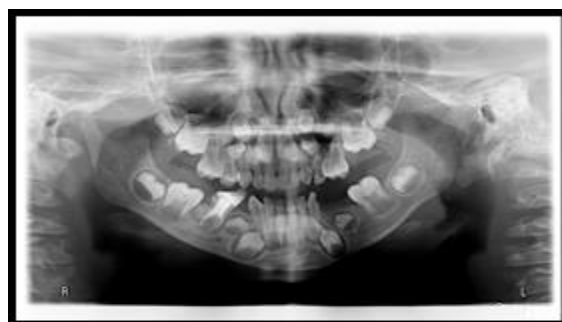

Fig. 3: OPG showing taurodontic 54, 55, 64, 65 & bilateral agenesis of mandibular second premolar

Mandibular bilateral functional space maintainer was delivered and regular recall visits were scheduled. Patient had reported no complaint and treated tooth represented no clinical sign of a problem at three months review.

During the recall visits patient was asymptomatic and also satisfied with the treatment.

Discussion

Taurodontism is a rare morphological variation which causes the occluso-apical elongation of the pulp chamber, and the reduction of the root size. Although taurodontism generally occurs in patients who do not have any syndrome, there are occasional reports of an association with certain syndromes and dental developmental disorders, including hypodontia, amelogenesis imperfecta, dentinogenesis imperfecta, ectodermal dysplasia.^(9,12)

Taurodontism may be unilateral or bilateral and seen in posterior teeth. It affects permanent teeth more frequently than primary teeth. The reason for these differences could be attributed to ethnic variations and to the methods used to detect taurodontism. Also, the causes for the differences of the prevalences between the primary and permanent dentition might be that the primary teeth have different root and crown morphology and the numbers of posterior teeth in permanent dentition are higher than in primary dentition.

The prevalence of taurodontism is reported to range from 2.5% to 11.3% of the human population and in children was found in 0.3%.⁽¹³⁾ In a study, it has been accounted for 18% of all of the anomalies.⁽¹⁴⁾

The radiographic appearance of taurodonts should be differentiated from other conditions which may demonstrate enlarged pulp chamber like: 1) The “shell teeth” of dentinogenesis imperfecta (Brandywine type) which have large pulp chambers resulting from the relative absence of dentin. 2) The teeth in regional odontodysplasia, “ghost teeth”, 3) In hypophosphatasia and/or vitamin D resistant rickets, the teeth are hypocalcified and harbor large horns rather than pulp chamber. 4) Pseudohypoparathyroidism teeth exhibit enlarged root canals with lack of apical closures 5) Internal resorption of teeth may also produce larger pulp chambers due to loss of pulpal dentin.

The clinical implication of taurodontism has potentially increased risk of pulp exposure. A taurodont tooth shows wide variation in the size and shape of the pulp chamber, varying degrees of obliteration and canal configuration, apically positioned canal orifices, and the potential for additional root canal systems.

Thus, endodontic treatment in taurodontism teeth has been described as a complex and difficult procedure, with increased incidence of haemorrhage during access opening which may be mistaken for perforation.

The most common congenitally missing permanent teeth after third molars are second premolars and lateral incisors. Primary teeth with missing successor is critically important to enable its preservation in a longer period than routinely expected. The physiologic resorption of the deciduous molars without second premolar occurs at an average age of 22 years, 10 years later than normal exfoliation time estimate. Longer term follow ups have revealed that if the retained primary tooth is left with an empty root canal and no resorption or other pathologies, it will become ankylosed and will appear to be submerged.⁽¹⁵⁾

In the case of primary teeth with no permanent successors, pulpectomy treatment is performed in the same manner as with permanent teeth. Conventionally resorbable paste can be used for primary teeth pulpectomies in order to give the chance of absorption of the material by the patient’s defense mechanism following physiologic root resorption. However, this is not the case when a subsiding tooth is missing.

In the pulpectomy of a pulpally involved primary tooth with a missing permanent successor, the canals are filled with gutta-percha following reconstruction of the crown. However, there are inherent limitations involved in preparing curved, fragile primary molar roots to a proper master apical file size, and it may be difficult to achieve adequate obturation. Because of complications in gutta percha, Mineral trioxide aggregate (MTA) has been recommended as a root-canal filling material in pulpectomies of minimally filed and shaped roots of retained primary teeth.^(16,17) But due to MTA’s resistance against resorption their use in routine pulpectomy of primary teeth is abandoned while in the cases where preservation of primary molar is in line such materials could be reconsidered for use.

Mineral trioxide has bioactive and biomineralizing properties. Biomineralization property of MTA forms hydroxyapatite crystals that helps in bonding with dentin to provide mechanical strength and also has the alkaline nature to restrict the activity of osteoblastic cells. MTA exhibits superior antibacterial and bioinductive properties that can improve treatment outcomes. Furthermore, the material is sterile, radiopaque, resistant to moisture, nonshrinking and stimulate responsible for the bioremineralization. Because of these characteristics, MTA might become a viable alternative treatment option.

In the presented case patient had normal development of height– weight relationship with regard to the average percentile of children of his age. The patient’s language and psychomotor skill development was consistent with his age. The case could not be associated to any syndrome. WMTA was selected as a root-filling material because of MTA’s biocompatibility and its role in enhancing regeneration of periradicular tissue.

Conclusion

Taurodontism is a rare occurrence, which requires a thorough clinical and radiographic examination to help in proper diagnosis and treatment planning. The clinician should be aware of the complex canal system for its successful endodontic management.

References

1. Stedman's Medical Spellchecker 2006 Source, 2006. Philadelphia: Lippincott Williams and Wilkins.
2. Keith A. Problems relating to the Teeth of the Earlier Forms of Pre-Historic Man. Proceedings of the Royal Society of Medicine 1913;6:103-24.
3. Kosinski RW, Chaiyawat Y, Rosenberg L. Localized deficient root development associated with taurodontism: A case report. *Pediatr Dent* 1999;21:213-215.
4. R Llamas, A. Jimenez-Planas. Taurodontism in premolar. *Oral Surg Oral Med Oral Pathol* 1993;75:501-505.
5. Shaw JC. Taurodont Teeth in South African Races. *Journal of Anatomy*. 1928;62:476-498.
6. Jafarzadeh H, Azarpazhooh A and Mayhall JT. Taurodontism: a review of the condition and endodontic treatment challenges. *International Endodontic Journal* 2008;41:375-388.
7. Venkataraghavan K, Choudhary P, Karthik S, et al. Taurodontism in Primary Teeth: A Review and Report of a Case. *Journal of Dental & Oro-facial Research* 2014;10(2):28-31.
8. Manjunatha BS, Kovvuru SK. Taurodontism –A Review on its etiology, prevalence and clinical consideration. *J Clin Exp Dent* 2010;2(4):e187-90.
9. Reddy. VN, Rao AP et al. Endodontic Treatment in Primary Molars with Taurodontism– A case report. *Annals and Essences of Dentistry* 2010;2(2):52-55.
10. Mahajan SK, Jindal R, Sharma K. Taurodontism of deciduous molars: An overview and a case report. *Indian Journal of Oral Sciences* 2013;4(3):134-137.
11. Shifman A, Chanannel I. Prevalence of taurodontism found in radiographic dental examination of 1,200 young adults Israeli patients. *Community Dent Oral Epidemiol* 1978;6:200-3.
12. Simsek H., Bayrakdar IS, Yasa Y., et al. Prevalence of Taurodont Primary Teeth in Turkish Children. *Oral Health and Dental management* 2015;14(1):23-26.
13. Bäckman B, Wahlin YB. Variations in number and morphology of permanent teeth in 7-year-old Swedish children. *Int J Paediatr Dent*. 2001;11:11-7.
14. Guttal KS, Naikmasur VG, Bhargava P, Bathi RJ. Frequency of Developmental Dental Anomalies in the Indian Population. *Eur J Dent*. 2010;4:263-9.
15. Bjerklin, K, J Bennett. Long term survival of lower second deciduous molars in subjects with agenesis of the premolars. *Eur. J. Orthod* 2000;22:245-255.
16. Bezgin T, Ozgul B M et al., Root canal filling in primary molars without successors: Mineral trioxide aggregate versus gutta-percha/AH-Plus. *Australian Endodontic Journal* 2015; doi: 10.1111/aej.1213.
17. O'Sullivan SM, Hartwell GR. Obturation of a retained primary mandibular second molar using mineral trioxide aggregate: a case report. *J Endod* 2001;27:703-705.