

Full mouth occlusal rehabilitation: by Pankey Mann Schuyler philosophy

Jinsa P. Devassy¹, Ankitha Sivas², Shabas Muhammed³

¹Consultant Prosthodontist, Ernakulam, Kerala, ²Assistant Professor, ³PG Student, Dept. of Prosthodontics, Kannur Dental College, Kerala

***Corresponding Author:**

Email: jinsa.pd@gmail.com

Abstract

Most of the cases with severe attrition of teeth need full mouth occlusal rehabilitation. There are many philosophies to follow for an occlusal rehabilitation, most important among them is Hobo's philosophy and Pankey Mann Schuyler philosophy. Pankey Mann Schuyler philosophy is a simple, organized procedure to follow for the full mouth rehabilitation cases. This article describes a case of full mouth occlusal rehabilitation of a 59 years old male patient who reported with pain over left TMJ region and oral examination revealed severe attrition on lower anterior teeth. The treatment followed Pankey Mann Schuyler philosophy and the occlusal analysis done using Broadrick flag.

Keywords: Full Mouth Occlusal Rehabilitation, Anterior Guidance, Broadrick Flag, Pankey Mann Schuyler Philosophy.

Introduction

Full mouth rehabilitation poses a significant challenge to dentistry, to get good functional and esthetic results we have to follow various prosthodontic principles. The goal of dentistry is to increase the life span of the functioning dentition, just as the goal of medicine is to increase the life span of functioning individual.⁽¹⁾ Apprehensions involved in reconstruction for debilitated dentitions are heightened by widely divergent views concerning the appropriate procedure for successful treatment. Most philosophies and associated techniques for full mouth rehabilitation shows similar characteristics based on an author specific philosophy of occlusion.⁽²⁾

Attrition of teeth is a very common in routine clinical examination. Many times patients are unaware about the ongoing process and realize it only when sufficient loss of teeth structures has occurred. Various factors such as vertical dimension of occlusion, centric relation, occlusal pattern, esthetics and phonetics needs to be considered simultaneously for both anterior and posterior teeth during rehabilitation. This may be further complicated by existing restorations, pulpal exposure, missing teeth, tooth sensitivity, supra erupted teeth and TMJ pain.⁽³⁾

This case report describes a full mouth occlusal rehabilitation done using Pankey Mann Schuyler philosophy.

Case Report

This clinical case report describes the rehabilitation of a 59 years old male patient complaining pain over left TMJ region especially at morning. Examination revealed partially edentulous maxillary ridge, severe attrition of lower anterior teeth, supra erupted lower first molars (36 and 46) and it is impinging the maxillary alveolar ridge. (Fig. 1, 2 & 3).

Different treatment plans were discussed and we planned to give maxillary cast partial denture and mandibular fixed crowns. The lost vertical dimension was determined and found it as 1.5mm following three methods Niswonger's method, Silverman closest speaking method⁽⁴⁾ and facial measurement method. Patient was given occlusal splint for two months for increasing the bite. During that time root canal treatment and periodontal treatments were completed. The case had been reviewed weekly, TMJ was examined and it was planned to restore 1.5mm of lost vertical dimension. Different philosophies are available for full mouth rehabilitation. We followed Pankey Mann philosophy. According to Pankey Mann philosophy, treatment is divided into 4 stages.⁽⁵⁾ Step 1: Examination, diagnosis, treatment planning and prognosis. Step 2: Harmonization of anterior guidance for the best possible esthetics, function and comfort. Step 3: Selection of acceptable occlusal plane and restoration of lower posterior occlusion in harmony with anterior guidance ie in a manner that will not interfere with condylar guidance. Step 4: Restoration of upper posterior occlusion in harmony with anterior guidance and condylar guidance.

We had done face bow transfer using spring bow (Fig. 4). Interocclusal records were taken and diagnostic mount up and mock up models were done using Hanau wide view articulator. Anterior guidance was established. In this case, lower anteriors were restored and temporary crowns were given. Esthetics, function and comfort of the patient were assessed. Then came the third part of the treatment i.e. the occlusal plane analysis. We analysed it using Broadrick flag analyzer. (Fig. 5). The caliper was set at a radius of 4 inch from needle point to pencil point (Fig. 6). Needle point of the caliper is placed against the selected point on premolar and an arc was scribed on the flag (anterior survey line). (Fig. 7). Caliper point is held against the condyle ball of the articulator and another arc is made in flag (condylar survey line) (Fig. 8). From the intersect point a line is drawn from molar to

canine (Fig. 9). Thus we got an accepted occlusal plane for the lower posteriors. To transfer this to mouth a wax guide is made and held against the teeth and preparation line 1.5 mm below the plane is marked on the teeth, giving space for the restoration (Fig. 10, 11). After the temporization of lower posteriors maxillary treatment RPD given in harmony with anterior guidance and condylar guidance (Fig. 12, 13). Temporization period for two month and patient is reviewed once in two weeks. Patient is comfortable with new bite (Fig. 14) and permanent crowns and maxillary cast partial denture were given (Fig. 15, 16). Pre and post treatment pictures are shown. (Fig. 17, 18).

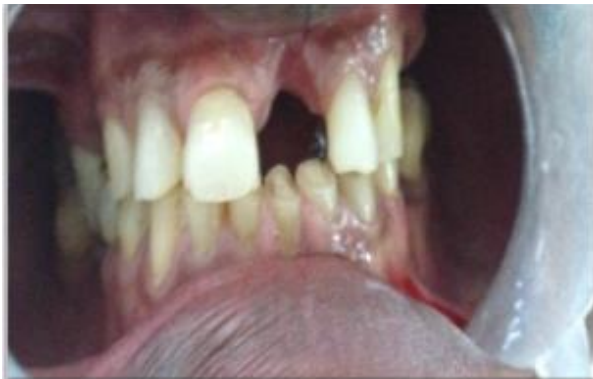

Fig. 1: Attrited mandibular anteriors and missing maxillary left central incisor (21)

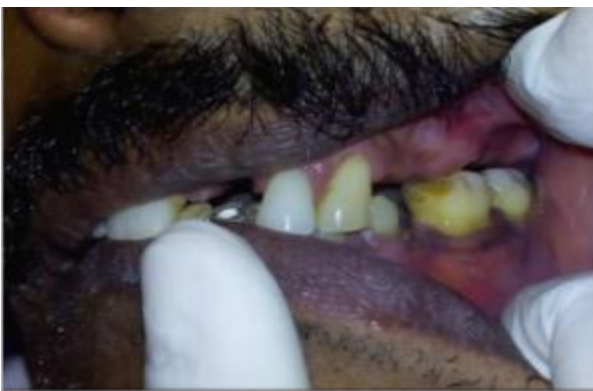

Fig. 2: Supraerupted mandibular left molars impinging maxillary alveolar ridge

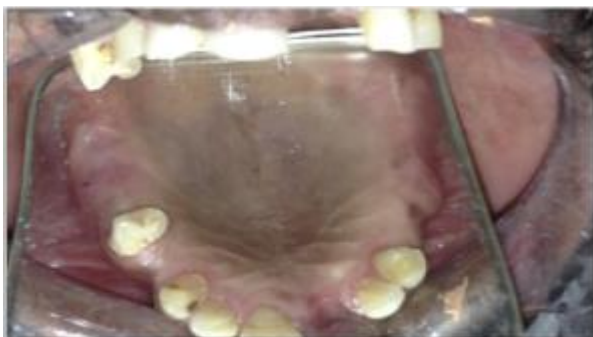

Fig. 3: Maxillary partially edentulous ridge (Kennedy class I modification 2)

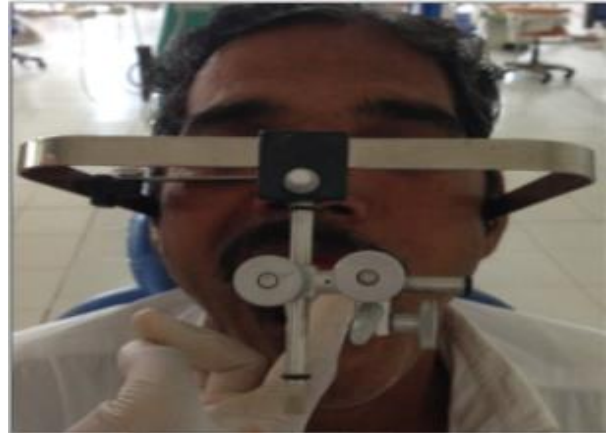


Fig. 4: Face bow transfer



Fig. 5: Broadrick flag analyzer



Fig. 6: Four inch radius is set for the caliper



Fig. 7: Anterior survey line




Fig. 10: Wax guide



Fig. 8: Condylar survey line

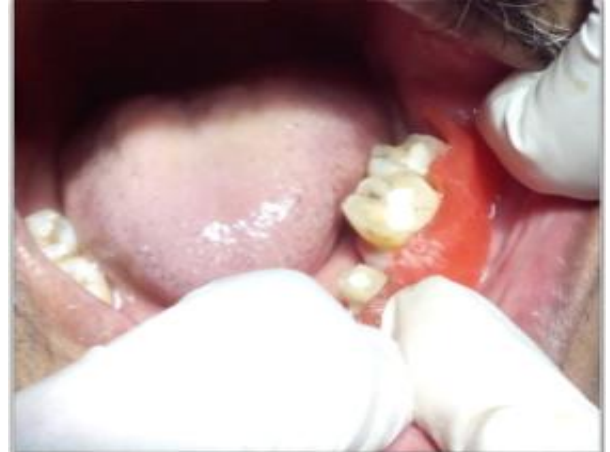

Fig. 11: Wax guide held against the teeth



Fig. 9: Line is drawn from molars to canine from intersecting point

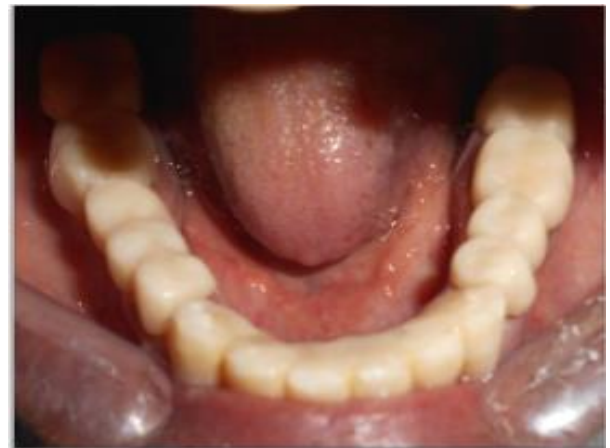

Fig. 12: Temporary lower crowns

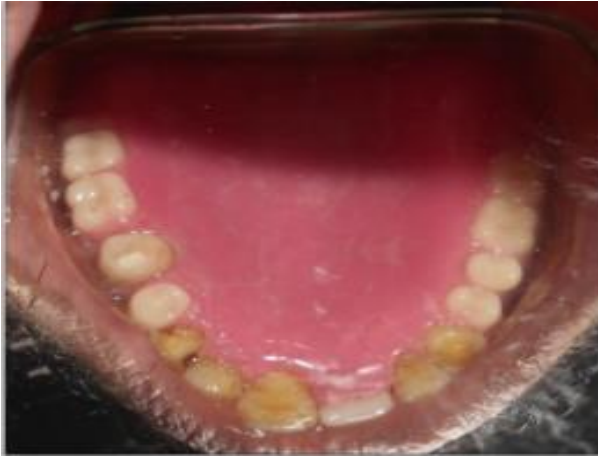

Fig. 13: Maxillary temporary RPD

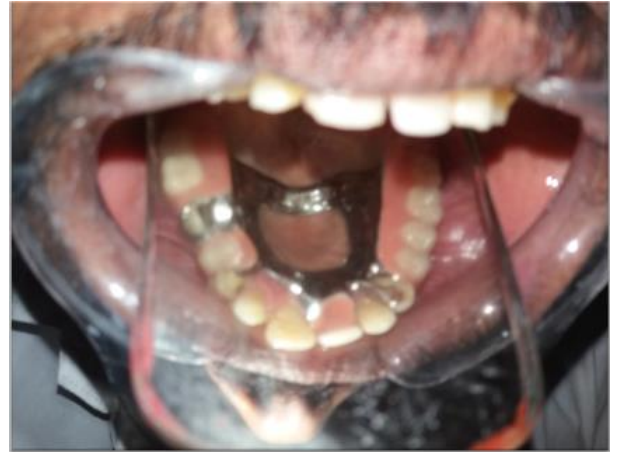

Fig. 16: Maxillary cast partial denture

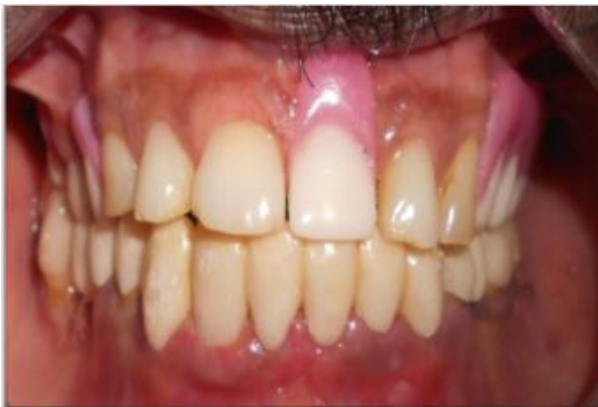

Fig. 14: Temporary full mouth occlusal rehabilitation with increased vertical dimension

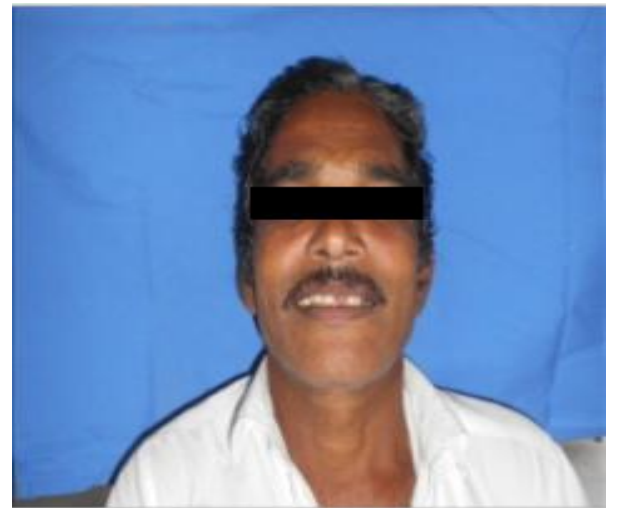

Fig. 17: Pre-operative

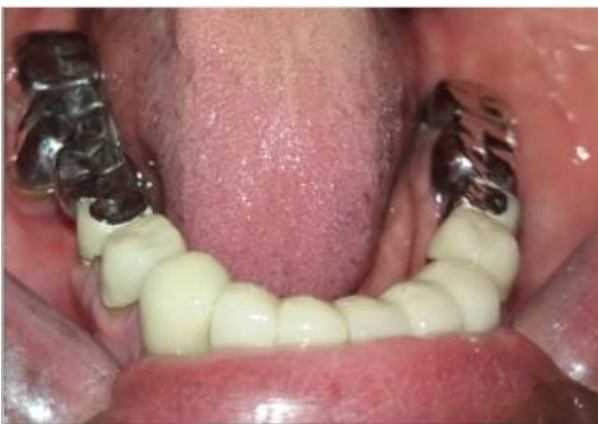

Fig. 15: Mandibular permanent crowns



Fig. 18: Post-operative

Discussion

Mouth rehabilitation seeks to convert all unfavourable forces on the teeth which inevitably induce pathologic conditions, into favourable forces which

permit normal function and therefore induce healthy conditions.⁽¹⁾ Here in this case, patient had lost maxillary posteriors around fifteen years back. He started chewing in front and eventually attrition of lower anteriors and supraeruption of lower posteriors have occurred. After the full mouth occlusal rehabilitation, patient got good functional occlusion and we reviewed several times and no further problems occurred even two years after the treatment.

There are many philosophies to follow for an occlusal rehabilitation, most important among them is Hobo's philosophy and Pankey Mann Schuyler philosophy. Pankey Mann Schylur philosophy is one of the most practical philosophies for occlusal rehabilitation. It is well organized logical procedure that progresses smoothly with less wear and tear on the patient operator and technique.⁽⁵⁾ Optimum oral health should be prime objective of the rehabilitation procedures, because the ultimate goal will always be to restore the mouth to health and preserve this status throughout life of a patient.⁽⁶⁾ Pankey and Mann introduced an instrument for occlusal plane analysis, here we used simplified version of the instrument i.e. customized broad rick flag analyzer. This assists in the reproduction of tooth morphology that is commensurate with the curve of Spee when posterior restorations are designed.⁽⁷⁾

Conclusion

For a successful occlusal rehabilitation, the dentist should have thorough knowledge about functional occlusion, hinge axis, eccentric path, centric relation, occlusal vertical dimension and plane of occlusion. By following Pankey Mann Schuyler philosophy the treatment can be completed more quickly and easily and with much more comfort for the patient. The patients appreciate anything which expedites having their work finished faster so that they can enjoy the oral health, comfort, functional efficiency and esthetics which are prime objectives of oral rehabilitation.⁽⁶⁾

References

1. Irving Goldman. The goal of full mouth rehabilitation. *J pros Dent* 1952;2:246-251.
2. T.K. Binkley, C. J. Binkley. A practical approach to full mouth rehabilitation. *The Journal of Prosthetic Dentistry* 1987;57:3;261-265.
3. Manoj Shetty, Niranjana Joshi et al. Complete Rehabilitation of a patient with occlusal wear. A case report. *Journal of Indian Prosthodontic Society* 2012;12:191-197.
4. Meyer M. Silverman. The speaking method in measuring vertical dimension. *J. Pros. Dent* 1953;3:2;193-199.
5. Evaluation, diagnosis and treatment planning of occlusal problems- 2nd edition by Peter E Dawson. Page no. 262.
6. Mann, Pankey. Use of P.M instrument in treatment planning and in restoring the lower posterior teeth. *J Pros dent* 1960;10:135-150.
7. Christopher D Lynch, Robert J Mc Connell. Prosthodontic management of the curve of spee: use of the broadrick flag. *J Prosthet Dent* 2002;87:593-7.