

Pier abutment: Break the stress

Aditi Mishra^{1,*}, Jayant Palaskar², VNV Madhav³, Swapnil R. Chopade⁴

¹Senior Resident, Dept. of Dentistry, All India Institute of Medical Sciences, Jodhpur, ²Professor & HOD, Sinhgad Dental College & Hospital, Pune, ³Professor & HOD, DY Patil Dental School, Pune, ⁴Assistant Professor, Dept. of Prosthodontics, Bharti Vidyapeeth Dental College, Sangli

***Corresponding Author:**

Email: draditimishra89@gmail.com

Abstract

Use of a conventional rigid five-unit fixed dental prosthesis is a less than ideal plan of treatment in pier abutment cases due to physiologic tooth movement, arch position of the abutments, and a disparity in the retentive capacity of the retainers. A non-rigid connector is a broken-stress mechanical union of retainer and pontic, instead of the usual rigid connector. An innovative and cost effective way of fabricating a non-rigid connector is presented in this case report.

Keywords: Pier abutment, Stress-breaker, Non-rigid connector

Introduction

A common clinical situation that presents itself to a dentist is the missing first premolar and molar in maxillary or mandibular arch. For a fixed dental prosthesis (FDP) treatment plan, the canine and the second molar must act as terminal abutments while the lone standing second premolar with edentulous space on either side serves as the pier abutment. We, as dentists, are more accustomed to using rigid connectors in our FDPs. However, a completely rigid restoration is not indicated for this situation as physiologic tooth movement, arch position of the abutments, and a disparity in the retentive capacity of the retainers can make a rigid five-unit FDP a less than ideal treatment plan.⁽¹⁾

The more logical choice is a non-rigid connector (NRC) which is a broken-stress mechanical union of retainer and pontic.

Case History

A 48 year old female reported with the chief complaint of missing #24 and #26, difficulty in mastication and aesthetic issues (Fig. 1). Intraoral examination revealed the second premolar as non-carious and firm. Financial constraints prohibited the patient to opt for dental implants and hence, a five unit metal –ceramic FDP with the canine and second molar acting as terminal abutments and the second premolar as a pier abutment with a NRC was finalized as the treatment plan.

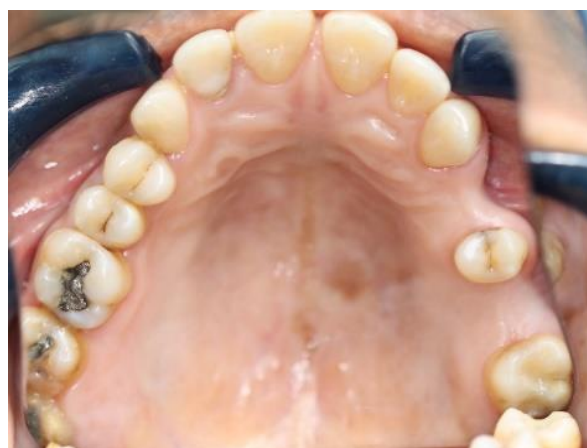

Fig. 1: Missing #24 and #26

Tooth preparation and gingival retraction was done (Fig. 2a) on #23, #25 and #27 followed by impression making using Two stage, double mix, putty- light body rubber base impression material (A- silicone, Aquasil, Dentsply) and poured in Type IV dental stone (Kalrock, Kalabhai). (Fig. 2b) Master casts were retrieved and mounted on semi-adjustable articulator using a face-bow transfer and inter-occlusal record. The provisional FDP was fabricated and cemented intraoral using non-eugenol provisional cement.

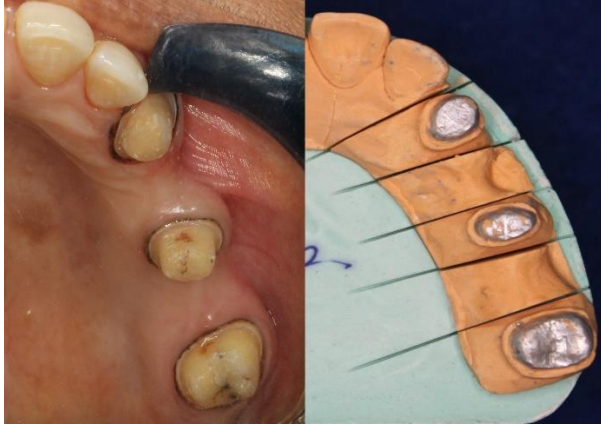


Fig. 2a: Tooth preparation with gingival retraction and 2b: Cast with die preparation

Wax pattern for the coping was made for the anterior three unit i.e. on the canine abutment, first premolar pontic and second premolar pier abutment. For a custom made female attachment (mortise), a die pin sleeve was then cut into half longitudinally and its height was adjusted according to the height of the pier abutment. The customized sleeve was then attached to the distal aspect of the pier abutment wax pattern using a surveyor and the pattern was casted. (Fig. 3)

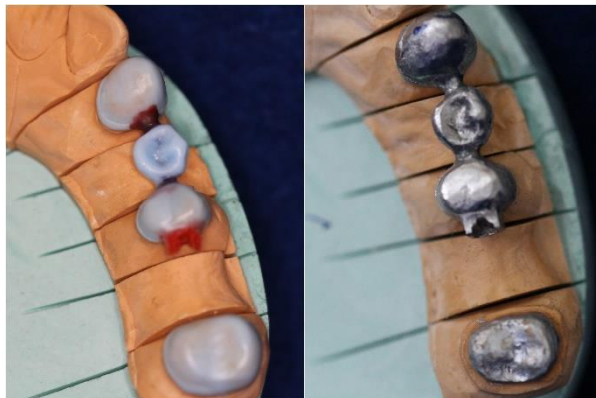


Fig. 3: Wax pattern and casting of anterior three unit FDP with die sleeve attachment

After the three unit casting with the female attachment was obtained, it was seated on the cast and the wax pattern of the posterior two unit FDP was made with a male attachment/ tenon extending into the previously casted customized female attachment. After the casting of the posterior two unit FDP (Fig. 4), it was fitted with the anterior unit and a metal coping trial was done in the patient's mouth (Fig. 5). After verifying the fit of the casting, as well as that of the customized tenon-mortise attachment, ceramic build up (Vita, Germany) was completed and the FDP was cemented (Fig. 6) after necessary occlusal adjustments using Glass Ionomer luting cement (Type I).

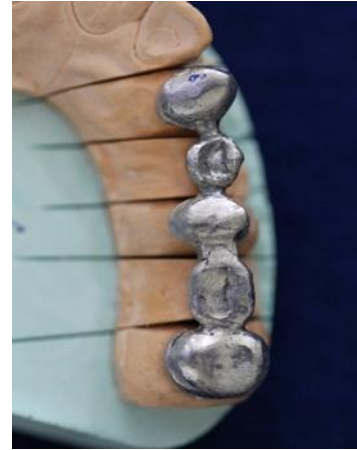

Fig. 4: Completed casting of anterior and posterior units with fitting of NRC

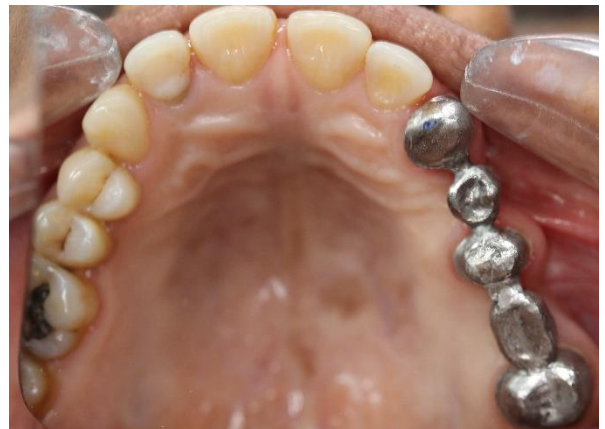

Fig. 5: Seating of the anterior and posterior copings and checking fit of the NRC intraorally

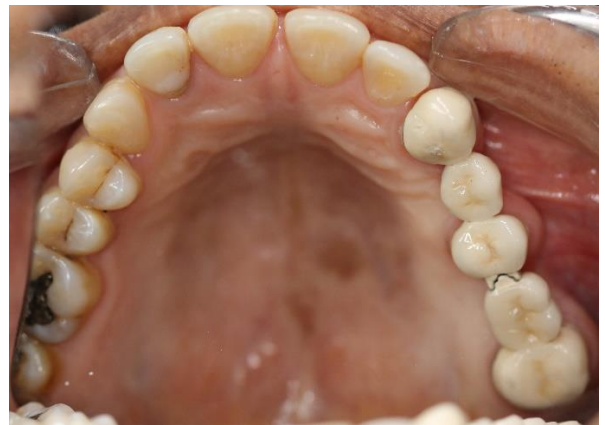

Fig. 6: Final Porcelain fused to metal prosthesis cemented intraorally

Discussion

Conventional rigid connectors are the preferred way of fabrication of FDP because it is the rigidity of the connection between the pontic and the retainers that provides desirable strength and stability to the prosthesis while minimizing the stresses associated with the restoration. However, this solution is not applicable in all

scenarios. In a pier abutment case, for example, because of the curvature of the arch, the bucco-lingual movement of an anterior tooth occurs at a considerable angle to the bucco-lingual movement of a molar. These forces and movements which are of considerable magnitude are directed in different directions and can create stress in a rigid long span prosthesis that is ultimately transferred to the abutments and the bone surrounding them.⁽²⁾

It was previously theorized that forces of mastication are transmitted to the terminal retainers as a result of the middle abutment acting as a fulcrum, causing failure of the weaker retainer if rigid connectors are used.⁽³⁾ However, photo elastic stress analysis and displacement measurement indicate that the prosthesis bends rather than rocks.⁽⁴⁾ Standlee and Caputo suggest that between the terminal retainers and their respective abutments, rather than a pier fulcrum, is the mechanism of failure.⁽⁴⁾ Intrusion of the abutments under the loading could lead to failure between any retainer and its respective abutment. The loosened casting will leak around the margin, and caries is likely to become extensive before discovery.⁽¹⁾

The NRC is the solution to this problem. The various types of NRC used today are the Tenon-mortise, the cross pin and wing, loop and the split pontic. The most commonly used are the tenon-mortise or the keyway type.

When a NRC is used in such a case, in spite of the seemingly close fit, it provides enough stress breaking so as to prevent the transfer of the forces from the segment being loaded to the rest of the FDP. The NRC transfers shear stress to supporting bone rather than concentrating it in the connectors and minimizes mesio-distal torqueing of the abutments while allowing them to move independently of each other.⁽⁵⁾ It aids in compensating for the difference in the resistance and retention form between the abutments. The design and passive fit of NRC is critical to the success of a long-span FDP.⁽⁶⁾

According to Shillingburg, the ideal location of the keyway is on the distal aspect of the pier abutment retainer while that of the key is on the mesial aspect of the distal pontic.⁽¹⁾ The reason is that the posterior teeth have a slight mesial inclination and have been shown to move more in this direction on application of occlusal forces.⁽⁷⁾ Placing the keyway on the distal aspect of the pier abutment helps in further seating of the key into the

keyway every time occlusal forces are applied. Placing the keyway mesial to the pier abutment retainer will tend to dislodge the key from the keyway on application of occlusal forces which in time might lead to fracture of the canine retainer or bone loss around the canine abutment. This placement is supported by Finite element analysis done by Oruc et al who said that the area of maximum stress concentration at the pier abutment was decreased by the use of a NRC at the distal region of the second premolar.⁽⁸⁾ Other authors advocated placing the NRC on the distal aspect of the pier abutment, and if desired, adding one more on the distal side of the anterior retainer.^(9,10)

Conclusion

The case report describes an innovative and cost effective way of fabricating a NRC for a pier abutment FDP case using a die-pin sleeve which is commonly available in any dental lab and at an iota of the cost of commercially available attachment systems.

References

1. Shillingburg HT, Sather DA, Wilson EL, Cain JR, Mitchell DL, Blanco LJ, et al. Fundamental of fixed Prosthodontics. *Chicago: Quintessence*; 2012;4:91-2.
2. Parfitt GJ: Measurement of the physiological mobility of individual teeth in an axial direction. *J Dent Res* 1960;39:608-18.
3. Shillingburg HT, Fisher DW. Non rigid connectors for fixed partial dentures. *J Am Dent Assoc* 1973;87:1195-9.
4. Standlee JP, Caputo AA. Load transfer by fixed partial dentures with three abutments. *Quintessence Int* 1988;19:403-10.
5. Sutherland JK, Holland GA, Sluder TB, White JT. A photoelastic analysis of the stress distribution in bone supporting fixed partial dentures of rigid and non-rigid designs. *J Prosthet Dent WBO*;44:616-23.
6. Badwaik PV, Pakahan AJ. Non rigid connectors in fixed Prosthodontics: current concepts with a case report. *J Ind Prostho Soc.* 2005;5:99-102.
7. Picton DCA: Tilting movements of teeth during biting. *Arch Oral Biol* 1962;7:151-9.
8. Oruc S, Eraslan O, Tukay HA, Atay A. Stress analysis of effects of non-rigid connectors on fixed partial dentures with pier abutments. *J Prosthet Dent* 2008;99:185-92.
9. Adams JD. Planning posterior bridges. *J Am Dent Assoc.* 1956;53:647-54.
10. Gill JR. Treatment planning for mouth rehabilitation. *J Prosthet Dent.* 1952;2:230-45.