

## “Endodontic Management of two Radix Entomolaris Cases having different Anatomic Diversities”

Akash Kumar Baranwal

Service Senior Resident, Faculty of Dental Sciences, IMS, BHU, Varanasi, Uttar Pradesh

Email: baranwalakash@yahoo.com

---

### Abstract

The knowledge of root canal anatomy and its variations may contribute to endodontic treatment success. It is known that the mandibular first molar may have different anatomical variations. A Radix Entomolaris (RE) with two distal roots is an interesting example of such anatomic diversity.

The presence of an additional root or canal can lead to difficulties during endodontic treatment. Identifying all the canals, cleaning, shaping and obturating the canals three dimensionally defines the success of the endodontic therapy.

The present article is about the endodontic management of two cases of mandibular first molar with different anatomic variations, one with an extra RE root and an extra distal canal while another with an extra RE root and canal using the magnification aid.

**Keywords:** Mandibular 1<sup>st</sup> molar, Radix entomolaris, extra root, Anatomic variations, Endodontic treatment.

---

### Introduction

Among the different causes of root canal treatment failures, an inability to localize and treat all of the root canals may be one of them. Because of varying complexity of the root canal system, the risk of missing anatomy or canal may be high. The mandibular first molar may often show the anatomical variations in its root canal system.<sup>1</sup>

In general, mandibular first molars are two rooted with one mesial root and one distal root<sup>1</sup> but there may be some variations in the number, location of roots and root canals. A mandibular molar having an additional third root was first reported by Carabelli, and it was called as Radix Entomolaris (RE)<sup>2</sup>. This additional root is distolingual to the mesial root of the mandibular molars. Similarly, an extra root presented at the mesiobuccal side of the distal root of the mandibular molar is confirmed as Radix Paramolaris (RP).<sup>3</sup>

The etiology associated with RE is still not clear. Different school of thoughts suggest the cause attributed either to disturbance during odontogenesis or due to an atavistic gene. The incidence of RE may vary among different populations and ranges from 5 to 30%.<sup>3</sup>

The RE seems to have prevalence of about 3.4 to 4.2% in European population, less than 5% in Eurasian and Indian population and 5 to 40% Mongoloid population<sup>4,5</sup>. A RE may involve any of the mandibular molar, but the second molar is least commonly involved. Also, there may be 50 to 67% chances of RE occurring bilaterally.<sup>3</sup>

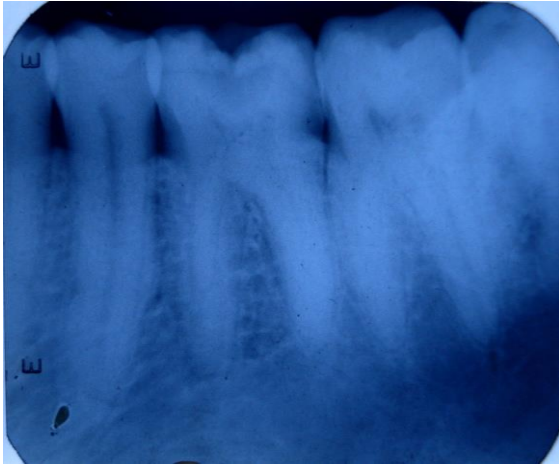
To confirm such varying anatomy within the tooth, several methods has been proposed in endodontics. One of the most significant developments in the past decade has been the use of the operating microscope. The microscope enables the clinician to have some important benefits in the following ways:<sup>6</sup>

1. The operating field can be inspected at high magnification so that small but important anatomical details, e.g. the extra canal, can be identified and managed.
2. Occupational and physical stress is reduced since using the microscope requires an erect posture. More importantly, the clinical environment is less stressful when clinicians can clearly see the operating field.

Therefore, the present article is about the endodontic management of two cases of mandibular first molar with different anatomic variations, one with an extra RE root and an extra distal canal while another with an extra RE root and canal using the magnification aid.

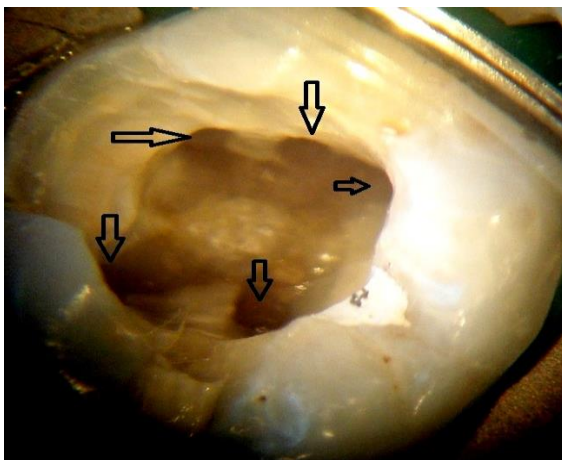
### Case History

**Case Report one:** A 26-year-old male patient reported to the Department Of Conservative dentistry & Endodontics, Dr. R. Ahmed Dental College & Hospital, Kolkata with chief complaint of pain in left lower back tooth since one week. The intensity of pain was moderate but continuous in nature. The patient also reported for sensitivity to both hot and cold. The pain was aggravating on taking hot foods and persisted even after the removal of stimulus. On clinical examination, there was a deep occluso-distal caries in mandibular left first permanent molar i.e. 36. Also, a diagnostic radiograph was taken which suggested deep caries with pulpal involvement along with faint outline of the distal root suggesting overlapping of roots. The condition was diagnosed as acute irreversible pulpitis and the treatment plan consisted of endodontic therapy followed by full coverage restoration and it was explained to the patient prior to initiation of treatment.



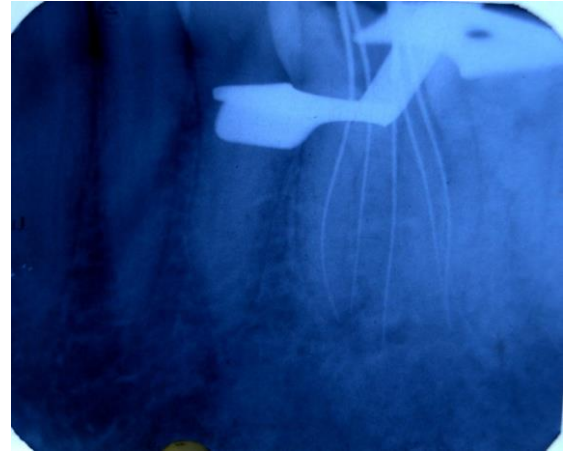
**Fig. 1: Pre-operative IOPA Radiograph Case One**

**Treatment Progress:** Local anesthesia was administered and the tooth was isolated under rubber dam. Under dental operating microscope (DOM), the access preparation was done with an endo-access kit including endo-Z bur (Dentsply). The first distal canal was found slightly away from the midline (buccally), suspecting of presence of another canal on the lingual side from midline. Now, the access cavity preparation was modified from a triangular shape to a trapezoidal form and the fourth canal was located with the help of DG-16 explorer. Beside this, an extra disto-lingual root canal orifice (5<sup>th</sup> canal) was also confirmed under DOM.



**Fig. 2: Microscopic view with arrows representing the presence of five canals in 36**

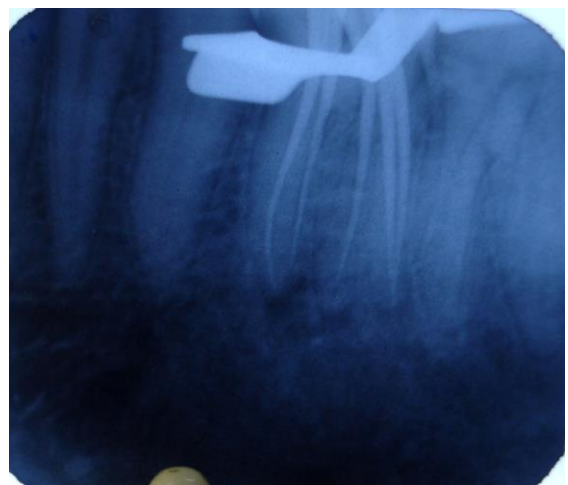
All the root canals were located with DG-16 endodontic explorer and patency of canals was made with #10 K – file (Mani, Japan). Working length was determined radiographically using SLOB (Same Lingual Opposite Buccal) or Tube Shift technique which clearly showed the presence of five separate canals including RE canal.



**Fig. 3: Case One Working Length Determination and Confirmation of Five Separate Canals through IOPA Radiograph**

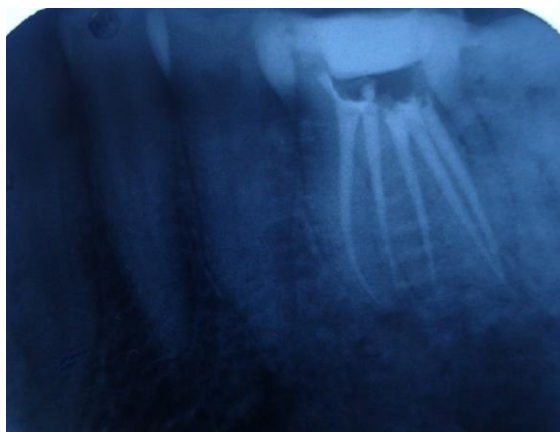Cleaning and shaping was done using ProTaper rotary instruments (Dentsply) upto size #F1 in a crown-down manner using 3% sodium hypochlorite (Parcan, Septodont), 17% EDTA solution and normal saline as irrigants followed by closed dressing of 36.

At the successive visit, the obturating lengths were further confirmed through IOPA radiograph by inserting #F1 gutta percha (G.P.) cones in the canals.



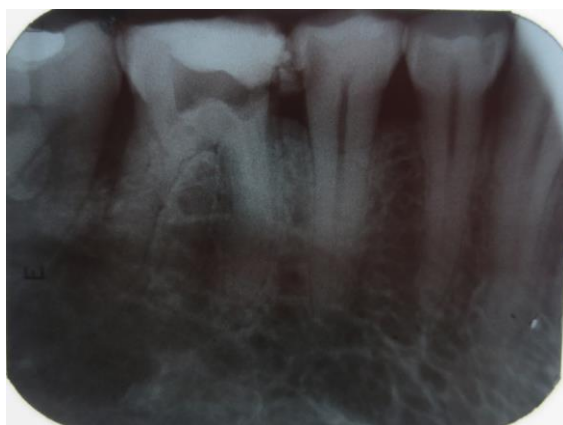**Fig. 4: Pre-obturation Gutta Percha Length Confirmation**

After drying the canal with paper points, the final obturation was performed using single cone #F1 G.P. and calcium hydroxide sealer (Apexit Plus, Ivoclar Vivadent). Access cavity was restored with Coltisol (Coltene Whaledent) and a post-obturation radiograph was taken.



**Fig. 5: Post-obturation IOPA Radiograph Case One**

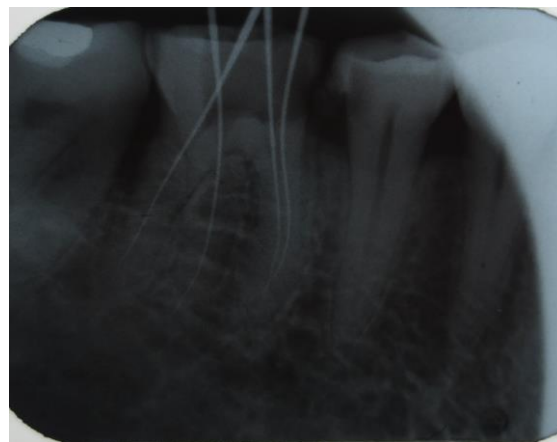
**Case Report two:** A 38-year-old male patient reported to the department with chief complaint of pain in lower right back tooth. Patient gave the history of initiation of endodontic treatment for that tooth by some outside dental practitioner but he was not getting relieved from pain. On clinical examination, the right mandibular first molar i.e. 46 was temporary filled. On IOPA radiograph confirmation, the pulpal chamber of 46 was opened. The IOPA radiograph also revealed a faint outline suspecting the presence of a third root between the mesial and distal roots. There was no any periradicular changes. For this case also, the treatment plan consisted of endodontic therapy followed by full coverage restoration.



**Fig. 6: Pre-operative IOPA Radiograph Case Two**

After giving local anesthesia with 2% lidocaine, temporary restoration was removed from 46. The access cavity was modified in form of trapezoidal and was little extended towards the disto-lingual side in suspicion of having RE root or canal. With the help of DG-16 explorer, all the mesial and distal canals were located and confirmed it under DOM.

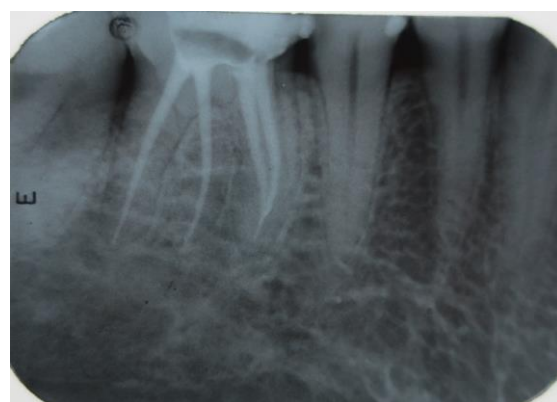The patency of the canals were verified with #10 K file. The canals were confirmed separately and working canal lengths were determined through IOPA radiograph.



**Fig. 7: Case Two Working Length Determination and Confirmation of RE root canal through IOPA Radiograph**

The canals shaping was done with protaper rotary system (Dentsply, Maillefer) till size #F1 using Glyde (Dentsply, Maillefer) as a lubricant and cleaning of the canals was done with 3% sodium hypochlorite and normal saline. Closed dressing was given at that visit.

At the next visit, after confirming the pre-obtured G.P. lengths, the canals were dried with paper points and obturated with single cone of ProTaper G.P. points (#F1) and Apexit Plus sealer (Ivoclar Vivadent). Post-obturation IOPA radiograph has been shown in **Fig. 8**.



**Fig. 8: Post-obturation IOPA radiograph Case Two**

### Discussion

Mandibular molars show variations like, extra root (three rooted mandibular molar), c-shaped canals and presence of extra canals. Hence, understanding these morphological variations plays a key role in the success of endodontic therapy. The radix entomolaris (RE) represents as one of the example of anatomic variation in mandibular molars.

The etiology of RE is not very clear; but often it can be associated to some causes like external factors during odontogenesis or an atavistic gene penetration or polygenic system. Previously, it has also been suggested that a particular gene expression may be

influenced by racial genetic factors which finally, may generate most accentuated phenotypic manifestation.<sup>7</sup>

The RE may involve the first, second and third mandibular molar with least occurrence is in the second molar. Some studies reported a bilateral occurrence of RE of about 50-67%.<sup>8,9</sup>

Various methods have been proposed for the diagnosis of RE. One of them include the clinical examination of the tooth crown and analysis of the cervical anatomy of the roots through:<sup>11,12</sup> Periodontal probing (helping for an additional root identification), various instruments like endodontic explorer, path finder, DG-16 probe and micro-opener (help locating the canal orifices at pulpal chamber floor), champagne bubble effect using sodium hypochlorite in pulp chamber (to locate missed or extra canal orifice). More importantly, an extra cusp (i.e. tuberculum paramolare) or a prominent occlusal distal or distolingual lobe, in association with cervical convexity may give suspicion of having RE root.

Apart from this, some additional methods can also be useful in confirmation of extra roots which may include<sup>10,11</sup>

- Radiographs with different angulations (using tube shift technique)
- Access cavity modification of tooth from triangular to trapezoidal form
- Knowledge of Krasner & Rankow's law of symmetry and law of orifices
- Visualizing the dentinal map and canal, bleeding points within pulp chamber
- Using magnifying loupes
- Use of dental operating microscope (DOM)
- Spiral Computed Tomography
- Cone Beam Computed Tomography (CBCT)

Here in the case, for the diagnosis of RE, IOPA radiographs play an important role which further gets easily confirmed with the use of DOM. It has been proposed that the radiographs were successful in over 90% of the cases while identifying additional roots.<sup>11</sup> A thorough examination and interpretation of the preoperative radiograph showing some special characteristics, such as double periodontal ligament space images or faint outline of the distal root or the root canal, may give a strong suspicion of a 'hidden' RE. A second radiograph should be taken from 30° mesial or 30° distal angulations to confirm the suspicious root.<sup>12,13</sup>

Clinically, the RE canal orifice can be precisely located by exploring dark developmental line or dentinal map on the pulp chamber floor using endodontic probe. Also, DOM through its enhanced magnifications, can be very useful especially in cases where the orifices are covered by a calcification that can be easily removed with ultrasonic tips or long shank round burs.

The orifice of the RE is located disto- mesiolingually from the main canal or canals in the

distal root, hence, the access cavity here was modified to trapezoidal form by extending the preparation to distolingual side. Using the crown down technique, the initial preparations of canals were done by enlarging canal orifices and thereby, removing coronal interferences in order to get a straight-line access. Also, in the cases, flexible Ni-Ti files like ProTaper rotary file system along with lubricant were used to prevent shaping aberrations, such as straightening of the root canal, ledge formation and canal transportation after creating a glide path within the canals.

Therefore, after the canal location, orifice enlargement and working length determination, such flexible Ni-Ti rotary files allows a more centered preparation of canal and also, provide a better irrigation flow within the prepared canal.

### Conclusion

It has always been a challenge for dentist to overcome the anatomical variations of teeth. The clinician's mind should have accurate knowledge of normal anatomy and its variations so that it could lead to the endodontic success. Radix entomolaris, though not a common entity, once diagnosed, can be managed using equipment's such as magnification aids and flexible Ni-Ti files following proper endodontic protocol.

### References

1. Vertucci FJ. Root canal anatomy of the human permanent teeth. *Oral Surg, Oral Med, Oral Pathol* 1984;58(5):589-99.
2. Calberson FL, De Moor RJ, Deroose CA. The radix entomolaris and paramolaris: clinical approach in endodontics. *J Endod* 2007;33(1):58-63.
3. De Moor R, Deroose C, Calberson F. The radix entomolaris in mandibular first molars: an endodontic challenge. *Intern Endod J* 2004;37(11):789-99.
4. Ravanshad S, Nabavizade MR. Endodontic treatment of a mandibular second molar with two mesial roots, report of a case. *Intern Endod J* 2008;3(4):137-140.
5. Egea S, Jose V, Santos R. Endodontic therapy in a 3-rooted mandibular first molar, importance of a through radiographic examination. *JCDA* 2002;68(9):541-544.
6. Kim S, Kratchman S. *Modern Endodontic Surgery Concepts and Practice: A Review.* *J Endod* 2006;32(7):601-23.
7. Reichart PA, Metah D. Three-rooted permanent mandibular first molars in the Thai. *Commun Dent Oral Epidemiol* 1981;9:191-2.
8. Eelman R. Incidence of an accessory distal root on mandibular first permanent molars in Hispanic children. *J Dent Child* 1986;53:122-3.
9. Yew SC, Chan K. A retrospective study of endodontically treated mandibular first molars in a Chinese population. *J Endod* 1993;19:471-3.
10. Shailendra G, Deepak R, Rishidev Y. The Radix Entomolaris and Paramolaris: A Case Report. *J Int Oral Health* 2011; Early online:01-07.
11. Hegde V, Kashid V. Radix entomolaris-series of case reports. *Intern J Advan Case Rep* 2015;2(4):216-220.

12. Irodi S, Farook AZ. Three Rooted Mandibular Molar; Radix Entomolaris and Paramolaris. Intern J Dent Clin 2011;3(1):102-104.
13. Chen YC, Lee YY, Pai SF, Yang SF. The morphologic characteristics of distolingual roots of mandibular first molars in Taiwanese population. J Endod 2009;35:643-5.