

## Delayed replantation and endodontic management of traumatically avulsed permanent central incisors with mature apex

Akash Kumar Baranwal

Service Senior Resident, Faculty of Dental Sciences (FDS), IMS, BHU, Varanasi

Email: baranwalakash@yahoo.com

---

### Abstract

Tooth avulsion is referred as complete displacement of tooth from the alveolar socket. It may involve both primary and permanent tooth as well. The management and outcome of such avulsion depends on speedy location of avulsed tooth and immediate replantation within the socket as the chances of periodontal ligament (PDL) cells survival decreases with increase in extra-oral dry time. The delayed replantation of tooth avulsion can also be managed following the proper guidelines and protocol. Therefore, the present article is about to discuss the replantation and management of the avulsed permanent maxillary central incisors of a patient with mature apex and an extra-oral dry time of more than 60 minutes.

**Key Words:** Avulsion, Replantation, PDL cells, Extra-oral dry time, Storage media

---

### Introduction

Traumatic injuries are being seen commonly these days and compared to this, the trauma affecting the dental structures are occurring at higher incidence. The avulsion of tooth although not a common occurrence but can be seen in 0.5–3% of all dental injuries. Tooth avulsion is defined as complete displacement of a tooth from its socket<sup>(1,2, 3)</sup>. The prevalence of tooth avulsion has been seen increasing between 7 to 9 years of age and the cause has been attributed to the incomplete root formation and minimal ability of the alveolar bone/periodontal ligament (PDL) to resist against extrusive forces during teeth eruption.<sup>(1,3)</sup>

The incidences of avulsion have been reported to be 1% to 16% in permanent teeth and 7% to 13% in primary teeth. The maxillary incisors are more frequently involved than the mandibular teeth.<sup>(4,5,6)</sup>

The viability of PDL cells plays a major role in determining the prognosis for avulsions. The outcomes may have better results if the PDL cells are preserved<sup>(7,8,9)</sup>. It has been reported that in case of avulsed tooth outside the alveolar socket, PDL cells on the root surface will survive and be viable if they are kept hydrated<sup>(5,10)</sup>. Such vital PDL cells have ability to reattach and to maintain its viability when avulsed tooth is replanted within the first 15-20 minutes after the occurrence.<sup>(11)</sup>

Outside oral environment to keep the cells hydrated and alive, readily available storage media for an avulsed tooth, in order of preference, are milk, saliva and saline but tissue transport medium, such as Hank's Balance Salt Solution (HBSS) contains excellent ability and has been reported as superior storage media.<sup>(12,13,14)</sup>. Water as storage medium cannot be recommended as the hypotonic conditions destroy the PDL cells.<sup>(15)</sup>

A relatively high success rate has been reported when the tooth is replanted immediately. Hence, the technique for replantation supports the immediate management of avulsed tooth with its quick location

and replantation at the site of injury itself if possible before reporting to any dentist. Here, the speed with which the avulsed tooth is replanted, can be the best criteria for success.<sup>(8,9)</sup>

As consequences of an avulsed tooth, attachment damage and pulp necrosis may occur. The tearing of PDL is the main cause for tooth separation from the alveolar socket but most of the root surface retains viable PDL cells. Also, the crushing/scraping of the tooth against the socket may result in small-localized cemental destruction<sup>(16)</sup>. The consequences are supposed to be very minimal, if, the periodontal ligament containing root surface does not dry out. Such hydrated PDL cells will result in very less or minimal destructive inflammatory changes after replantation.<sup>(5,10)</sup>

On contrary to this, the PDL cells left out dried for a longer duration can provoke an inflammatory response involving most of the root surface. It has been seen that the slower moving cementoblasts are not able to heal such diffuse root surface area in time resulting in direct bony attachment onto the root surface. As the time elapses, complete osseous replacement or replacement resorption may occur through physiologic bone remodeling.<sup>(17,18)</sup>

The necrotic pulp occurring as result of avulsion injury, although having minimal or no consequences, may harbor bacterial contamination. In the absence of revascularization or effective endodontic treatment, there is highly suspicion for pulp being infected. This infected pulp along with external root cemental destruction may result in an aggressive external inflammatory resorption. Also, the resorption will remain active as long as the microbes are harbored in the root canal leading to the rapid tooth loss<sup>(19)</sup>. But, if such cases are managed properly, the replanted avulsed teeth will remain functional for the years.<sup>(20)</sup>

Therefore, the present article is about to discuss the replantation and management of the avulsed permanent

maxillary central incisors of a patient with mature apex and an extra-oral dry time of more than 60 minutes.

### Case Report

A 26 year old female patient reported to the department of conservative dentistry & endodontics with avulsed maxillary central incisors after one hour of injury. The teeth were brought dipped in water (Fig. 1). On examination, the patient did not show any signs or symptoms of neurological injury. The extra-oral examination revealed slight swelling and lacerations on upper lip. The intraoral examination revealed empty alveolar sockets of maxillary central incisors i.e.<sup>(11,21)</sup> suggesting teeth avulsion (Fig. 2). The IOPA radiograph of concerned region confirmed the empty alveolar sockets of<sup>(11,21)</sup> without any other sign of adjacent tooth or bone fracture. This also revealed the presence of normal radiopaque lamina propria surrounding the alveolar sockets (Fig. 3). In a vitality test, the adjacent teeth gave positive responses.

Examination of the avulsed teeth revealed that the crown and root portions of<sup>(11,21)</sup> were intact. Patient and her relatives were very anxious and disturbed due to loss of front teeth. But they felt relaxed after assuring them that the teeth could be saved. The available treatment options were explained to the patient and her relatives and it was decided to replant the avulsed incisors as an immediate treatment. Also, they were informed about the possible outcome or risks of the treatment.

### Treatment Procedures

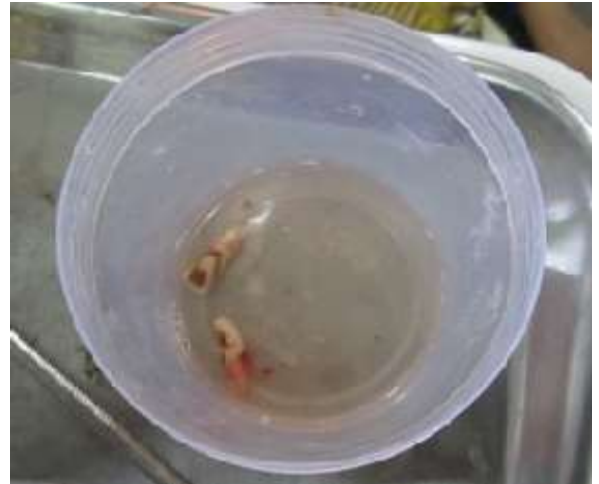The alveolar sockets of the teeth were prepared by gently rinsing with saline solution after giving local anesthesia. The avulsed teeth were rinsed with distilled water to remove any contamination. Remaining periodontal ligaments (PDL) present over root surfaces were removed with a scaler followed by root conditioning with citric acid. Now, the teeth were soaked in a 2% sodium fluoride (NaF) solution for 20 minutes and after that, treated with doxycycline solution for 5 minutes. Finally, the root surfaces were rinsed with saline and replanted within sockets with slight finger pressure maintaining their original position. (Fig. 4)

The teeth were then stabilized using a semi-rigid fiber splint and the acid-etch composite resin technique (Fig. 5). After completing the procedure, the IOPA radiograph was obtained (Fig. 6). Post-operatively, oral hygiene instructions and advice about a soft diet and the need to use chlorhexidine mouth rinse during the stabilization period were given. Prophylactic antibiotic therapy was prescribed for one week. The patient was also referred for an anti-tetanus booster.

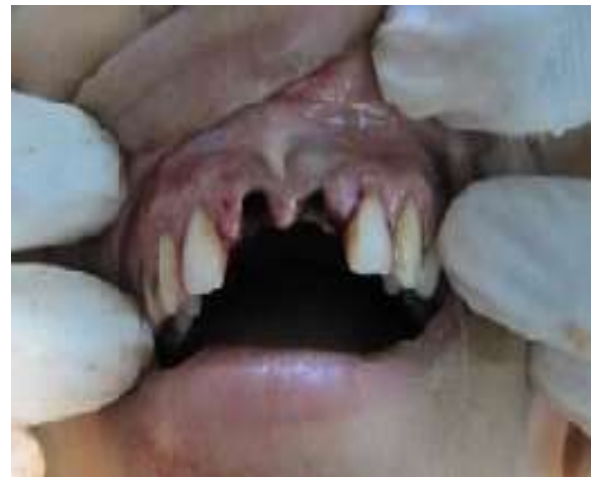Root canal treatment of<sup>(11,21)</sup> was initiated intra-orally at the next visit after 10 days but before removing the splint. After access cavity, working length determination (Fig. 7). and chemo-mechanical

preparation of<sup>(11,21)</sup> with K-files following proper protocol, intermittent intra-canal calcium hydroxide dressing was given for 2 weeks. At subsequent visit, the obturation was completed using zinc oxide eugenol sealer and gutta percha (G.P.) (Fig. 8). The post-endodontic intra-oral photograph of the patient has been shown in (Fig. 9).

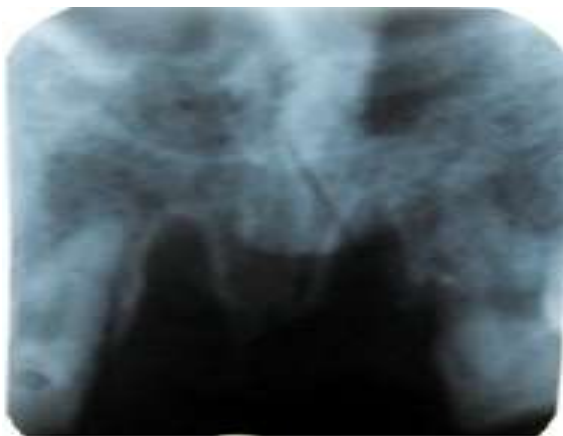The patient was informed about the importance of regularly returning for clinical and radiographic follow-ups at interval of one month, 3 months, 6 months and one year.



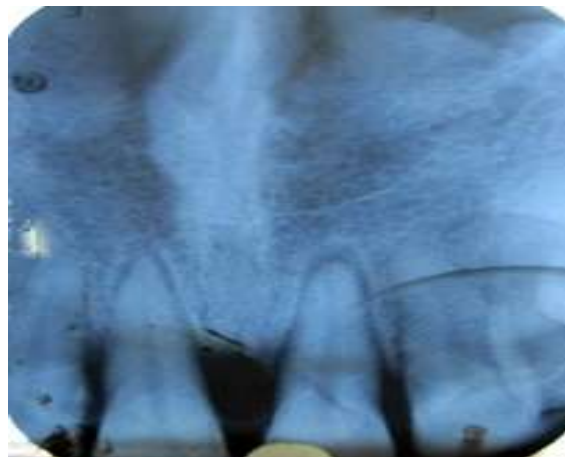
**Fig. 1: Avulsed teeth brought stored in water**



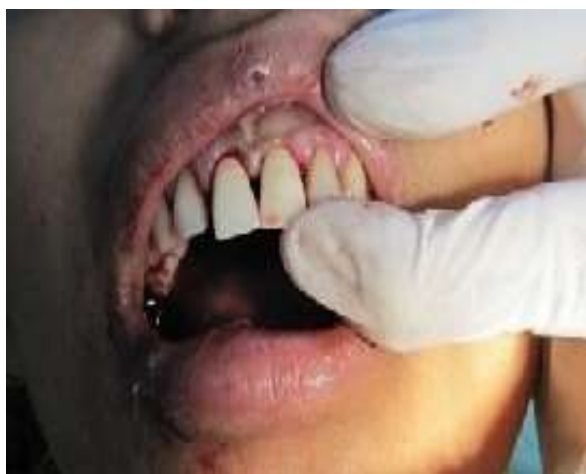**Fig. 2: Pre-operative Intra oral photograph**



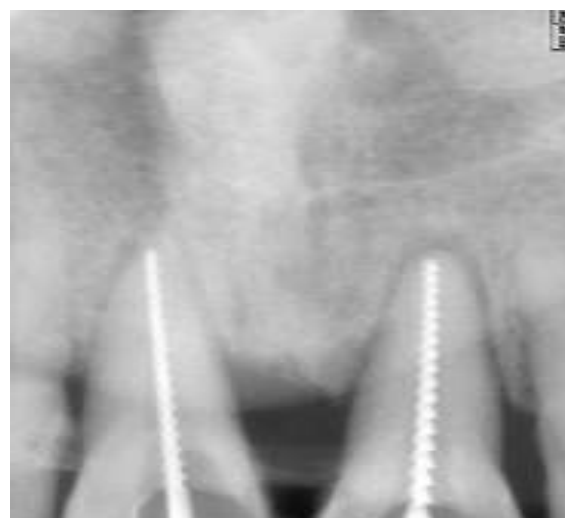**Fig. 3: Pre-operative IOPA Radiograph**



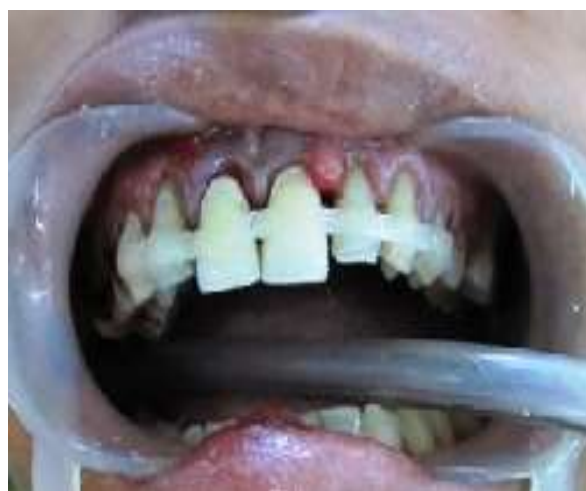**Fig. 6: IOPA Radiograph after replantation**



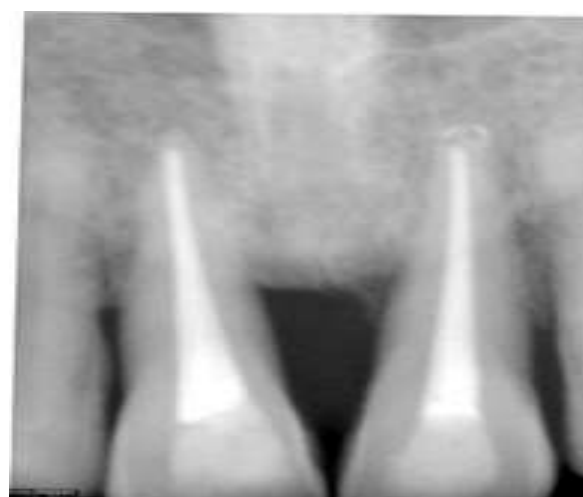**Fig. 4: Teeth replanted within socket**



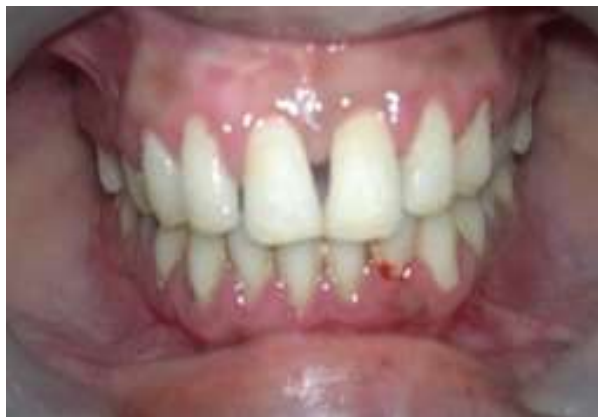**Fig. 7: Working length determination**



**Fig. 5: Replanted teeth stabilized with Fiber splinting**



**Fig. 8: Post-obturation IOPA Radiograph**



**Fig. 9: Post endodontic intra oral photograph**

### Discussion

The management of avulsed permanent teeth follows various guidelines depending upon some factors, but the ideal treatment for an avulsed tooth sticks to its speedy and immediate replantation<sup>(3,21)</sup>. However, it is not always possible to perform it immediately. The treatment choice for avulsed teeth depends on the factors like the maturity of the root apex (open or closed) and the condition of the PDL cells. Whereas, the PDL cells viability depends on the storage medium and the time the tooth being outside the oral cavity<sup>(4,22,25)</sup>. This extra-oral time plays a significant role for outcome and has a direct effect on the PDL cells viability. It has been shown through clinical studies that the speedy replantation of teeth within 5 minutes after avulsion can provide the best prognosis.<sup>(26)</sup>

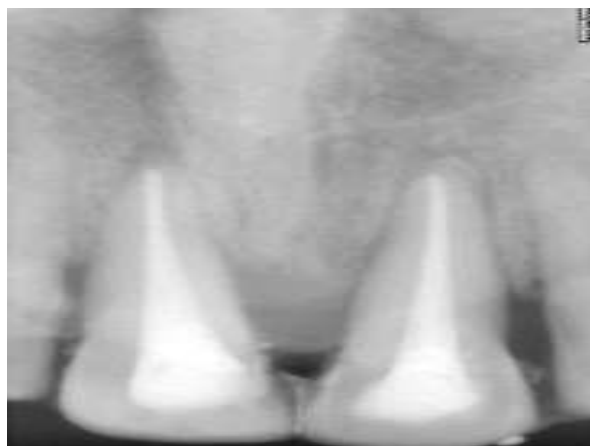
Whereas, an extra-oral dry time of 60 minutes or more after avulsion, all PDL cells do not survive and become nonviable<sup>(3,21)</sup>. But the suitable storage and transport media used during this extra-oral time may have vital significant role in order to keep PDL cells hydrated and viable. Hence, the patients should be aware to maintain the avulsed tooth with a prolonged extra-oral time, in a suitable media such as HBSS, saline, milk, or saliva until it is replanted back into the alveolar socket by a dentist.<sup>(27,28)</sup>

In the present cases while reporting to the department, the teeth were brought dipped into the normal tap water and with the extra-oral time of more than 60 minutes. But the water as storage medium could not be acceptable as the hypotonic conditions might have destroyed the PDL cells<sup>(15)</sup>. Hence, the condition of PDL cells was considered non-viable. The management of this case was then followed in accordance with the accepted replantation protocol described by the International Association of Dental Traumatology.<sup>(3)</sup>

For such cases, it has been indicated that, if the tooth has been dry for more than 60 min before replantation, the endodontic treatment (RCT) may be performed either extra-orally prior to replantation or

few days later after replantation. In the absence of revascularization or effective endodontic treatment, it is highly suspected for pulp being infected. Because of mature apex denying any possibility of pulp space revascularization and the presence of non-viable PDL cells, it was not expected to heal and it was decided to opt for root canal treatment of the replanted avulsed teeth. Therefore, RCT was started ten days after the replantation but before removing the semi-rigid splint in order to avoid any unwanted destabilization of teeth during access cavity preparation. The endodontic treatment was completed after that following proper protocols and the patients was instructed for regular follow-ups.

The subsequent follow-up visits confirmed the asymptomatic and stabilized nature of the teeth. There was no sign of pain, mobility found within six months. At the six months follow-up visit, a percussion test of the replanted teeth revealed a change in the percussion sound due to ankylosis which was also confirmed via obtaining the IOPA radiograph (Fig. 10). The patient is still under observation for further evaluation.



**Fig. 10: Six months follow-up IOPA Radiograph**

### Conclusion

The success of avulsed tooth replantation is directly attributed to the extra-oral time and storage or transport media of the tooth. Despite an extended extra-alveolar dry storage time, teeth with delayed replantation may regain a stable and functional position in the dental arch, if; they are managed following proper guidelines & protocols. Follow-up appointments are crucial in order to obtain & confirm the successful management of teeth avulsion.

### References

1. Andreasen JO, Andreasen FM. "Classification, etiology and epidemiology," in Textbook and Color Atlas of Traumatic Injuries to the Teeth, Andreasen JO, Andreasen FM. Eds., pp.151–179, Mosby, Munksgard, Copenhagen, Denmark, 1994.
2. Andreasen JO, Andreasen FM. "Examination and diagnosis of dental injuries," in Textbook and Color Atlas of Traumatic Injuries to the Teeth, Andreasen JO,

- Andreasen FM. Eds., pp. 195–217, Mosby, Copenhagen, Denmark, 1994.
3. Andersson L, Andreasen JO, Dayetal P. International Association of Dental Traumatology guidelines for the management of traumatic dental injuries: 2. Avulsion of permanent teeth. *Dent Traumatol* 2012;28(2):88–96.
  4. Andreasen FM, Andreasen JO. Textbook and color atlas of traumatic injuries to the teeth. 3<sup>rd</sup> ed. St Louis: Mosby, Inc. 1994;383-425.
  5. Andreasen JO. Effect of extra-alveolar period and storage media upon periodontal and pulpal healing after replantation of mature permanent incisors in monkeys *Int J Oral Surg* 1981;10(1):43-53.
  6. Cvek M, Granath LE, Hollender L. Treatment of non-vital permanent incisors with calcium hydroxide. III. Variation of occurrence of ankylosis of reimplanted teeth with duration of extra- alveolar period and storage environment. *Odontol Revy* 1974;25(1):43-56.
  7. American Association of Endodontists. Recommended guidelines of the American Association of Endodontists for the treatment of traumatic dental injuries. Chicago; 2003.
  8. Trope M. Clinical management of the avulsed tooth: present strategies and future directions. *Dent Traumatol*. 2002;18(1):1-11.
  9. Diangelis AJ, Bakland LK. Traumatic Dental Injuries: current treatment concepts. *J Am Dent Assoc*. 1998;129(10):1401-14.
  10. Soder PO, Otteskog P, Andreasen JO, Modeer T. Effect of drying on viability of periodontal membrane. *Scand J Dent Res*. 1977;85(3):164-8.
  11. Barrett EJ, Kenny DJ. Avulsed permanent teeth: a review of the literature and treatment guidelines. *Endod Dent Traumatol* 1997;13(4):153-63.
  12. Hiltz H, Trope M. Vitality of human lip fibroblasts in milk, Hank's balanced salt solution and Viaspan storage media. *Endod Dent Traumatol* 1991;7(2):69-72.
  13. Trope M, Friedman S. Periodontal healing of replanted dog teeth stored in Viaspan, milk and Hank's balanced salt solution. *Endod Dent Traumatol* 1992;8(5):183-8.
  14. Blomlof L. Milk and saliva as possible storage media for traumatically exarticulated teeth prior to replantation. *Swed Dent J Suppl* 1981; suppl 8:1-26.
  15. Muhamad AH, Nezar W, Azzaldeen A. Replantation of Avulsed Permanent Anterior Teeth: A Case Report. *Res Reviews: J Dent Sci* 2014;2(4):43-52.
  16. Trope M. Avulsion of permanent teeth: theory to practice. *Dent Traumatol* 2011;27(4):281-94.
  17. Andreasen JO, Hjorting-Hansen E. Replantation of teeth. I. Radiographic and clinical study of 110 human teeth replanted after accidental loss. *Acta Odontol Scand* 1966;24(3):263–86.
  18. Trope M. Root resorption of dental and traumatic origin. Classification based on etiology. *J Pract Periodont Aesthet Dent* 1998;10(4):515–22.
  19. Tronstad L. Root resorption etiology, terminology and clinical manifestations. *Endod Dent Traumatol* 1988;4(6):241-52.
  20. Rokaya D, Sundar S, Upadhyay S. Emergency Management of an Avulsed Tooth. *Intern Dent J Stud Res* 2013;1(4):31-35.
  21. Kaba AD, Marechaux SC. A fourteen-year follow-up study of traumatic injuries to the permanent dentition. *J Dent Childr* 1989;56(6):417–425.
  22. Cohenca N, Karni S, Eidlitz D, Nuni E, Moshonov J. New treatment protocols for avulsed teeth. *Refuat Hapeh Vehashinayim* 2004;21(2):48–53.
  23. Ramand D, Cohenca ON. Therapeutic protocols for avulsed permanent teeth: review and clinical update. *Pediat Dent* 2004;26(3):251–255.
  24. Cvek M, Cleaton-Jones P, Austin J, Lownie J, Kling M, Fatti P. Effect of topical application of doxycycline on pulp revascularization and periodontal healing in reimplanted monkey incisors. *Endod Dent Traumatol* 1990;6(4):170–176.
  25. Andreasen JO, Borum MK, Andreasen FM. Replantation of 400 avulsed permanent incisors. 3. Factors related to root growth. *Endod Dent Traumatol* 1995;11(2):69–75.
  26. Andersson L, Bodin I. Avulsed human teeth replanted within 15 minutes—a long-term clinical follow-up study. *Dent Traumatol* 1990;6(1):37–42.
  27. Barretand EJ, Kenny DJ. Avulsed permanent teeth: a review of the literature and treatment guidelines. *Endod Dent Traumatol* 1997;13(4):153–163.
  28. Pohl Y, Filippi A, Kirschner H. Results after replantation of avulsed permanent teeth. II. Periodontal healing and the role of physiologic storage and antiresorptive-regenerative therapy. *Dent Traumatol* 2005;21(2):93–101.