

Content available at: <https://www.ipinnovative.com/open-access-journals>

IP Annals of Prosthodontics and Restorative Dentistry

Journal homepage: <https://www.aprd.in/>

## Case Report

# Restoring facial harmony: Prosthetic rehabilitation of an orbital defect secondary to post-COVID mucormycosis - A case report

Harmandeep Dhaliwal<sup>1\*</sup>, Jyoti Tembhurne<sup>1</sup>, Arti Gangurde<sup>1</sup>, Niraja Jaiswal<sup>1</sup>, Pradnya Salian<sup>1</sup>

<sup>1</sup>Dept. of Prosthodontics and Crown and Bridge, Government Dental College and Hospital, Mumbai, Maharashtra, India



### ARTICLE INFO

#### Article history:

Received 05-04-2024

Accepted 03-05-2024

Available online 15-05-2024

#### Keywords:

Orbital prosthesis

Orbital defect

maxillofacial prosthesis

Eye Prosthesis

### ABSTRACT

Orbital prostheses serve as a hope in restoring facial aesthetics for individuals who have undergone orbital exenteration due to various pathologies, trauma, or congenital anomalies. The outbreak of COVID-19 brought forth numerous challenges, including the emergence of secondary complications such as mucormycosis, a rare but severe fungal infection. Through a meticulous fabrication process, prosthesis is tailored to the unique anatomical and aesthetic needs of each patient. This case report underscores the pivotal role of prosthetic rehabilitation in addressing the sequelae of post-COVID mucormycosis leading to an orbital defect and fabrication of silicone orbital prosthesis with its transformative impact on patient's confidence.

This is an Open Access (OA) journal, and articles are distributed under the terms of the [Creative Commons Attribution-NonCommercial-ShareAlike 4.0 License](https://creativecommons.org/licenses/by-nc-sa/4.0/), which allows others to remix, tweak, and build upon the work non-commercially, as long as appropriate credit is given and the new creations are licensed under the identical terms.

For reprints contact: [reprint@ipinnovative.com](mailto:reprint@ipinnovative.com)

## 1. Introduction

Loss of an eye is one of the most tragic of all sensory organ losses. It significantly impacts one's self esteem and overall wellbeing of an individual. An eye defect can result due to underlying pathology, trauma, congenital defects or tumors. An Eye Prosthesis can be classified into ocular prosthesis and orbital prosthesis. An ocular prosthesis involves artificial replacement of eye without replacing any adjacent structures whereas orbital prosthesis involves replacement of eye along with the adjacent structures.<sup>1,2</sup>

The COVID-19 pandemic did not only bring about significant challenges in managing viral infections but also led to the emergence of various secondary complications, including opportunistic fungal infections such as mucormycosis. The development of orbital defects in the setting of COVID-induced mucormycosis represents a complex interplay between viral infection,

immune dysregulation, and fungal invasion of the orbital tissues. These factors create a conducive environment for the proliferation of opportunistic fungal pathogens. Management of COVID-induced mucormycosis orbital defects requires a multifaceted approach involving antifungal therapy, aggressive surgical debridement, and adjunctive measures to address underlying predisposing factors such as diabetes mellitus and immunosuppression.<sup>3,4</sup>

This case report highlights the conventional approach customized according to the patient to give 'life like appearance' to the prosthesis and describes the steps in fabrication of an adhesive retained silicone orbital prosthesis. Prosthetic Rehabilitation of such patients help in restoring esthetics and psychosocial well-being.

## 2. Case Presentation

A 60-year-old male patient reported to the Department of Prosthodontics with chief complaint of unesthetic appearance due to missing left eye. Patient had diabetes

\* Corresponding author.

E-mail address: [hdchahat1308@gmail.com](mailto:hdchahat1308@gmail.com) (H. Dhaliwal).

mellitus and high blood pressure and was under medication for the same since 5 years. Patient was apparently alright 2 years back when he got diagnosed with covid and underwent treatment for the same. Six months later he developed rhino-orbital mucormycosis in the left eye and was operated surgically for the same 1 year back. Exenteration of the left orbit was done and reconstruction surgery was done to close the defect. Patient also gives history of stroke 6 months back which caused facial paralysis on the left side of his face. Thus, the patient was suffering from severe emotional and psychological trauma due to disarranged facial esthetics.

On extra oral examination, patient had facial asymmetry on the left side of face with missing left eye (Figures 1, 2 and 3). Drooping of the left corner of mouth and loss of facial expressions was noted. The orbital defect was 4.5 cm mediolaterally 5 cm superioinferiorly. The margins of the orbital defect were well healed with no signs of inflammation or discharge. It was a closed defect with no sinus tract or intraoral communication. Clinical diagnosis was exenterated orbital defect secondary to post covid mucormycosis. Patient was explained about various treatment options like adhesive retained silicone orbital prosthesis, spectacle retained orbital prosthesis, attachment retained orbital prosthesis and implant retained orbital prosthesis. Adhesive retained silicone orbital prosthesis was planned due to presence of other co-morbidities. Written consent of the patient was taken before beginning with the treatment.

### 2.1. Procedure

Impression of the orbital defect was made with irreversible hydrocolloid impression material (Dentsply vignette chromatic alginate). A layer of wet gauze was placed on the material as it was setting (Figure 4). Fast setting dental plaster was mixed and placed over the gauze to reinforce the impression material acting as mechanical retention for ease of retrieval of impression. Type III dental stone (Kalstone; Kalabhai Karson, India) was used to pour the impression and obtain Facial moulage (Figure 5). Custom tray was fabricated using cold cure acrylic over defect area after applying spacer wax.

Marking of vertical facial lines which include facial midline, medial canthus, lateral canthus, centre of right pupil, and a horizontal line from medial to lateral canthi was made on the right side (Figure 6). These markings were transferred on the defect side using vernier caliper. Medium body impression material was used to make final impression using custom tray. Working cast was obtained using Type IV dental stone (Kalrock Die stone, Kalabhai Karson, India)(Figure 7). Selection of stock iris shell was made by matching size, shape and shade from right iris. Peripheries of eye shell were trimmed and customization of scleral shade was done using tooth colored acrylic followed by staining of sclera for characterization.

The iris was positioned according to the reference lines and transferred on the working cast (Figure 8). A layer of Vaseline was applied on the cast for easy retrieval. Wax up and carving of the peri-orbital structures was done (Figure 9). Wax pattern trial was done. The position of iris and associated contours were verified using digital photography and customized digital grid at normal conversational gaze. Patient's approval was taken (Figure 10).

### 2.2. Processing

Plastic nozzle was attached to the iris using clear acrylic to stabilize the eye shell during processing. Flasking was done followed by dewaxing which created mold space (Figures 11 and 12). Basic Shade selection of the silicone was done by mixing various intrinsic stains (Factor II, Technovent) and matched with the patient's face using trial and error. After a satisfactory shade was obtained, heat temperature vulcanized silicone (M-511, maxillofacial silicone, Technovent South Wales, UK) with Part A: Part B was mixed in ratio of 10:1 and packed into mold space. Curing was done at 100 degrees celsius for 1 hour according to manufacturer's instructions. After curing, silicone trial was done to verify fit, retention and esthetics. Extrinsic staining was done with extrinsic stains (Factor II, Technovent) for characterization. Incorporation of eye lashes was done by stitching to eye lids (Figure 13).

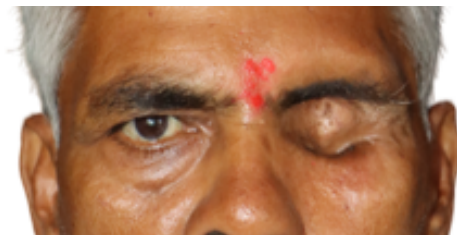

Figure 1: Extraoral frontal view

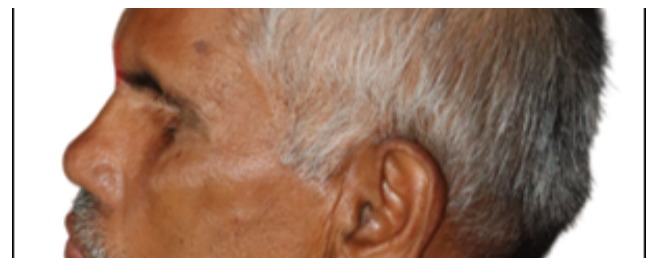
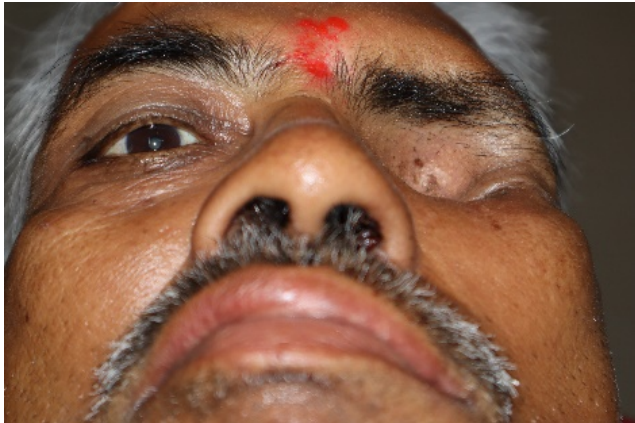
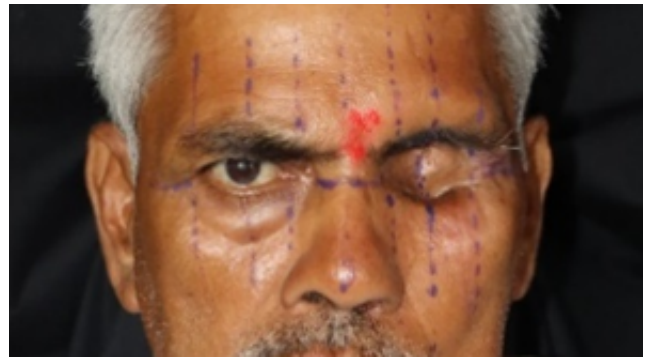Figure 2: Extraoral left lateral view

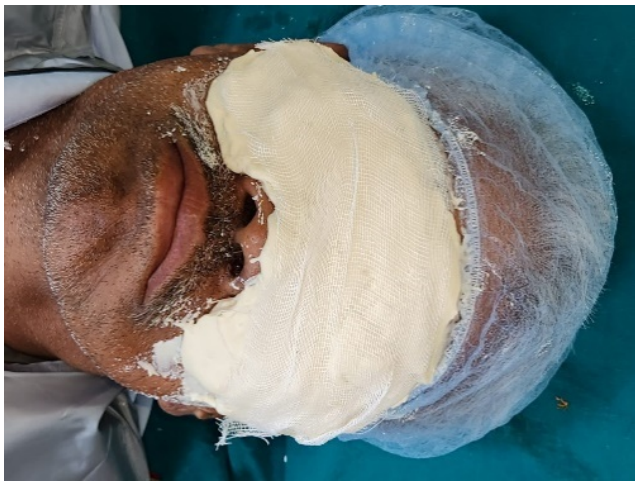Final prosthesis was checked in patient for retention and esthetics (Figures 14 and 15). Water based adhesive (Technovent, Ltd, South Wales, UK) was used to retain the prosthesis. Patient was taught about the insertion & removal



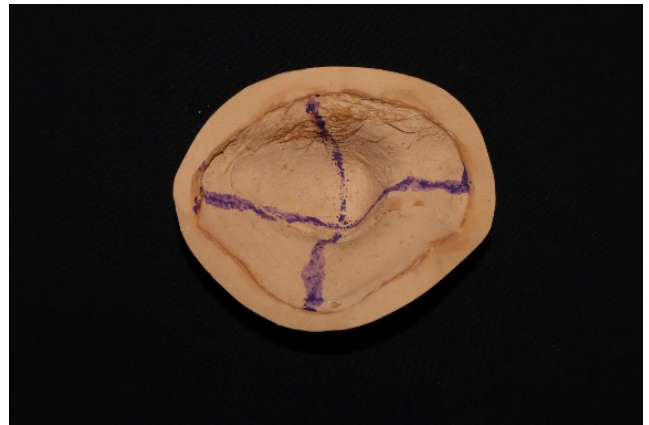**Figure 3:** Extraoral 12'o clock view



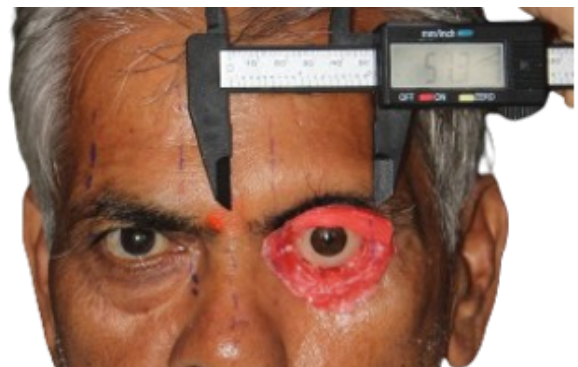**Figure 6:** Marking of reference lines




**Figure 4:** Impression made using alginate



**Figure 7:** Working wax



**Figure 8:** Positioning of iris

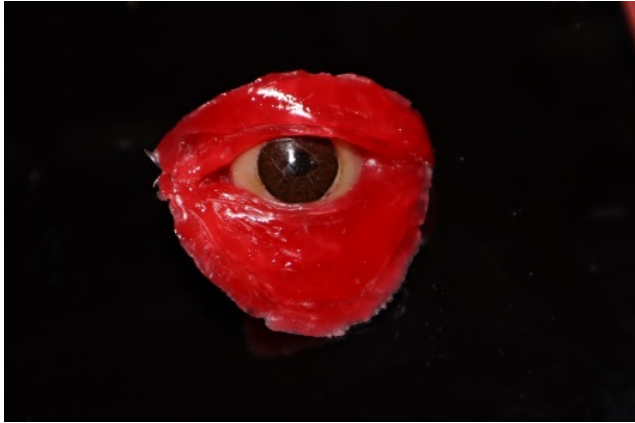


**Figure 5:** Facial moulage

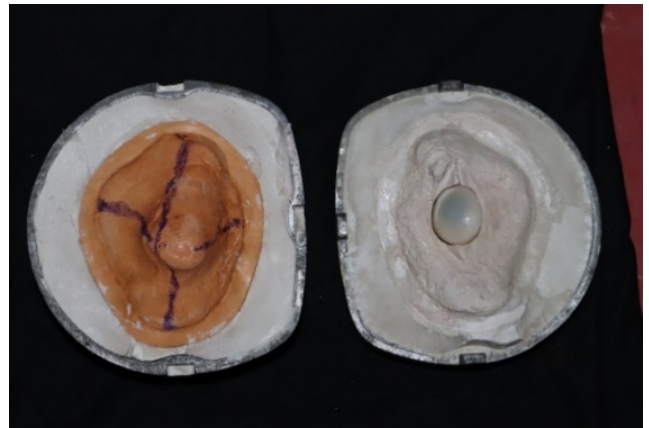
of prosthesis. Home care instructions were given. Regular follow up was done. Patient was satisfied with the outcome.

### 3. Discussion

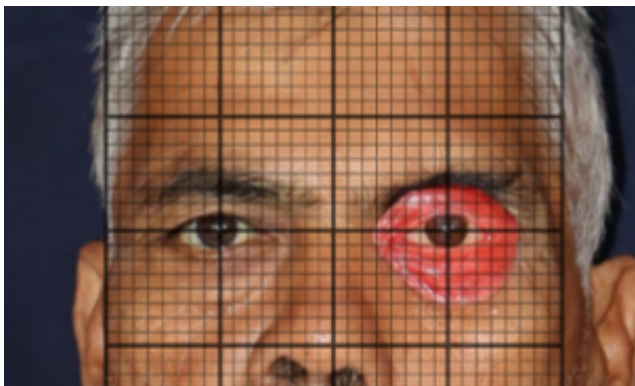
Prosthetic rehabilitation after orbital exenteration poses a great challenge due to complex anatomy of the orbital region and at the same time meeting the patient expectations. In cases of post-COVID mucormycosis, the extent of tissue destruction and surgical intervention further



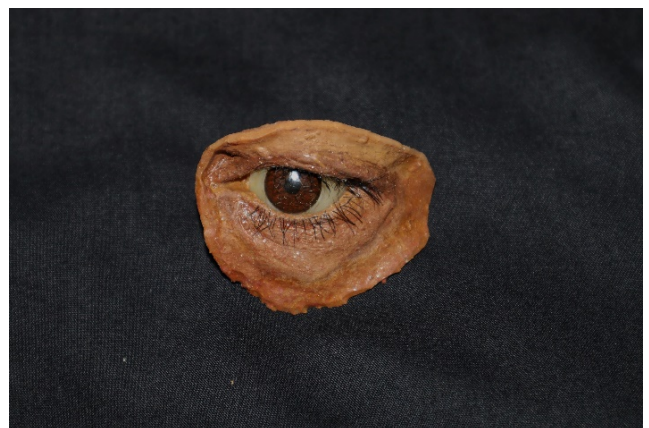**Figure 9:** Wax pattern



**Figure 12:** Pickup of eye shell on counter flask



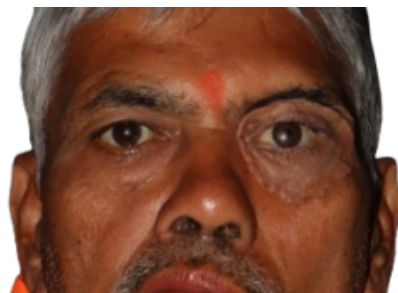**Figure 10:** Wax pattern try in and digital verification



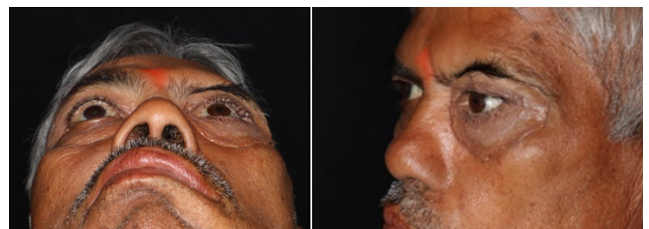**Figure 13:** Characterized orbital prosthesis



**Figure 11:** Attachment of plastic nozzle of gas can



**Figure 14:** Post operative Frontal View



**Figure 15:** Post operative 12 o'clock view and left lateral view

complicates the rehabilitation process. However, with the correct technique and choice of materials life like prosthesis can be mimicked.

In this case, conventional approach combined with digital photography was used to aid in fabrication of prosthesis. Positioning of iris can be done in various ways. Use of electronic vernier caliper as advocated by Lanzara et al. in 2019 to position the iris. Verification by superimposing grids on a good digital photograph was used to verify its positioning during try in of wax pattern.<sup>5</sup> Various materials can be used for fabrication of maxillofacial prosthesis including acrylic resins based on polymethyl methacrylate (PMMA), polyurethanes, latex, and silicone polymers. The material of choice for fabrication of prostheses in this case was medical grade HTV silicone due to superior mechanical properties such as high tear strength, better colour stability and low toxicity.<sup>6–9</sup> Due to absence of favorable undercuts for self-retention of prosthesis, water-based silicone adhesive was used for additional retention.<sup>10–12</sup>

#### 4. Conclusion

The journey of rehabilitating a patient with an orbital defect post-COVID mucormycosis underscores the vital role of prosthodontists in restoring not only physical form but also dignity and confidence. Through meticulous planning, innovative techniques backed by scientific principles and compassionate care, patient developed a renewed sense of normalcy. Confronting the aftermath of COVID-19 and its associated complications, the interdisciplinary collaboration between medical professionals becomes increasingly essential. Use of less invasive techniques in rehabilitation of maxillofacial defects along with post operative care and follow up needs to be emphasised.

#### 5. Conflict of Interest

None.

#### 6. Source of Funding


None.

#### References

1. Vincent A, Kohlert S, Kadakia S, Sawhney R, Ducic Y. Prosthetic reconstruction of orbital defects. *Semin Plast Surg.* 2019;33(2):132–

- 7.
2. Beumer J, Curtis TA, Marunick MT. Maxillofacial rehabilitation Prosthodontic and surgical considerations. MDMI, Inc; 1996.
3. Singh AK, Singh R, Joshi SR, Misra A. Mucormycosis in COVID-19: A systematic review of cases reported worldwide and in India. *Diabetes Metab Syndr.* 2021;15(4):102146. doi:10.1016/j.dsx.2021.05.019.
4. Ravi MB, Srinivas S, Silina E, Sengupta S, Tekwani T, Achar RR, et al. Prosthetic rehabilitation of rhino orbital mucormycosis associated with COVID-19: A case series. *Clin Cosmet Investig Dent.* 2022;14(1):1–10. doi:10.2147/CCIDE.S346315.
5. Lanzara R, Thakur A, Viswambaran M, Khattak A. Fabrication of ocular prosthesis with a digital customization technique -A case report. *J Family Med Prim Care.* 2019;8:1239–42.
6. Huber H, Stephan PS. Materials and techniques in maxillofacial prosthodontic rehabilitation. *Oral Maxillofac Surg Clin North Am.* 2002;14(1):73–93.
7. Chalian VA, Majid AA, Leckrone WR. Milling machine for coloring heat-vulcanizing silicone materials in maxillofacial prosthetics. *J Prosthet Dent.* 1974;31(1):78–82.
8. Kulkarni RS, Nagda SJ. Colour stability of maxillofacial silicone elastomers: a review of the literature. *Eur J Prosthodont Restor Dent.* 2014;22(3):108–15.
9. Guttal SS, Patil NP, Nadiger RK, Kulkarni R. A study on reproducing silicone shade guide for maxillofacial prostheses matching Indian skin color. *Indian J Dent Res.* 2008;19(3):191–5.
10. Türksayar AAD, Saglam SA, Bulut AC. Retention systems used in maxillofacial prostheses: A review. *Niger J Clin Pract.* 2019;22(12):1629–34.
11. Kanathila H, Pangi A. The changing concepts in the retention of maxillofacial prosthesis from past to present- a review. *J Evolution Med Dent Sci.* 2017;6(84):5879–83.
12. Retenr S, Kumar S, Shankar R, Krishna H, Kumar S. Extra oral implants as retentive aids for maxillofacial prosthesis: A review. *J Appl Dent Med Sci.* 2016;2(2):135–42.

#### Author biography

**Harmandeep Dhaliwal**, Post Graduate Student  <https://orcid.org/0009-0008-2589-6145>

**Jyoti Tembhurne**, Professor and Head

**Arti Gangurde**, Associate Professor

**Niraja Jaiswal**, Associate Professor

**Pradnya Salian**, Post Graduate Student

**Cite this article:** Dhaliwal H, Tembhurne J, Gangurde A, Jaiswal N, Salian P. Restoring facial harmony: Prosthetic rehabilitation of an orbital defect secondary to post-COVID mucormycosis - A case report. *IP Ann Prosthodont Restor Dent* 2024;10(2):160-164.