

Content available at: <https://www.ipinnovative.com/open-access-journals>

IP Annals of Prosthodontics and Restorative Dentistry

Journal homepage: <https://www.aprd.in/>

Case Report

Clinical applications of diode lasers in dentistry - Case series with review of literature

Hema Kanathila^{1*}, Ashwin Pangi², Suidha Patil¹, Meeha Peter¹,
Bharathi Poojary³

¹Dept. of Prosthodontics, KAHER KLE VK Institute of Dental sciences, Belgaum, Karnataka, India

²Aesthetix Dental Clinic, Belgaum, Karnataka, India

³Dept of Periodontics, Sharavathi Dental College, Shimoga, Karnataka, India



ARTICLE INFO

Article history:

Received 27-01-2024

Accepted 26-02-2024

Available online 16-03-2024

Keywords:

Diode lasers

Photo biomodulation

Soft tissue lesions

Surgical excision

Low level laser therapy

Crown lengthening

Ulcer

Painless

Bloodless

Healing

ABSTRACT

In the realm of dentistry, lasers make it possible to administer numerous treatment modalities more effectively, leading to successful outcomes in the majority of cases. Numerous applications of lasers in general practice and implantology have been shown to be more efficient than traditional ones. Dental professionals are better able to choose the ideal wavelength and mode for various patients during clinical procedures when they have a complete understanding of lasers, their features, and mechanisms of action. Lasers have been used in a variety of therapeutic modalities, including pain management, the removal of soft tissue lesions, crown lengthening, sulcus uncovering operations in implantology, etc. This article shows the application of diode lasers successfully in various dental treatment procedures.

This is an Open Access (OA) journal, and articles are distributed under the terms of the [Creative Commons Attribution-NonCommercial-ShareAlike 4.0 License](https://creativecommons.org/licenses/by-nc-sa/4.0/), which allows others to remix, tweak, and build upon the work non-commercially, as long as appropriate credit is given and the new creations are licensed under the identical terms.

For reprints contact: reprint@ipinnovative.com

1. Introduction

Laser dentistry is becoming more and more popular. Dental experts must evaluate which lasers are most suited for specific uses. While it speeds up and simplifies the treatment process for dental experts, it is also more affordable and completely painless for patients, lowering their anxiety throughout the procedure. Endre Mester briefed on the application of laser bio stimulation, and it was shown to have a dual nature of stimulation as well as suppression of biological effects, thus producing photo biomodulation (PBM) effects.¹

Diode lasers have demonstrated their efficacy in photobiomodulation as well as the excision of soft tissue lesions and mucogingival surgeries. They provide a clear

surgical view by reducing bleeding, disinfecting the site, eliminating post-operative pain, reducing surgical time, and promoting faster healing. Diode lasers are also bactericidal and can be used for adjunctive periodontal procedures.

2. Case Presentations

2.1. Case 1: Diode laser in the excision of Epulis fissuratum

A 56-year-old female patient reported to our dental clinic with an ill-fitting lower complete denture and a tissue growth in the lower vestibule. A thorough medical history was taken and it was noted that the patient was suffering from Type 2 Diabetes Mellitus, for which she was undergoing treatment. On intraoral examination, a fibrous hyperplastic lesion was noted in the buccal

* Corresponding author.

E-mail address: hemak_19@yahoo.com (H. Kanathila).

mucosa of the anterior mandibular vestibule. The fibrous growth was presented with irregular borders. It was pink and approximately 6mm x 15mm in its dimensions. A provisional diagnosis of epulis fissuratum was made. Excision of the hyperplastic growth with a diode laser and its advantages were explained to the patient. Taking her medical history into consideration, diode laser surgery was given more priority than scalpel surgery in this patient.

The Diode laser fibre tip was initiated using articulating paper at the tip with 2W power. Tip initiation was done to concentrate the laser energy at the tip for the procedure and to prevent the exit of laser energy from the handpiece. The lesion was excised using a diode laser (Novolase Diode Laser) with an 810 nm wavelength in contact mode. (Figure 1)

Excised tissue growth was immersed in 10% formalin and sent for histopathological examination. A thorough irrigation of the operative field was done using normal saline. In this case, the need for sutures and periodontal packs was nullified by the advantages of diode lasers, providing a bloodless, painless, and sterile environment. The wound was left open and allowed for secondary healing (Figure 2). The patient was advised on the diet and was told to avoid spicy and hot foods for a minimum of 5 days to avoid post-operative complications. Medications were not prescribed. Warm salt water mouth rinses were advised thrice daily. The patient was recalled after a week to assess the healing of the anterior mandibular vestibular region and it was found to be uneventful (Figure 3).

2.2. Case 2: Diode laser in tongue ulcer

A 55-year-old male patient reported having a painful tongue and difficulty in having food. There was no significant medical history. On oral examination, small ulcers greater than 5 mm in diameter were noted on the lateral aspects of the tongue. A provisional diagnosis of traumatic ulcer was made (Figure 4).

The diode laser with 660nm wavelength, 100mW for 60 seconds was the treatment of choice. Because of the acute nature of the ulcer, laser therapy was given on the first, second, third, and fourth days. It was noted that the pain subsided immediately after PBM on the first day (Figure 5). Consequently, at the second appointment, healing of the ulcer and a decrease in pain were noted. On the 3rd day of the follow-up appointment, the size of the ulcer had reduced and the ulcer had healed completely.

2.3. Case 3: Diode laser in crown lengthening

A female patient of 45 years of age reported to our clinic with dislodged crowns and pain in the upper left back tooth region. On clinical examination, 24,25 were found to have deep caries and short clinical crown height (Figure 6). The patient was advised for root canal treatment, crown

lengthening, post and core, followed by crowns.

Post endodontic treatment, crown lengthening was planned using an 810nm diode laser. A soft tissue Diode Laser (Novolase) tip with contact mode at 2 W in continuous wave mode was used for the excision and contouring of the gingival cuff around the tooth. No pain or bleeding was reported. Good gingival contours were achieved after 1 week postoperatively (Figure 7).

2.4. Case 4: Diode laser in denture soreness

A male patient aged 65 years reported to our clinic with severe pain in the upper right back tooth region. On clinical examination, a small erythematous area was located in the upper right back tooth region due to denture irritation (Figure 8).

Photo biomodulation with a 660nm diode laser, 50mW for 60 seconds, was planned. The pain was reduced at the first appointment, and after 2 days on the follow-up visit, the ulcer was noted to have healed completely (Figure 9).

2.5. Case 5: Diode laser in soft tissue uncovering in implantology

A male patient aged 55 years old reported to our clinic for the replacement of missing teeth in the lower anterior region. Implant placement was done in the lower anterior region of the jaw. The patient visited the clinic for 2nd stage surgery for ball abutment placement. It was noted that the implant was covered with soft tissue (Figure 10), and the removal of the soft tissue growth over the implant was planned using an 810nm diode laser at 2W under local anesthesia. After soft tissue uncovering, the cover screw was removed and the placement of the ball abutment was done on the same visit (Figure 11).

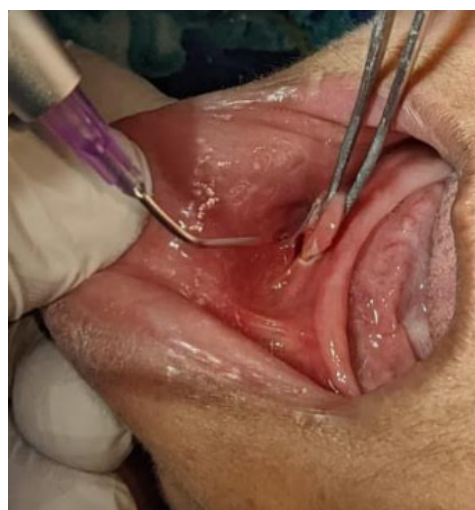

Figure 1: Surgical excision using diode laser

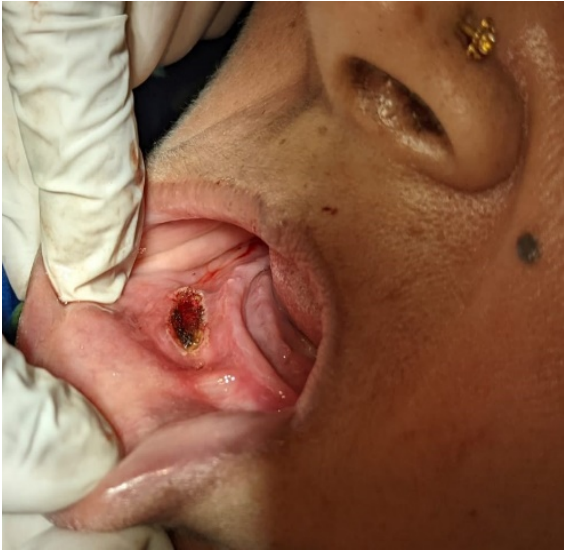

Figure 2: After excision of Epulis fissuratum

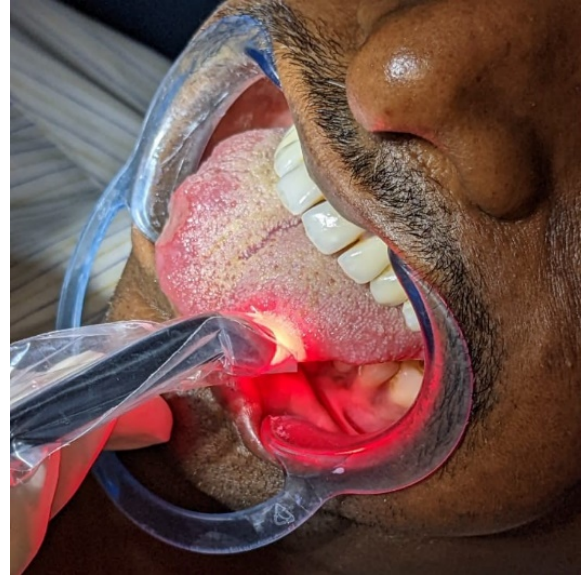


Figure 5: Photobiomodulation on first appointment

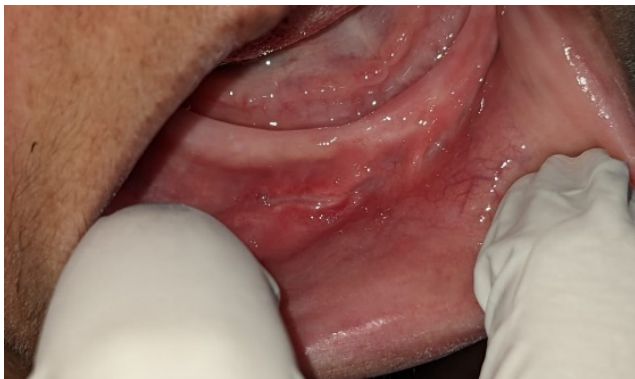

Figure 3: Post healing

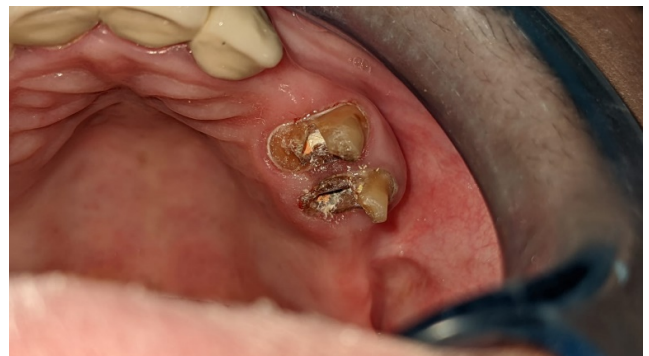

Figure 6: Short clinical crown height of premolars

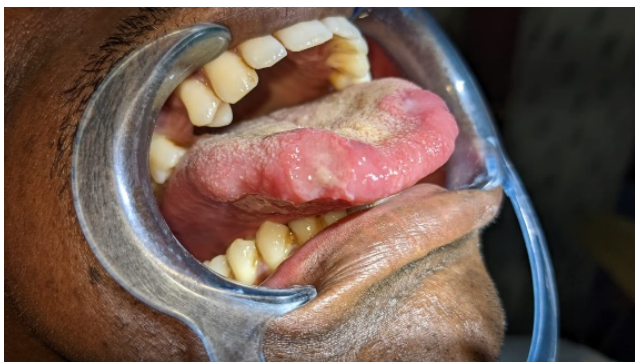

Figure 4: Traumatic tongue ulcer

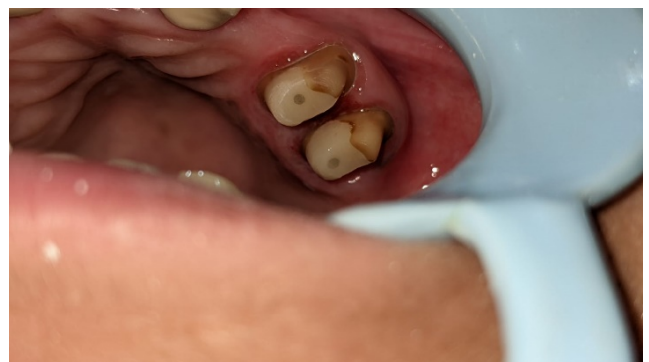

Figure 7: After crown lengthening using diode laser

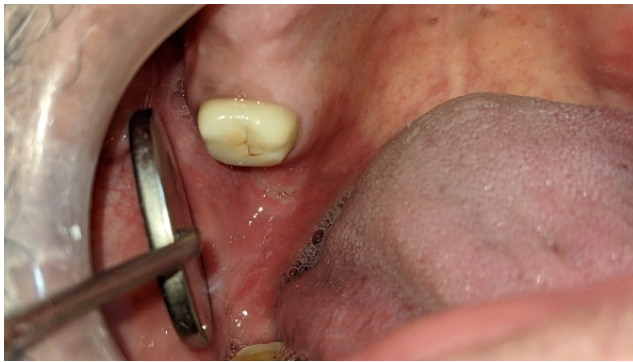

Figure 8: Denture soreness

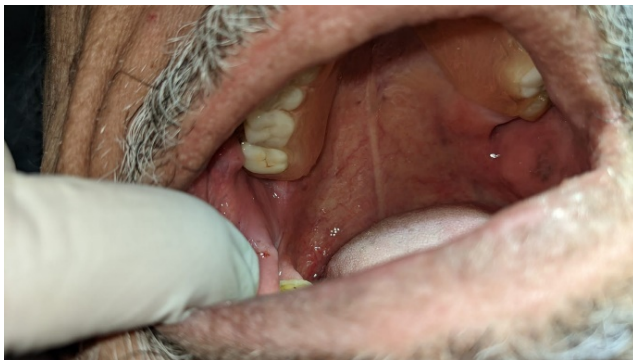

Figure 9: Healed Denture soreness

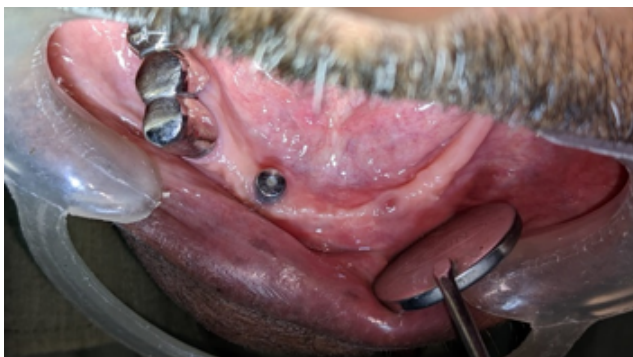

Figure 10: Implant covered with soft tissue

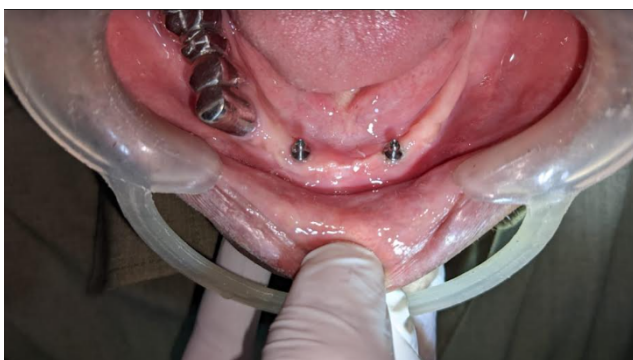

Figure 11: Placement of ball abutment on the same visit

The main advantage of this case of using lasers was that, as it provided a bloodless operative field, the benefit of being able to place the ball abutments and pick up of the o-ring sleeves in the denture was done on the same day.

3. Discussion

Laser technology in dentistry has a vast number of applications, starting from photobiomodulation effects to surgical excisions. Applications of lasers in dental clinical as well as lab procedures have improved due to their increased demand. Photo biomodulation, otherwise known as Low Level Laser Therapy (LLLT), uses low-level power light to enhance wound healing, reduce inflammation and relieve pain. It has a direct action on the cell behaviours, thereby enhancing the tissue repair. They have a biphasic dose response with low levels of light having stimulating effects, whereas excessive levels of light have inhibiting ones. Soliman et al, in their study evaluated the pain-relieving and healing capacity of diode lasers at 660 nm wavelength in 20 healthy patients with minor recurrent aphthous stomatitis.² And this treatment showed remarkable improvements in the reduction of pain, size, and healing time. A number of cases have been successfully treated with laser in dentistry, which is shown in Table 1.²⁻⁶

Lasers that can be used for excision include the CO₂ laser, the Erbium: YAG laser, the Neodymium: YAG laser, and the diode laser.⁷ The advantages of laser therapy include minimal bleeding, decreased post-operative pain, faster wound healing, no edema, and the exclusion of sutures.⁸ These advantages have led to the vast application of lasers in minor surgeries. CO₂ lasers and Nd: YAG lasers have been applied in soft tissue excision because of their ablation ability, but they have the disadvantage of their thermal effects on target tissues, which can delay the initial repair mechanism.

In our case report, the advantages of the crown lengthening procedure with diode laser were that it was a bloodless procedure, providing good gingival contour a week later. Conclusions from another study has emphasized that laser can be a safe and effective alternative to conventional crown lengthening using scalpel.⁹ In a case series, Gokulanathan et al. presented three cases of crown lengthening using a diode laser and concluded that it was a safe and efficient procedure.⁵

Erbium (Er: YAG and Er: Cr: YSGG) lasers are also widely used in dentistry.¹⁰ Fekrazad et al. have reported the effectiveness of using the Er; Cr: YSGG laser for crown lengthening procedures.¹¹

Table 1: Effectiveness of different soft tissue lasers on different cases

Author	Year	Laser therapy	Wavelength	Case	Outcome
Soliman et al ²	2019	Photobiomodulation	660nm	Minor aphthous ulcer	Effective in reducing pain size and healing time
Ryu et al ³	2021	Photobiomodulation	660-940nm	Oral mucositis caused by chemo and radiotherapy	Effective in reducing the pain, lesion size and reduces healing time
Chen et al ⁴	2021	Photothermal effect	810nm	Vascular epulis	Surgical time was shorter, good therapeutic effect after 5 year follow up
Gokulanathan et al ⁵	2014	Photothermal effect	Diode laser (wavelength not mentioned)	Crown lengthening	Safe, no infection,pain, swelling or scarring
Manvir et al ⁶	2018	Photothermal effect	810nm	Second stage surgery in implant	Improves visibility, less surgical trauma, absence of bleeding, less discomfort

3.1. Why Diode lasers are preferred over other treatment modalities?

Diode lasers are considered as an excellent option for photo biomodulation and surgical excision of any soft tissue growth compared to conventional scalpel surgery. It provides quite a lot of benefits than other lasers due to its small size, transmission via fibre optics, and a wide range of spectrum. Diode lasers remove or excise the soft tissue lesion based on its photothermal effect. They allow good visibility of the operative field as they seal the smaller blood vessels, making it a bloodless procedure. Apart from this, other advantages of laser surgery include sterilization of the operative field instantly, hence elimination of bacteremia, minimum mechanical trauma, hence minimum post-operative swelling and minimum post operative pain, reduced scarring and shrinkage of the tissue. As it requires no sutures after the procedure, the healing takes place by secondary intention. The overall time required for laser surgery is also less, compared to the scalpel surgical procedure.

Diode lasers in particular have unique properties such as definite and sharp cutting edges, better action, hemostasis and coagulation after the surgical procedure, which makes them very efficient compared to CO₂ lasers and erbium lasers. When considering the disadvantages compared to scalpel surgery, it is quite similar to the other lasers, such as charring tissue in case of smaller lesions and delayed repair in the case of larger lesions.¹²

The CO₂ laser causes less collateral damage to the edges of the lesion during excision and is used in many cases of soft tissue surgery. But the main drawback is the cost and difficulty in its handling, which makes the practitioners prefer the diode laser.¹³ Similar to the CO₂ laser, the wavelength of the erbium laser makes its penetration less into the tissue, hence the injury caused by it is comparatively less than that of diode lasers, thus giving a faster recovery result. Diode lasers have been considered safe compared

to Nd: YAG lasers as the collateral damage caused by the Nd: YAG laser is greater than the diode laser because of its wavelength and penetrating depth.¹⁴

4. Conclusion

Now a days patients demand for painless, bloodless treatment procedures. To meet these clinical needs of patients and to ensure the smooth operation of clinical practice, dental professionals must live up to their patients' expectations by providing the same. Aside from that, soft tissue management is critical in clinical procedures for a successful treatment outcome. With their wide clinical applications and numerous added benefits, lasers have set a new standard in dentistry. The laser approach assists the clinician in meeting the patient's expectations and providing comfortable treatment for the patients. Laser's photobiomodulatory effects, as well as their ability to remove smaller lesions with minimal patient discomfort and faster post-operative healing, make them an attractive option for use in routine dental procedures.

5. Source of Funding

None.

6. Conflict of Interest


None.


References

- Asan M, Babu G, Castelino R, Rao K, Pandita V. Applications of Photobiomodulation Therapy in Oral Medicine-A Review. *Eur J Ther.* 2021;27(2):177–82.
- Soliman HA, Mostafaa D. Clinical Evaluation of 660 nm Diode Laser Therapy on the Pain, Size and Functional Disorders of Recurrent Aphthous Stomatitis. *Open Access Maced J Med Sci.* 2019;7(9):1516–22.
- Ryu H, Abueva C, Chung PS, Woo SH. Decade long survey of low-level laser therapy/photobiomodulation therapy (LLLT/PBM) for oral mucositis treatment. *Med Laser.* 2021;10(3):138–42.

4. Chen TL, Wang XM, Zhang XH, Chen J, Liu J. Therapeutic effects of diode laser on vascular epulis in esthetic area. *J Indian Soc Periodontol.* 2021;25(1):75–7.
5. Gokulanathan S, Mathews D, Daniel R, Ahathya R. Crown lengthening using diode laser: A case series. *J Indian Acad Dent Spec Res.* 2014;1(2):77–9.
6. Kaur M, Sharma YPD, Singh P, Sharma S, Wahi A. Comparative evaluation of efficacy and soft tissue wound healing using diode laser (810 nm) versus conventional scalpel technique for second-stage implant surgery. *J Indian Soc Periodontol.* 2018;22(3):228–34.
7. Mekayssi R, Taleb B, Merzouk N, Benfdil F. The Prosthetic Management of a Case of Epulis Fissuratum by a Novel Technique. *Odovtos Int J Dent Sci.* 2021;23(2):27–32.
8. Atashrazm P, Sadri D. Prevalence of Oral Mucosal Lesions in a Group of Iranian Dependent Elderly Complete Denture Wearers. *J Contemp Dent Pract.* 2013;14(2):174–8.
9. Farista S, Kalakonda B, Koppolu P, Baroudi K, Elkhatat E, Dhaifullah E, et al. Comparing Laser and Scalpel for Soft Tissue Crown Lengthening: A Clinical Study. *Glob J Health Sci.* 2016;8(10):55975. doi:10.5539/gjhs.v8n10p73.
10. Khalifa C, Bouguezzi A, Sioud S, Hentati H, Selmi J. An innovative technique to treat epulis fissuratum: A case report. *SAGE Open Med Case Rep.* 2021;9:2050313. doi:10.1177/2050313X211063135.
11. Fekrazad R, Nokhbatolfoghahaei H, Khoei F, Kalhori KA. Pyogenic Granuloma: Surgical Treatment with Er:YAG Laser. *J Lasers Med Sci.* 2014;5(4):199–205.
12. Azma E, Safavi N. Diode laser application in soft tissue oral surgery. *J Lasers Med Sci.* 2013;4(4):206–11.
13. Cano-Durán JA, Ortega-Concepción D, PeñaCardelles JF, Sáez-Alcaide LM, Paredes-Rodríguez VM, López-Quiles J, et al. Employment of Diode Laser in the Treatment of Epulis Fissuratum. Case Report. *IOSR J Dent Med Sci.* 2017;16(5):112–5.
14. Asnaashari M, Zadsirjan S. Application of laser in oral surgery. *J Lasers Med Sci.* 2014;5(3):97–107.

Author biography

Hema Kanathila, Professor  <https://orcid.org/0000-0002-5876-1377>

Ashwin Pangi, Consultant Prosthodontist  <https://orcid.org/0000-0002-5480-8932>

Suvidha Patil, Lecturer

Meekha Peter, Consultant Prosthodontist

Bharathi Poojary, Reader

Cite this article: Kanathila H, Pangi A, Patil S, Peter M, Poojary B. Clinical applications of diode lasers in dentistry - Case series with review of literature. *IP Ann Prosthodont Restor Dent* 2024;10(1):76-81.