

Content available at: <https://www.ipinnovative.com/open-access-journals>

IP Annals of Prosthodontics and Restorative Dentistry

Journal homepage: <https://www.aprd.in/>

Case Report

Repositioning of herniated buccal fat pad following blunt trauma - Rare case report in pediatric patients

Divya Sanjay Sharma¹, Zeba Ambreen^{1*}, Himani Gupta¹, Nehal Ahmad¹, Saima Yunus Khan¹

¹Dept. of Pediatric and Preventive Dentistry, Dr. Ziauddin Ahmad Dental College, Aligarh Muslim University, Aligarh, Uttar Pradesh, India



ARTICLE INFO

Article history:

Received 13-12-2023

Accepted 20-02-2024

Available online 16-03-2024

Keywords:

Buccal fat pad herniation

Pseudolipoma

Pediatric patient

ABSTRACT

Herniation of the buccal fat pad in pediatric patients is a rare injury, occurring due to a breach in the buccinator muscle, often termed traumatic pseudolipoma in infants. This condition plays a crucial role in cheek contour in adults. Two case reports detailing the management of this rare injury in young children emphasize the importance of assessing mucosal perforation and considering previous trauma history for accurate diagnosis. These reports provide valuable insights for healthcare professionals, contributing to the understanding and management of uncommon medical conditions.

This is an Open Access (OA) journal, and articles are distributed under the terms of the [Creative Commons Attribution-NonCommercial-ShareAlike 4.0 License](https://creativecommons.org/licenses/by-nc-sa/4.0/), which allows others to remix, tweak, and build upon the work non-commercially, as long as appropriate credit is given and the new creations are licensed under the identical terms.

For reprints contact: reprint@ipinnovative.com

1. Introduction

Bichat's fat, commonly referred to as the buccal fat pad, exhibits greater prominence in neonates, infants, and young children.

Buccal fat pad, also known as bichat fat, is more prominent in newborns, infants, and young children.^{1,2} it gives a plump look to the face and also help in supporting cushioning and suction for newborns and children. This buccal fat pad is anatomically found in-between the masseter and buccinator muscles. it supports muscles during sucking in infants, and in adults it plays an important role in defining the contour of the cheeks. These structures serve as a protective barrier, shielding delicate facial muscles from harm resulting from both muscle contractions and external impacts. In babies, even a minor injury to the buccinator muscle has the potential to lead to an intraoral hernia.³

More frequently, these incidents occur when children experience falls while having items in their mouths, like

pens, toothbrushes, lollipops, utensils, and straws. Such incidents can lead to injuries in the mucosal tissue and the development of fatty hernias.⁴ Limited literature exists regarding cases of traumatic herniation where the buccal fat pad protrudes into the oral cavity.⁵⁻⁷ This condition is also referred to as traumatic pseudolipoma.

2. Case 1

A 3-year-old boy was brought up by his parents to TRAUMA centre. His parents reported with complaint of noticeable intraoral mass adjacent to the tongue protruding from the left buccal mucosa following injury in his mouth by pencil. The injury led to slight bleeding from the mouth and mild swelling of the face. The bleeding stopped spontaneously. Several hours later, around 3 hours post-injury, the mother observed a significant mass that hadn't been present initially. Additionally, the child experienced discomfort while chewing, prompting them to seek medical attention at the trauma centre. There was no history of loss of consciousness or vomiting. Vitals were within

* Corresponding author.

E-mail address: zebaambreen123@gmail.com (Z. Ambreen).

normal limit. On examination child was active and healthy with no other associated injury. Intraoral examination revealed a large approximately 2*2 cm reddish yellow, soft, pedunculated mass extending from a laceration of the left buccal mucosa at the level of the occlusion of primary molars. (Figure 1a) This intraoral mass was non tender, ovoid, smooth and freely mobile on palpation. When retracted, a 1.5 cm laceration of the buccal mucosa was noticeable. The mass was homogenous and a provisional diagnosis of traumatic herniation of buccal fat pad was made.

Following appropriate investigations and with the patient's informed consent, the necessary intervention was performed under local anaesthesia, using 2% lignocaine. Since there were no indications of necrosis, atrophy, or capsule tear, the decision was made to reposition the protruding buccal fat pad (BFP) despite its size. The exposed BFP was meticulously cleansed with saline and gently maneuvered back to its normal anatomical position through the existing defect or laceration. The wound was then secured with 3-0 vicryl sutures (an absorbable suture material) (Figure 1b). The patient was prescribed a course of amoxicillin antibiotics for five days. After discharge, a follow-up appointment was scheduled for one week, during which intraoral mucosal healing progressed smoothly (Figure 1c). and there were no complications observed six months post-intervention.

3. Case 2

A 2.5-old boy was brought up by his parents to TRAUMA centre. His parents were complaining of protruding intraoral mass beside the tongue from the left side of cheek while he was playing with a knife in his mouth. An injury resulted with minimal bleeding from the mouth along with mild facial oedema. His mother noticed a large mass with respect to left cheek which was coming in between teeth when occluded and while chewing. They reported 12 hours after the injury to the TRAUMA centre for the same. There was no history of loss of consciousness or vomiting. Vitals were within normal range. On examination child was active and healthy with no other associated injury. Intraoral examination revealed a large approximately 3*2 cm reddish yellow, soft, pedunculated mass was seen extending from a laceration of the left buccal mucosa at the level of the occlusion of primary molars. (Figure 1d) This intraoral mass was non tender, ovoid, smooth and freely mobile on palpation. When retracted, a 1.5 cm laceration of the buccal mucosa was noticeable. The mass was homogenous and a provisional diagnosis of traumatic herniation of buccal fat of pad was made. There was no sign of necrosis or atrophy of the capsule. The intervention was done in the patient under local anesthesia (with 2% lignocaine) after getting informed consent from the patient's parents. In this case also, it was decided to reposition the intraoral mass. After

thoroughly cleansing the protruding BFP with saline, it was gently pushed back to its normal anatomic site, through the existing incision.

The wound was ligatured or sutured with 3-0 vicryl sutures (absorbable suture material). (Figure 1e) The patient was medicated for five days with the course of amoxicillin antibiotics. The patient was discharged and recalled after one week for evaluation. There was satisfactory mucosal healing. (Figure 1f)

4. Discussion

The buccal fat pad consists of a lobulated structure with buccal extension toward the mandible, pterygoid extension toward the temporal bone filling the pterygomandibular space, pterygopalatine extension filling the infra-temporal fossa, and temporal extension toward the ears, as it lines the masticatory space aiding in mastication.⁵ It is situated in between masseter and buccinator muscles.⁵ The BFP is comparatively larger in infants than children and adults; therefore, even a minor trauma leading to tear of the buccinator muscle can cause herniation of BFP intraorally.⁸

Differential diagnosis of traumatic pseudolipoma includes pyogenic granuloma, inflammatory pseudotumour, foreign body granuloma, traumatic neuroma, lipoma, hemangioma, and salivary neoplasm.⁹ There are some peculiar features of traumatic pseudolipoma that make its diagnosis simple such as there is always a history of trauma in such patients, there is absence of the mass before the accident, it has a very specific anatomic site, and adipose-like appearance. All these findings were positive in our cases and lead to the diagnosis of buccal fat pad herniation. There was also a history of swelling that appeared after sometime of trauma which gradually increased in size and there was difficulty in chewing and speaking.² Intraoral mass was red yellowish homogenous, non-tender, soft with smooth borders, and a non-blanchable mass. There are two treatment protocols which can be implicated for treating traumatic pseudolipoma which include either excision of the whole mass or it's reposition. Irrespective of the approach applied, care must be taken to avoid the damage of parotid duct and its aperture. In this case, tissue restoration with primary wound closure was done as it is effective when an early diagnosis is made (in approximately 4 hours) prior to the development of inflammatory alterations. Excision of whole tissue from base of buccal mucosa is preferred in those cases when there is a delay between diagnosis and treatment due to tissue contamination and necrosis.² However in case 2 even when the patient reported after 12 hour there was no sign of necrosis. Hence, we opted for repositioning of buccal fat pad. Among the cases which have been documented, Horie N et al., Clawson JR et al., and Fleming P preferred to reposition the buccal fat pad to it's anatomic position through the laceration present in the mucosa.⁹⁻¹¹ Interestingly, among all the reported cases, the

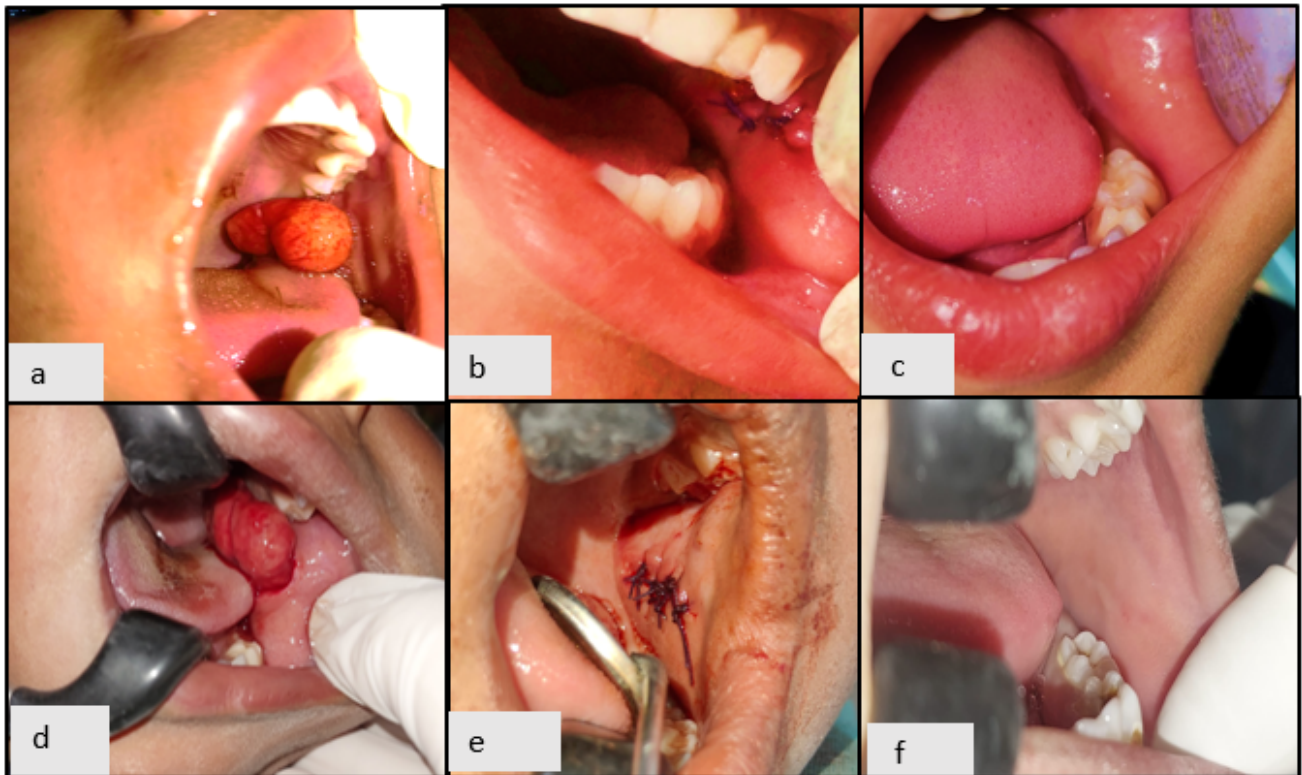


Figure 1: a and d: Herniation of Buccal fat; b: and e: after repositioned back the protruded mass; c and f: One-week followup showing satisfactory healing

aetiology was intraoral trauma at the occlusal level, with near proximity to the parotid papilla.

Both the treatment modalities have showed good prognosis, however the repositioning of buccal fat pad has better immediate postoperative symmetry and also as the pad one excised cannot be regenerated. The known complication of this method is necrosis of the BFP, and that of excision are facial disfigurement and difficulty in jaw movement.

5. Conclusion

Keen observation through follow-up revealed that the herniated BFP adjusted itself after its reposition and wound closure. It can be concluded that the patients should be thoroughly evaluated for any preceding history of trauma and examined carefully for any mucosal protrusion, laceration or extension.

6. Source of Funding

None.

7. Conflict of Interest

None.

References

1. Fregnani ER, Pires FR, Falzoni R, Lopes MA, Vargas PA. Lipomas of the oral cavity: clinical findings, histological classification and proliferative activity of 46 cases. *Int J Oral Maxillofac Surg.* 2003;32(1):49–53.
2. Sah K, Chandra S, Kale A, Awasthi S, Rastogi P. Traumatic pseudolipoma causing facial asymmetry: An uncommon pathology and review of its pathogenesis. *J Oral Maxillofac Pathol.* 2011;15(1):113–5.
3. Ramourar VRN, Patel PP, Isache CL. An unusual presentation of ventral posttraumatic pseudolipomas in a surfer: a case report. *Eur J Med Case Rep.* 2017;1:40–3.
4. Kim SY, Alfara A, Kim JW, Kim SJ. Traumatic buccal fat pad herniation in young children: a systematic review and case report. *J Oral Maxillofac Surg.* 2017;75(9):1926–31.
5. Gadhia K, Rehman K, Williams RW, Sharp I. Traumatic pseudolipoma: herniation of buccal fat pad, a report of two cases. *Int J Oral Maxillofac Surg.* 2009;38(6):694–6.
6. Gadipelly S, Sudheer MV, Neshangi S, Harsha G, Reddy V. Traumatic herniation of buccal fat pad in 1 year old child: case report and review of literature. *J Maxillofac Oral Surg.* 2015;14(Suppl 1):435–7.
7. Chaudhry K, Singh C, Shishodia M. Traumatic herniation of the buccal fat pad into the oral cavity of a 3.5-year-old boy: a case report. *J Calif Dent Assoc.* 2016;44(5):297–9.
8. Ghosh C, Jana B, Garai D, Mandal PK. Traumatic intraoral herniation of the buccal pad of fat in paediatric patients: Report of two cases. *Int J Pediatr Rehabil.* 2019;4(1):26–30.
9. Horie N, Shimoyama T, Kaneko T, Ide F. Traumatic herniation of the buccal fat pad. *Paediatr Dent.* 2001;23(3):249–52.
10. Clawson JR, Kline KK, Armbrrecht EC. Trauma-induced avulsion of the buccal fat pad into the mouth: Report of a case. *J Oral Sur.*

1968;26(8):546–7.

11. Fleming P. Traumatic herniation of buccal fat pad: A report of two cases. *Br J Oral Maxillofac Surg*. 1986;24(4):265–8.

Author biography

Divya Sanjay Sharma, Professor  <https://orcid.org/0000-0002-6464-1152>

Zeba Ambreen, Junior Resident III

Himani Gupta, Junior Resident

Nehal Ahmad, Junior Resident

Saima Yunus Khan, Professor

Cite this article: Sharma DS, Ambreen Z, Gupta H, Ahmad N, Khan SY. Repositioning of herniated buccal fat pad following blunt trauma - Rare case report in pediatric patients. *IP Ann Prosthodont Restor Dent* 2024;10(1):72-75.