

Content available at: <https://www.ipinnovative.com/open-access-journals>

IP Annals of Prosthodontics and Restorative Dentistry

Journal homepage: <https://www.aprd.in/>

## Case Report

# Root canal treatment of a rhizomegaly tooth 36 mm long right permanent maxillary canine – A case report

Kiran Reddy<sup>1</sup>, Anita Kapri<sup>2\*</sup>, Varun Rana<sup>2</sup>, Oliver Jacob<sup>2</sup>, Pushpa Kumari<sup>2</sup>

<sup>1</sup>Dental Centre, INHS Kalyani, Visakhapatnam, Andhra Pradesh, India

<sup>2</sup>Dept. of Prosthodontics, INHS Kalyani, Visakhapatnam, Andhra Pradesh, India



### ARTICLE INFO

#### Article history:

Received 06-12-2023

Accepted 15-01-2024

Available online 16-03-2024

#### Keywords:

Rhizomegaly

Permanent Maxillary canine

Root canal anatomy

Protaper Hand file

Gates glidden drills

Root canal treatment

### ABSTRACT

**Introduction:** Permanent maxillary canines can have variable length even exceeding 31 mm. The present case report is about the root canal treatment of a permanent maxillary canine with an unusual length of 36 mm

**Case Report:** A 37-year old male patient has come to Dental centre, Cannanore suffering from decay on tooth #13 with extra-oral swelling corresponding to right cheek. Root canal treatment was completed, and the tooth was noticed to have an atypical length of 36 mm. A 31 mm long Hand protaper file was used to do cleaning and shaping and Gates glidden drills of sizes 2 & 3 were used to enlarge the canal orifice to receive gutta percha during obturation.

This is an Open Access (OA) journal, and articles are distributed under the terms of the [Creative Commons Attribution-NonCommercial-ShareAlike 4.0 License](https://creativecommons.org/licenses/by-nc-sa/4.0/), which allows others to remix, tweak, and build upon the work non-commercially, as long as appropriate credit is given and the new creations are licensed under the identical terms.

For reprints contact: [reprint@ipinnovative.com](mailto:reprint@ipinnovative.com)

## 1. Introduction

Successful Root Canal Treatment can only be achieved with correct radiographic investigations, correct diagnosis, correct armamentarium and correct treatment protocol. Therefore the clinician should have sound knowledge to judge what all to be implemented to increase the prognosis of the case.<sup>1</sup> Studies on tooth anatomy report various mean lengths for various tooth types. In permanent maxillary canines, they have been found with usual mean lengths of 26.5 mm,<sup>2</sup> 27.3 mm,<sup>3</sup> and 26.8 mm.<sup>4</sup> A number of studies have been conducted to recognize the length of human permanent maxillary canine. In 1902, G.V Black published a case of longest maxillary cuspid with length 32.0 mm,<sup>2</sup> while Bjorndal et al. reported a case of longest maxillary canine with length 33.3 mm in 1974.<sup>3</sup> In 1979, Wiene reported an extracted human permanent maxillary canine of an unusual 39.5 mm length.<sup>5</sup> The present case

report describes root canal treatment of a peri-apical abscess infected 36 mm long maxillary canine with a discussion on the technique employed in root canal cleaning, shaping and obturation.

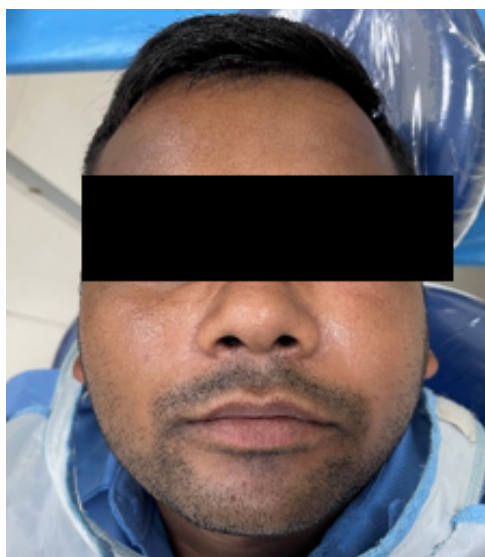## 2. Case Report

A 37 year old male patient with no significant past systemic medical history reported with a chief complaint of decayed tooth in the right upper front tooth region associated with extra-oral swelling over right cheek region. Intraoral clinical examination disclosed dental caries in right maxillary canine tooth. The tooth was infected with distal proximal dental caries and showed negative response to thermal tests, with tenderness to vertical percussion. Normal physiological mobility with swelling over the tooth apex area. Extraoral examination reveals swelling over right cheek region Figure 1. Intra oral periapical radiograph for the tooth of complaint (#13) showed unusual length of 36 mm with radiolucency confined to periapical area of

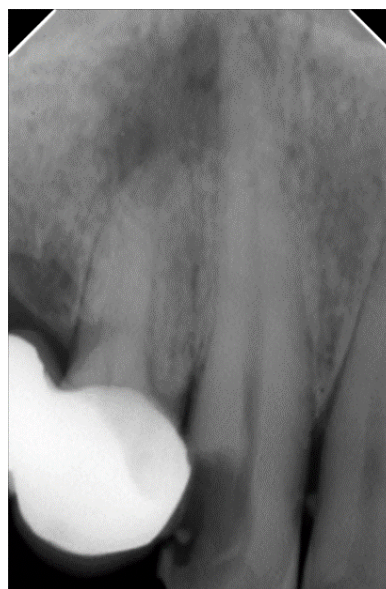\* Corresponding author.

E-mail address: [a.kapri@rediffmail.com](mailto:a.kapri@rediffmail.com) (A. Kapri).

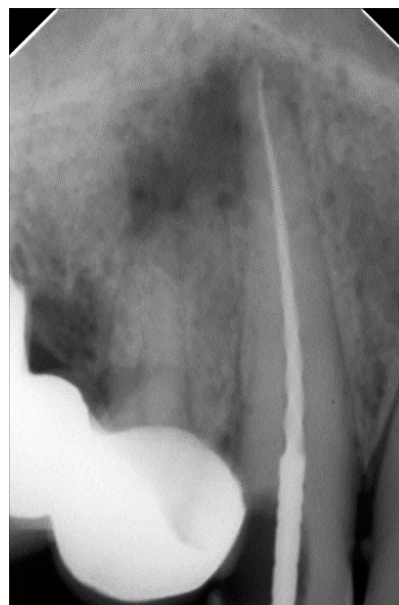maxillary canine apical foramen (Figure 2). The diagnosis reached was asymptomatic chronic periapical abscess. The patient was anesthetized (2% lignocaine with epinephrine 1:100,000 local anesthesia), carious part was removed carefully, and access cavity preparation was done. We have done cleaning & shaping using existing hand K file size 15, 20, 25 of 31 mm length (M-Access by Dentsply Maillefer) and cingulum as reference point for working length. Followed by series of Protaper Hand files Sx, S1, S2 and F1. Master file F1 IOPA was taken (Figure 3). Continuous irrigation with 2.5% sodium hypochlorite and 17% ethylene diamine tetra acetic acid (EDTA) was carried out during the cleaning and shaping phase. Intracanal Metapex was placed as an inter-appointment medicament and the access opening was secured using Cavit G (3M, ESPE). Two weeks later the swelling over right cheek resolved and patient is asymptomatic (Figure 4); the metapex was thoroughly flushed out by using Hand protaper F1 file and the canal was dried using sterile paper points. Obturation was done by using F1 size Gutta percha (Dentsply Maillefer) and Seal apex root canal sealer (KERR Sybron Endo) (Figure 5). The tooth was restored permanently by Ketac Molar (3M).



**Figure 1:** Pre-operative Extra-oral image with facial swelling (Rt)



**Figure 2:** Pre-operative IOPA with Periapical radiolucency (13)



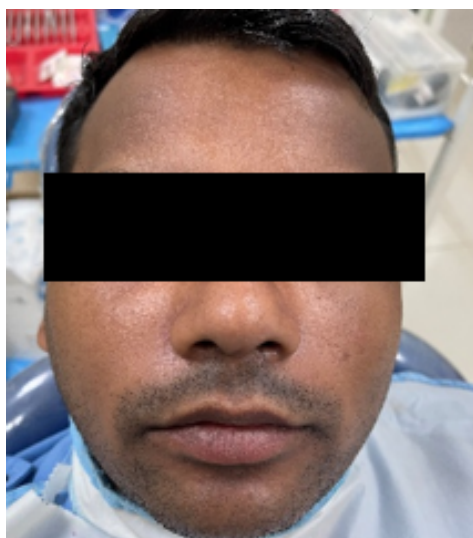**Figure 3:** IOPA with Master file

### 3. Discussion

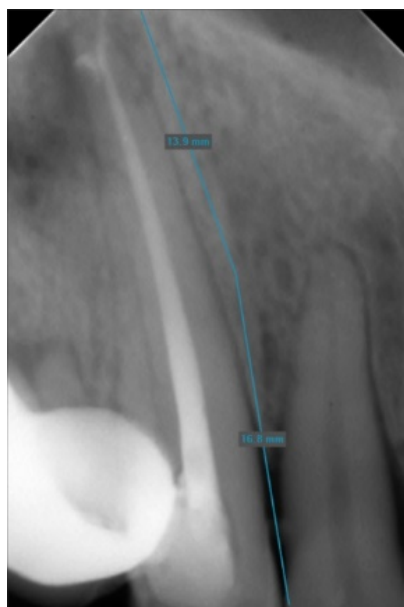
Precise working length determination is essential for successful root canal treatment, which reduces the chances of inadequate cleaning and shaping of the root canal or impairing the integrity of the peri-radicular tissues from over instrumentation.<sup>6,7</sup> The traditional way of ascertaining working length of unusual lengthy teeth through endodontic hand files of maximum available length of 31 mm is arduous.<sup>8</sup> The length of the root canal treated canine (36-mm) of this case differ so greatly from the usual length of

teeth.<sup>5</sup>

Root canal treatment of long permanent maxillary canines has been experienced by a few authors. Venokur and Fink., in 1976 canine length was estimated to be 41 mm to 42 mm, but they did not document obturation radiographically.<sup>9</sup> In 1982, Bellizzi documented and reported a case in which the maxillary canine was obturated to a working length of 38 mm.<sup>10</sup> Also, in 1992, Vargo and Hartwell modified endodontic treatment of a 40-mm long maxillary canine.<sup>11</sup> Literature search revealed a gap from 1992 without documentation of RCT of a



**Figure 4:** Post-operative Extra-oral image with resolved facial swelling (Rt)



**Figure 5:** Post-operative IOPA with obturation completed

long maxillary canine, until recently Al-Dahman et al., in 2017 treated a tooth of 32- mm.<sup>12</sup> In 2019 Cardoso et al., implemented a new technique titled “Instrument Cable Cutting Technique” (ICCT).<sup>13</sup> The root canal instrumentation of permanent maxillary canines of unusual length more than 31 mm is extremely strenuous, because the longest commercially available endodontic file is 31-mm length.<sup>14,15</sup> The endodontic file length of 31-mm makes it strenuous to widen the canal to the full working length. In this case, we have found even more difficulty during obturation as the F1 Gutta percha has huge taper at grasping end. We have enlarged the canal orifice with Gates glidden

drills of sizes 2,3. Even then the F1 Gutta percha is not reaching till the complete working length, So we have heated the grasping end of gutta percha on a flame followed by disinfection by immersing it in 5.25% Naocl for 1 minute then the F1 Gutta percha has reached till complete working length.

#### 4. Conclusion

Teeth of unusual length can be seen very often, exploring and using alternative techniques during canal instrumentation without compromising the risk of drastically reducing the sound tooth structure will enhance the prognosis of a root canal treatment. The technique employed in the present case would be one such example where we can achieve adequate canal instrumentation and obturation of the root canal without compromising the remaining sound tooth structure.

#### 5. Conflict of Interest

None.

#### 6. Source of Funding

None.


#### References

1. Vertucci FJ. Root canal morphology and its relationship to endodontic procedures. *Endod Topics*. 2005;10(1):3–29.
2. Black GV. Descriptive anatomy of the human teeth. 4th edn. Philadelphia: S. S. White Dental Manufacturing Co.; 1902.
3. Bjorndal AM, Henderson WG, Skidmore AE, Kelner FH. Anatomic measurements of human teeth extracted from males between the ages of 17 and 21 years. *Oral Surg Oral Med Oral Pathol*. 1974;38(5):791–803.
4. Verhoven JW, Van Aken J, Van Der Weerd G. The length of teeth. *Oral Surg Oral Med Oral Pathol*. 1979;47(2):193–9.
5. Weine FS. A Very Long Cuspid! *J Endod*. 1986;12(2):80–1.
6. Iqbal Z, Memon RA. Comparison between radiographic and electronic working length determination in root canal treatment in vivo study. *ISRA Med J*. 2013;5:41–6.
7. Naulakha D, Agrawal M, Naulakha N. Determination of tooth length variation of maxillary canine. *J Nobel Med Coll*. 2014;3(1):40–5.
8. De-Deus G, Reis C, Beznos D, De Abranches A, Coutinho-Filho T, Paciornik S, et al. Limited ability of three commonly used thermoplasticized gutta-percha techniques in filling oval-shaped canals. *J Endod*. 2008;34(11):1401–5.
9. Bellizzi R. Endodontic therapy associated with a case of cuspid gigantism. *Oral Surg*. 1982;53(2):199–202.
10. Vargo JW, Hartwell GR. Modified Endodontics for Lengthy Canals. *J Endod*. 1992;18(10):512–4.
11. Al-Dahman Y, Al-Hawwas A, Al-Jebaly A. AlJebaly Asma S. Root canal treatment of a 32-mm length maxillary canine - A case report. *Int J Contemp Med Res*. 2017;4(11):2297–9.
12. Barletta FB, Grecca FS, Wagner MH, Ferreira R, Lopez FU. Endodontic treatment of a 36-mm long upper cuspid: clinical case report. *Rev Odonto Ciênc*. 2010;25(4):412–6.
13. Cardoso RM, Vieira TM, Limoeiro AG, Bastos H, Tomazinho LF, Albuquerque D, et al. An alternative technique to Endodontic treatment for long teeth: A case report. *J Surg Clin Dent*. 2019;17(1):8–10.

14. Venokur PC, Fink HD. Maxillary canine of unusual length. *Oral Surg Oral Med Oral Pathol.* 1976;42(1):137. doi:10.1016/0030-4220(76)90042-6.
15. Ho ESS, Chang JWW, Cheung GSP. Quality of root canal fillings using three gutta-percha obturation techniques. *Restor Dent Endod.* 2016;41(1):22–8.

**Varun Rana**, CI Spl Periodontics

**Oliver Jacob**, CI Spl Periodontics  <https://orcid.org/0000-0003-0652-3593>

**Pushpa Kumari**, CI Spl Oral And Maxillofacial Surgery  <https://orcid.org/0009-0000-4847-5855>

## Author biography

**Kiran Reddy**, Dental Officer  <https://orcid.org/0000-0002-4316-9792>

**Anita Kapri**, CI Spl Prosthodontics  <https://orcid.org/0000-0002-1784-2349>

**Cite this article:** Reddy K, Kapri A, Rana V, Jacob O, Kumari P. Root canal treatment of a rhizomegaly tooth 36 mm long right permanent maxillary canine – A case report. *IP Ann Prosthodont Restor Dent* 2024;10(1):59-62.