

Content available at: <https://www.ipinnovative.com/open-access-journals>

IP Annals of Prosthodontics and Restorative Dentistry

Journal homepage: <https://www.aprd.in/>

Case Series

Tooth avulsion and its consequences: Case series

Varun Rana¹, Anita Kapri^{2*}, Oliver Jacob³, Ebenezer Mani⁴

¹Dept. of Conservative Dentistry and Endodontics, Dental Centre INHS Kalyani, Visakhapatnam, Andhra Pradesh, India

²Dept. of Prosthodontics, Dental Centre INHS Kalyani, Visakhapatnam, Andhra Pradesh, India

³Dept. of Periodontics, Dental Centre INHS Kalyani, Visakhapatnam, Andhra Pradesh, India

⁴Dept. of Periodontics, Adhiparasakthi Dental College and Hospital, Melmaruvathur, Tamil Nadu, India



ARTICLE INFO

Article history:

Received 30-10-2023

Accepted 11-11-2023

Available online 04-12-2023

Keywords:

Avulsion

External root resorption

Replacement resorption

ABSTRACT

On an average about 30% of all school children suffer traumatic dental injury in primary dentition, whereas 22% suffer in permanent dentition. Avulsion is a serious injury which causes damage to dental and supportive tissues, ranging from 0.5-16 % among dental injuries and it mostly occurs in maxillary incisors.

Tooth avulsion can be described as the complete displacement of the entire tooth out of its alveolar socket as a result of force generated due to external injury. The accepted management of choice is immediate replantation of the tooth into its socket provided dental facilities are nearby available and if it is delayed, placement of the tooth in an appropriate storage media until dental treatment can be initiated. Replantation of avulsed incisors in children has shown successful prognosis. The replanted teeth with time may lead to ankylosis followed by inflammatory or replacement resorption, as immediate replantation is practically rare.

This case series showcases management of an avulsed maxillary left central incisor which was kept in patient oral cavity from the moment of trauma until its replantation in a eight year old boy. The avulsed tooth was replanted back into the alveolar socket after completion of endodontic treatment extra orally in same visit and splinted with composite resin. The other 2 case reports are 01 & 1.5 years follow up of replanted avulsed central incisors. During the follow up of these cases it was found that the teeth reported in these cases have remained in a stable, functional position but revealed external root resorption & replacement resorption even after completion of endodontic treatment. The amount of damage to tooth and supporting structures like bone, gingiva, emergency management and follow up period play a vital role in the prognosis of the avulsed tooth. It can be recommended to keep the avulsed tooth in saline solution as it is easily available when more appropriate storage media like HBSS are not available immediately.

This is an Open Access (OA) journal, and articles are distributed under the terms of the [Creative Commons Attribution-NonCommercial-ShareAlike 4.0 License](https://creativecommons.org/licenses/by-nc-sa/4.0/), which allows others to remix, tweak, and build upon the work non-commercially, as long as appropriate credit is given and the new creations are licensed under the identical terms.

For reprints contact: reprint@ipinnovative.com

1. Introduction

Tooth avulsion is a traumatic dental injury as a result of which either a single or multiple teeth are removed from its alveolar socket and its periodontal ligaments and neurovascular bundles sustain injury.^{1,2}

Tooth avulsion is one of the most seen cases of all traumatic injuries with 0.5% to 16% range in permanent dentition.^{3,4} It occurs most frequently between the age group of 7–14 years and most frequently involves the maxillary central incisors.⁵ Esthetic appearance and chewing function of avulsed tooth can be restored by replantation, which is a rapid treatment method. Tooth avulsion mainly occurs during sports, physical violence,

* Corresponding author.

E-mail address: a.kapri@rediffmail.com (A. Kapri).

road traffic accidents, fall and other physical impacts.^{6,7} Increased overjet and incompetent lips are also considered as etiological factors in avulsion cases.^{8,9}

Immediate replantation of the avulsed tooth provided dental treatment facilities are available nearby is the best possible management, also replantation in 20-30 min after the injury or keeping the tooth in an appropriate storage media until the patient can be seen by a dentist is also feasible option.^{10,11} Various clinical studies have concluded that the optimal replantation time for the best prognosis as 5 minutes. The healthy cell survival rate of pulp and periodontal ligament fibers starts to decrease by lack of blood supply, dryness along with bacterial contamination when the tooth is removed from its alveolar socket.^{12,13} It is very important that the innermost cell layers of the root surface should be vital for the proper regeneration of the periodontal ligament. There are various factors like pH, osmolality, and temperature of the storage medium which affects the survival of periodontal ligament cells, wet storage is the main medium to save the avulsed tooth.

When a tooth is avulsed from the socket due to tearing of the periodontal ligament it exposes the viable periodontal ligament cells present on the exposed root surface. It also results in small and localized cemental damage due to crushing of the tooth against the alveolar socket. Periodontal ligament cells which are still attached to the root surface does not dry out and are healthy, the unfavourable impact of tooth avulsion is usually minimal.¹⁴ If replantation is delayed it can result in excessive drying and the damaged periodontal ligament cells result in a severe inflammatory response over a diffuse area on the root surface. The cementoblasts cannot cover the full root surface once the tooth has been replanted, and in some locations of root surface, bone will attach directly onto the root surface. In time, through physiologic bone recontouring, the entire root will be replaced by bone which has been termed osseous replacement or replacement resorption.¹⁵

Replacement resorption has been the most common findings in cases of reimplantation following avulsion (87.2%).¹⁶ Resorption initiated after trauma can be diagnosed on radiograph after 3 weeks. In cases of external root resorption, the incidence of surface root resorption was found to be 13.3%, inflammatory root resorption as 23.2%, and replacement root resorption 51%.^{17,18} It has been found that patient parent compulsion is the reason for delayed replantation after tooth avulsion in most of the cases.¹⁹

In our first case report we have discussed the management of an avulsed maxillary central incisor which was kept in patient oral cavity from the moment of trauma until its replantation two hours later in a eight year old boy. The additional two case reports also discusses avulsion with follow up of 01 & 1.5 years showing external root resorption of the involved teeth.

2. Case Report 1

A eight year old male patient accompanied by his parents reported to dental centre with an avulsed maxillary left central incisor, tooth 21 ((Federation Dentaire Internationale numbering system) after falling in ground while playing at home (Figure 1). The accident occurred two hours ago and the avulsed maxillary left central incisor had been kept in patient oral cavity from the moment of trauma as told by his parents till the time of reporting. The patient reported to dental centre walking and seemed healthy. Glasgow comma scale (GCS) assessment rating was 15. Extra oral examination showed no soft tissue injuries, swelling, facial asymmetry or pain. On intra oral examination patient had permanent dentition, with class I skeletal and dental relationship and oral hygiene was good. To complete the examination, intra oral periapical radiographs were taken. Radiographs showed a normal socket for maxillary left central incisor (21) and non fractured root for maxillary right central incisor (11) & maxillary left lateral incisor (22) was observed (Figure 2). The crown of the avulsed tooth 21 was intact and the root had a closed apex (Figure 3). The right central and lateral incisors showed negative response to pulp vitality test (heat and cold test).

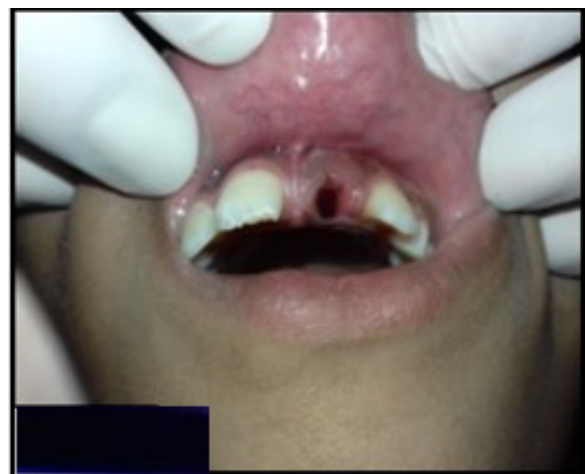


Figure 1: Intra oral photograph shows avulsion of maxillary left central incisor 21.

The condition of tooth avulsion and available treatment options was explained to the parents with the possible treatment outcome before the teeth was replanted into the socket. The treatment plan consisted of initially completing the endodontic treatment extra orally followed by immediate replantation of avulsed tooth 21 (Figure 4). Necrotic and dried remnants of the periodontal ligament tissue were carefully removed from the root surface using pumice prophylaxis. The tooth was soaked in 1.23% sodium fluoride for 20 minutes and local anesthesia was administered via buccal infiltration & an incisive canal nerve block with lignocaine 1.8% with 1:80000 epinephrine. The

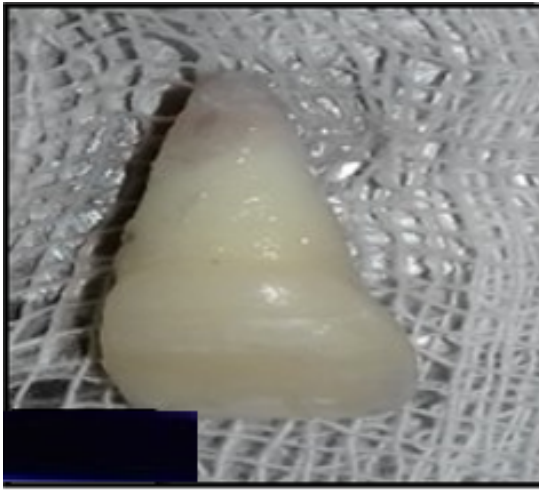


Figure 2: Avulsed tooth 21.

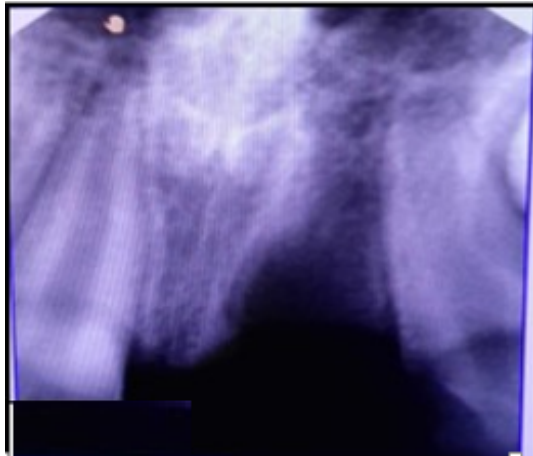


Figure 3: Intra oralperi apical radiograph.

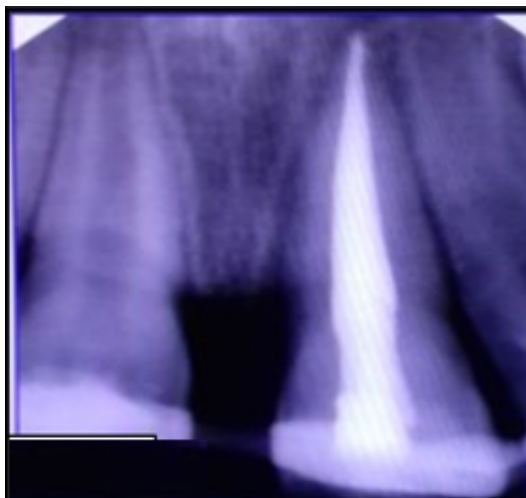


Figure 4: Post obturation radiograph.

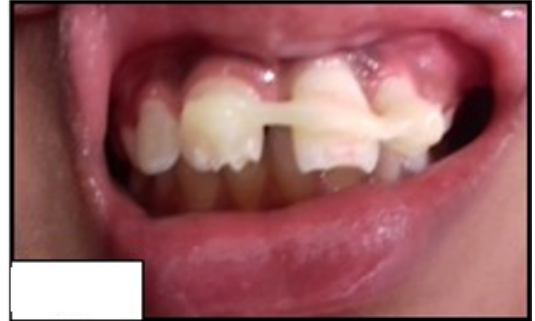

Figure 5: Splinting of the avulsed tooth with fibre reinforced composite resin.

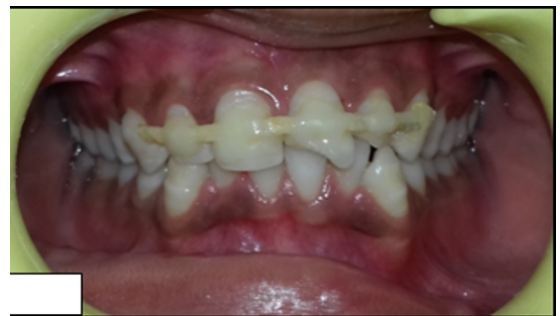

Figure 6: Intra oral frontal view shows composite splint from 13 to 23 withellis class II fracture in 21.

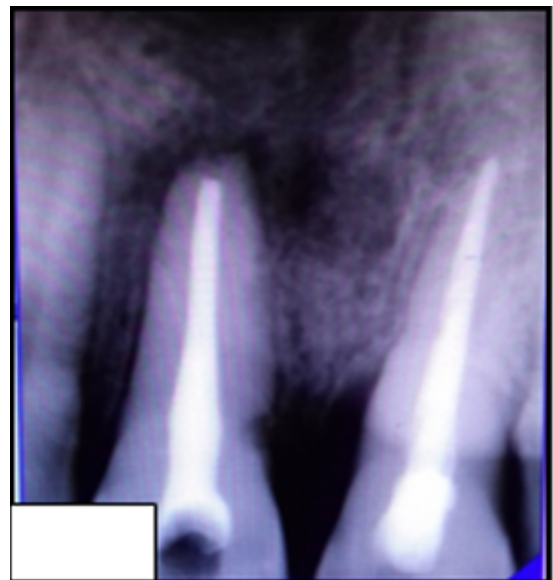

Figure 7: IOPA radiograph reveals root canal treated 11 with presence ofperi apical radiolucency & external root resorption.

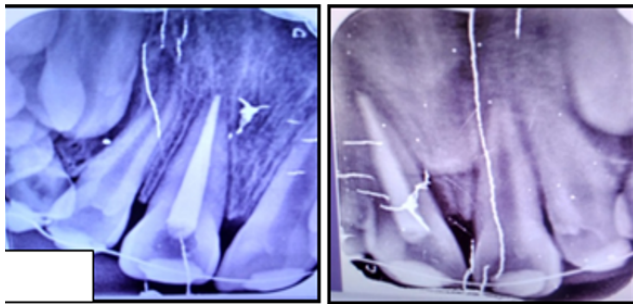


Figure 8: IOPA radiograph after obturation and replantation of 21.

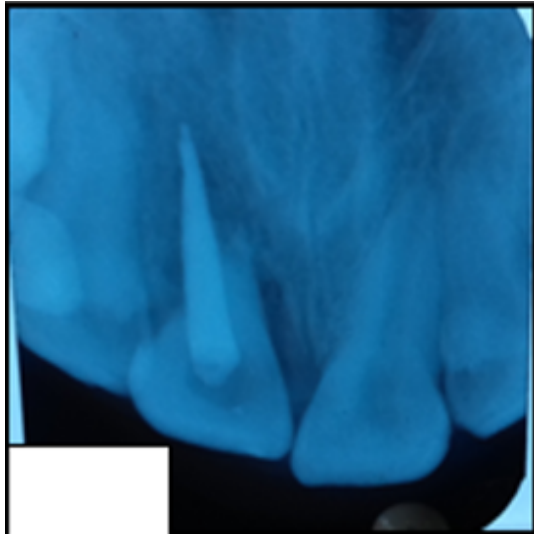


Figure 9: Radiograph shows severe root resorption with protruding gutta percha.

socket was gently rinsed with saline & when clear of the clot and debris, its walls were examined directly for the presence, absence, or collapse of the socket wall. The tooth was carefully repositioned with the help of finger pressure & splinted to the adjacent teeth with composite resin splint (Figure 5). Intra oral periapical radiograph was again taken to confirm whether the tooth has been positioned properly into the socket or not. The splint was left in place for 2 weeks.

Oral hygiene instructions both verbally and in written form along with nutritious soft diet was advised during the stabilization period to the parents. 0.2% chlorhexidine gluconate mouth rinse was prescribed for 07 days. Prophylactic antibiotics were prescribed with amoxicillin at a dose of 250 mg/day & tab ibuprofen 200 mg tds for five days and the patient was referred to the MI room for an anti tetanus serum injection.

The parents were informed about the importance of visiting the dental centre for clinical and radiographic examination so that the condition of the tooth could be evaluated after 01,06,12 months period. The patient was

reviewed after two weeks, and no clinical or radiological pathological changes were detected. The composite splint was removed at this appointment and the tooth was firm in its socket with no mobility.

3. Case Report 2

A 12 years boy accompanied by his parents reported to dental centre with chief complaint of intermittent pain in upper front region of jaw. His father gave a history of trauma after falling into the ground while riding bicycle & was provided dental treatment around one year ago in Bangalore. The parent had photographs of the previous dental treatment in his smart phone and while going through the records it was interpreted that maxillary right central incisor¹¹ had been avulsed & implanted in the socket within one hour of the trauma. On intra oral examination Ellis Class 2 fracture of maxillary left central incisor (21) was present along with pain on percussion. In maxillary right central incisor (11) there was no pain on percussion with no mobility. The composite resin splint was still intact which was applied from 13 to 23 (Figure 6). IOPA radiograph revealed endodontically treated 11 with presence of peri apical radiolucency and root resorption. The parents were explained about treatment outcome of 11 and 21. Since 11 was asymptomatic we kept it under observation and review. The composite resin splint removed. Endodontic treatment of maxillary left central incisor (21) was completed using calcium hydroxide intra canal medicament for 1 week and later obturated using No 50 gutta percha master cone & AH plus sealer (Figure 7).

4. Case Report 3

A 13 year old boy was brought for routine dental check up by his parents. They gave a history of avulsion of maxillary left central incisor (21) & getting treatment done at Lucknow. Patient father had saved photographs of the radiograph when the tooth was implanted 1.5 years ago (Figures 8 and 9). Intra orally there was no mobility, no pain on percussion, gingiva was healthy & no discoloration in 21. IOPA radiograph was taken & it revealed severe external root resorption of 21 upto middle third in mesial aspect & coronal third in distal aspect. There was complete loss of root surface in place of which healthy bone had formed which indicates it as a classical “replacement resorption” case. The parents were advised about the child developing root condition & educated for improving the overall oral hygiene.

5. Discussion

The International Association of Dental Traumatology (IADT) has come up with various guidelines which provides a detailed insights into the management of avulsion of permanent teeth.²⁰ For the treatment of avulsed permanent

teeth the most commonly accepted consensus is that the ideal treatment is immediate replantation so as to achieve better long lasting prognosis.^{21,22} However, due to various factors like presence/absence of dental centres in vicinity, parents/ guardians knowledge regarding avulsion tooth condition it is not always feasible to be carried out immediately.²³

The treatment decision regarding avulsed teeth which plays a very important factor is related to the maturity of the root apex (open or closed) and the condition of the periodontal ligament cells. The condition of periodontal ligament cells depends upon the storage medium and the time the tooth has been out of the oral cavity.^{24–26}

The extra oral time period considerably affects the outcome and has a direct association with the survival of periodontal ligament cells. Various clinical studies have stated that teeth replanted within 5 minutes after avulsion have the best prognosis in terms of survivability.²⁷ After a dry time of 60 minutes or more, all periodontal ligament cells are in non viable condition. The storage and transport media during the extra oral time also play a vital role.

In cases where prolonged extra oral time is unavoidable, the tooth should be maintained in a suitable media, such as milk, Viaspan, Hanks balanced salt solution (HBSS), saline or individual saliva, contact lens solution, Save-a-tooth (Phoenix-Lazerus Inc., Shartlesville PA, USA), and EMT Tooth saver (SmartPractice.com, Phoenix, AZ, USA) until it is replanted by a pediatric dentist or General dentist.^{28–30} The preferred storage medium recommended by The American Association of Endodontists is Hanks balanced salt solution (HBSS), because of its ability to preserve the vitality of periodontal ligament (PDL) cells for a longer duration.³¹ HBSS preserves the vitality of fibroblast cells for 72 h, but is not commonly available in MI rooms. Saline is easily available in various medical set up and can be used until the Dental Specialist starts management, but it only has a 2 h preservation time.³²

When a splint is provided to the patient it should allow physiologic tooth movement during healing and kept for a minimal period resulting in a decreased incidence of ankylosis.³³ Semi rigid (physiologic) fixation for 1 to 2 weeks is recommended. The splint should allow movement of the tooth, should have no memory (so the tooth is not moved during healing), and should not impinge on the gingival or prevent maintenance of oral hygiene in the area.

Splints can be classified as flexible, semi rigid and rigid. The use of semi rigid splint is recommended in cases of dental avulsions when no bone fracture can be detected clinically and radiographically. Various types of splints have been suggested in literature such as composite resin with orthodontic wire or nylon thread, fibre splints made

of polyethylene or Kevlar fibre mesh, orthodontic brackets bonded to the teeth with a resin based orthodontic cement and connected with a light 0.014 Nickel Titanium flexible wire, sutures or vestibular bars, titanium trauma splint.³⁴ Stomahesive (ConvaTec Inc.) is a skin barrier adhesive material and can also be used hold the teeth in its socket and cover coronal fractures to reduce sensitivity when patients are report to MI room till the time routine dental treatment can be initiated.

The avulsed tooth can maintain aesthetic and functional properties for some years after the replantation. Panzarini et al. in their study concluded that when there are no periodontal ligament remnants and root contamination is under control, replacement resorption and ankylosis are the best results followed. Although these events will end up leading to tooth loss, this will happen slowly with out any loss of alveolar ridge height which is considered an important factor for future prosthesis planning.^{35,36} Hence, in our second & third case report, a uniform bone preservation is expected before extraction of the intact crown if in future it becomes mobile favoring the prosthodontic replacements.

Educational efforts should be made to increase awareness by means of delivering lectures, chair side demonstrations and Save a tooth posters so as to emphasize the parents, school teachers, dental surgeons, general practitioners in the emergency room and Medical Assistants regarding the primary management of tooth and if possible to perform reimplantation procedure which will result in improvement of the long term prognosis of an avulsed tooth.^{37,38}

6. Conclusion

Avulsion of tooth is considered to be one of the most serious oro facial dental injuries which affects esthetics, has psychological and functional consequences on an individual and the prognosis is mainly correlated with the amount of injury to periodontal ligament.

On a community level knowledge should be provided related to the emergency management of tooth avulsion. This can be done by conducting a variety of education programs such as lectures, videos & posters in various schools and dental centres. According to the findings of the presented cases, intentional replantation can be advised for management of avulsed tooth with prolonged extra oral time, however the risk of root resorption in future should also be considered.

7. Source of Funding

None.

8. Conflict of Interest

None.

References

- Stockwell AJ. Incidence of dental trauma in the Western Australian School Dental Service. *Community Dent Oral Epidemiol.* 1988;16(5):294–8.
- Kaba AS, Marechaux SC. A fourteen-year follow-up study of traumatic injuries to the permanent dentition. *ASDC J Dent Child.* 1989;56(6):417–25.
- Glendor U, Halling A, Andersson L, Eilert-Petersson E. Incidence of traumatic tooth injuries in children and adolescents in the county of Västmanland, Sweden. *Swed Dent J.* 1996;20(1-2):15–28.
- Andreasen JO, Andreasen FM, Tsilingaridis G. Avulsions. In: Andreasen J, Andreasen F, Andersson L, editors. Textbook and color atlas of traumatic injuries to the teeth. vol. 2019. Oxford: Wiley Blackwell; 2018. p. 486–520.
- Bastone EB, Freer TJ, Mcnamara JR. Epidemiology of dental trauma: a review of the literature. *Aust Dent J.* 2000;45(1):2–9.
- Stockwell AJ. Incidence of dental trauma in the Western Australian School Dental Service. *Community Dent Oral Epidemiol.* 1988;16(5):294–8.
- Onetto JE, Flores MT, Garbarino ML. Dental trauma in children and adolescents in Valparaiso, Chile. *Endod Dent Traumatol.* 1994;10(5):223–7.
- Andreasen JO, Andreasen FM. Examination and diagnosis of dental injuries. In: Andreasen J, Andreasen FM, editors. Textbook and Color Atlas of Traumatic Injuries to the Teeth. Copenhagen, Denmark: Mosby; 1994. p. 195–217.
- Kaba AD, Marechaux SC. A fourteen-year follow-up study of traumatic injuries to the permanent dentition. *ASDC J Dent Child.* 1989;56(6):417–25.
- Andreasen JO, Andreasen FM. Textbook and color atlas of traumatic injuries to the teeth, 3rd edn. Copenhagen/St. Louis: Munksgaard/CV Mosby; 1994.
- Andreasen JO, Kristersson L. The effect of limited drying or removal of the periodontal ligament: periodontal healing after replantation of mature permanent incisors in monkeys. *Acta Odontol Scand.* 1981;39(1):1–13.
- Andreasen JO. The effect of extra-alveolar period and storage media upon periodontal and pulpal healing after replantation of mature permanent incisors in monkeys. *Int J Oral Surg.* 1981;10(1):43–51.
- Soder PO, Otteskog P, Andreasen JO, Modeer T. Effect of drying on viability of periodontal membrane. *Scand J Dent Res.* 1977;85(3):164–8.
- Andreasen JO. Effect of extra-alveolar period and storage media upon periodontal and pulpal healing after replantation of mature permanent incisors in monkeys. *Int J Oral Surg.* 1981;10(1):43–53.
- Soder PO, Otteskog P, Andreasen JO, Modeer T. Effect of drying on viability of periodontal membrane. *Scand J Dent Res.* 1977;85(3):164–8.
- Andreasen JO, Hjørtting-Hansen E. Replantation of teeth. Radiographic and clinical study of 110 human teeth replanted after accidental loss. *Acta Odontol Scand.* 1966;24(3):263–86.
- Trope M. Root resorption of dental and traumatic origin: classification based on etiology. *Pract Periodontics Aesthet Dent.* 1998;10(4):515–22.
- Soares AJ, Souza GA, Pereira AC, Vargas-Neto J, Zaia AA, Silva E, et al. Frequency of root resorption following trauma to permanent teeth. *J Oral Sci.* 2015;57(2):73–8.
- Souza BDM, Dutra KL, Kuntze MM, Bortoluzzi EA, Flores-Mir C, Reyes-Carmona J, et al. Incidence of root resorption after the replantation of avulsed teeth: A meta-analysis. *J Endod.* 2018;44(8):1216–27.
- Andersson L, Andreasen JO, Day P, Heithersay G, Trope M, Diangelis AJ, et al. International association of dental traumatology guidelines for the management of traumatic dental injuries: 2. Avulsion of permanent teeth. *Dent Traumatol.* 2012;28(2):88–96.
- Ram D, Cohenca ON. Therapeutic protocols for avulsed permanent teeth: review and clinical update. *Pediatr Dent.* 2004;26(3):251–5.
- Trope M. Avulsion of permanent teeth: theory to practice. *Dent Traumatol.* 2011;27(4):281–94.
- Santos M, Habecost A, Gomes FV, Weber JBB, De Oliveira M. Parent and caretaker knowledge about avulsion of permanent teeth. *Dent Traumatol.* 2009;25(2):203–8.
- Cvek M, Cleaton-Jones P, Austin J, Lownie J, Kling M, Fatti P, et al. Effect of topical application of doxycycline on pulp revascularization and periodontal healing in reimplanted monkey incisors. *Endod Dent Traumatol.* 1990;6(4):170–6.
- Andreasen JO, Borum MK, Andreasen FM. Replantation of 400 avulsed permanent incisors. 3. Factors related to root growth. *Endod Dent Traumatol.* 1995;11(2):69–75.
- Barrett EJ, Kenny DJ. Avulsed permanent teeth: a review of the literature and treatment guidelines. *Endod Dent Traumatol.* 1997;13(4):153–63.
- Pohl Y, Filippi A, Kirschner H. Results after replantation of avulsed permanent teeth. II. Periodontal healing and the role of physiologic storage and anti resorptive regenerative therapy. *Dent Traumatol.* 2005;21(2):93–101.
- Lee W. Viability of human periodontal ligament fibroblasts after storage in Save-A-Tooth, EMT tooth saver and Hank's Balanced Salt Solution. Marquette University; 2016. Available from: https://publications.marquette.edu/theses_open/362/.
- Nam O, Ro ST, Lee HW, Jeong J, Chae YK, Lee KE, et al. Evaluation of delphinidin as a storage medium for avulsed teeth. 2023;23(1):21. Available from: <https://doi.org/10.1186/s12903-023-02713-9>. doi:10.1186/s12903-023-02713-9.
- Brier ND, Dorien O, Borra V, Singletary EM, Zideman DA, Buck E, et al. Storage of an avulsed tooth prior to replantation: A systematic review and meta-analysis. *Dent Traumatol.* 2020;36(5):453–76.
- Zhang N, Cheng Y, Li F, Kang Q. Network Meta-Analysis of 10 Storage Mediums for Preserving Avulsed Teeth. *Front Med (Lausanne).* 2021;8:749278. doi:10.3389/fmed.2021.749278.
- Nam OH, Oh TJ, Lee JH, Hwang YS, Choi SC. Differential gene expression profiles of human periodontal ligament cells preserved in Hank's balanced salt solution and milk. *Dent Traumatol.* 2020;36(1):58–68.
- Kahler B, Hu JY, Marriot-Smith CS, Heithersay GS. Splinting of teeth following trauma: a review and a new splinting recommendation. *Aust Dent J.* 2016;61(1):59–73.
- Arx T, Filippi A, Buser D. Splinting of traumatized teeth with a new device: TTS (titanium trauma splint). *Dent Traumatol.* 2001;17(4):180–4.
- Vilela A, Soares PBF, Versluis A, Soares CJ. Dental trauma splints for the mixed dentition - A finite element analysis of splint material, splint extension, missing teeth, and PDL representation. *Dent Traumatol.* 2022;38(6):495–504.
- Panzarini SR, Gulinelli JL, Poi WR, Sonoda CK, Pedrini D, Brandini DA, et al. Treatment of root surface in delayed tooth replantation: A review of literature. *Dent Traumatol.* 2008;24(3):277–82.
- Zadik Y, Marom Y, Levin L. Dental practitioners knowledge and implementation of the 2007 International Association of Dental Traumatology guidelines for management of dental trauma. *Dent Traumatol.* 2009;25(5):490–3.
- Jorge KO, Ramos-Jorge ML, De Toledo F, Alves LC, Paiva SM, Zarzar PM, et al. Knowledge of teachers and students in physical education's faculties regarding first-aid measures for tooth avulsion and replantation. *Dent Traumatol.* 2009;25(5):494–9.

Author biography

Varun Rana, Classified Specialist Endodontist

Anita Kapri, Classified Specialist Prosthodontics
 <https://orcid.org/0000-0002-1784-2349>

Oliver Jacob, Graded Specialist Periodontist

Ebenezer Mani, Associate Professor
Periodontist  <https://orcid.org/0000-0001-8945-9376>

Cite this article: Rana V, Kapri A, Jacob O, Mani E. Tooth avulsion and its consequences: Case series. *IP Ann Prosthodont Restor Dent* 2023;9(4):262-268.