

Content available at: <https://www.ipinnovative.com/open-access-journals>

IP Annals of Prosthodontics and Restorative Dentistry

Journal homepage: <https://www.aprd.in/>

## Case Report

# Full mouth prosthetic rehabilitation using hobo's philosophy: A case report

Rahul Patil<sup>1,\*</sup>

<sup>1</sup>Dept. of Prosthodontics, Emirates Health Services, UAE



### ARTICLE INFO

#### Article history:

Received 05-06-2023

Accepted 29-08-2023

Available online 10-10-2023

#### Keywords:

Hobo

Occlusal wear

TMJ

Vertical dimension

Anterior guidance

### ABSTRACT

The face, which is the part of the body that is most exposed, has the mouth as a prominent feature. The allure of the teeth draws all eyes. Some patients with collapsed bites were required to have all of their teeth extracted and replaced with traditional complete dentures because rehabilitation techniques' efficacy was questioned in the 20th century. The occlusal surfaces of a patient's teeth will gradually deteriorate over the course of their lifetime. But excessive occlusal wear can result in pulpal injury, occlusal discord, functional impairment, and aesthetic deformity. Thanks to improvements in dental technology, equipment, and materials over the last millennium, the task of restoring and rehabilitating the damaged dentition has gotten simpler. This has given restorative dentists the ability to maintain teeth and associated structures. Establishing optimal oral health should be the main objective of all rehabilitation procedures because maintaining oral health and safeguarding the stomatognathic system will always be the end goal. The report's case study serves as an illustration of Hobos' full mouth rehabilitation technique.

This is an Open Access (OA) journal, and articles are distributed under the terms of the [Creative Commons Attribution-NonCommercial-ShareAlike 4.0 License](https://creativecommons.org/licenses/by-nc-sa/4.0/), which allows others to remix, tweak, and build upon the work non-commercially, as long as appropriate credit is given and the new creations are licensed under the identical terms.

For reprints contact: [reprint@ipinnovative.com](mailto:reprint@ipinnovative.com)

## 1. Introduction

A truly wonderful aspect of prosthodontists is their capacity to transform lives through comprehensive oral care. The prosthodontists' ability to comprehend the patient's main concerns and desires, as well as all the dental and medical implications related to the treatment, presents a challenge along with the patient benefit. Patients who have experienced severe dental wear frequently exhibit a severely damaged dentition.<sup>1</sup> The majority of the time, tooth emergence and alveolar bone development maintain the Vertical Dimension of Occlusion (VDO). As teeth deteriorate, the alveolar bone goes through an adaptive process to make up for the lost tooth structure and preserve the VDO. Nevertheless, depending on the cause of the wear, occlusal wear may happen more quickly than continuous eruption. This calls for cautious manipulation of the VDO.

The destruction of the restorations or of the teeth themselves frequently occurs when the VDO in bruxers is increased, placing a severe overload on the teeth. Various factors may combine to produce worn out dentition and the etiology often remains unidentified.<sup>2</sup>

Rehabilitation of patients with collapsed bite is becoming crucial, both from a restorative and preventive point of view. Comprehensive treatment planning along with assessment of correct occlusal dimensions are essential part of full mouth rehabilitation.

Turner and Missirlian (1984) classified the patients requiring full mouth rehabilitation into three categories:

1. Excessive occlusal wear with loss of vertical dimension, but with space available to restore the vertical height
2. Excessive wear without loss of vertical dimension of occlusion but space available for restoration.
3. Excessive wear without loss of vertical dimension of occlusion but with limited space.<sup>3</sup>

\* Corresponding author.

E-mail address: [dr.rahulp13584@gmail.com](mailto:dr.rahulp13584@gmail.com) (R. Patil).

The goals to be attained for full mouth rehabilitation are as follows:-

1. Liberation from disease in all the masticatory and associated structures
2. Maintainable healthy periodontium
3. Stable TMJs
4. Stable occlusion
5. Maintainable healthy teeth
6. Comfortable function
7. Optimum esthetics

However, the recent concept of rehabilitating the teeth began with the idea of bite raising to rectify the cases with collapsed bite caused due to excessive wear but compensated vertical dimension. As long as the occlusal stability is solidly established, a moderate increase in the VDO does not appear to be a risky procedure. Without some increase in VDO, it is not always possible to restore a worn occlusion. As a result, the vertical dimension has to be raised to make room for the restorative material.<sup>4</sup>

Full-mouth rehabilitations can be conducted using a variety of popular occlusal philosophies and concepts, including the Gnathological concept, Pankey Mann-Schuyler concept,<sup>5</sup> Hobo's concept,<sup>6,7</sup> Biological occlusion concept, Youdeli's concept,<sup>8</sup> and Nyman and Lindhe concept. The twin-stage technique has become popular among clinicians due to its many benefits.<sup>9–13</sup>

The following case report elaborates the use of the Hobo's twin-stage procedure for rehabilitation of a patient with severe generalized occlusal wear.

## 2. Case Report

A 69-year-old male patient reported having difficulty chewing, some teeth that were thermally sensitive, and gradually shortening teeth as his main complaints. The patient provided no pertinent medical history and denied having any symptoms of myofascial pain dysfunction or temporomandibular joint disorder.

### 2.1. Extraoral examination

Without any obvious facial asymmetry, the patient's face was bilaterally symmetrical. There were no pathological symptoms found during the examination of the masticatory muscles or the TMJ. Movements of the mandible fell within the range of typical motions.

### 2.2. Intraoral examination

A clinical examination showed widespread tooth wear. The teeth 23, 42, 43, 44, and 32,33,34,35 (FDI notation) exhibited excessive occlusal wear and thermal sensitivity. Teeth 31,41 were remaining roots and not restorable (Figures 1 and 2). A soft tissue examination revealed no

pathology or inflammation. Due to the loss of the vertical tooth stop in the lower anterior region as well as the loss of anterior guidance, there was over eruption of maxillary anterior teeth (Figure 3). Loss of intercuspation and a discrepancy between *Centric Relation (CR)*, *Maximum Intercuspal Position (MIP)* were discovered during an occlusal examination of the present condition. The patient's orthopantomogram (OPG) provided additional confirmation of these results. A multiphase treatment protocol was planned as follows:

#### 2.2.1. Counselling and prophylaxis

The first stage started with patient education about his current oral condition and what will be the goals of his dental. Counseling for mental health was provided. Pre-treatment records were gathered along with a thorough oral evaluation. The patient received periodontal prophylaxis, maintenance, and oral hygiene advice, including instructions on how to properly brush his teeth.

#### 2.2.2. Diagnostic procedures

Clinical evaluation was done on the vertical dimension. The patient fit into category Class I of Turner and Missirlan's classification of occlusal vertical dimension and tooth wear—which says excessive wear with loss of vertical dimension but with room available to restore the vertical height.

Facial measurements were used to determine the physiologic rest position, and phonetics was used to confirm it. The occlusal vertical dimension could be restored by increasing the interocclusal distance by about 2 mm. Diagnostic casts were made. According to Hobo's philosophy, the lower cast was divided into 3 segments/parts. The mandible was guided into CR by the bimanual manipulation technique. Bite registration was completed using a customized anterior de-programming device (impression compound) and interocclusal bite registration was done using PVS material which was injected on bilateral the posterior teeth. Casts for the upper and lower teeth were mounted on a semi-adjustable articulator using this interocclusal record and face bow transfer. (Figure 4)

#### 2.2.3. Pre prosthetic phase

Turner's category -1 excessive tooth wear with loss of VD states that the patient should receive a removable splint for 6–8 weeks with increased VD, followed by a fixed provisional restoration for 2–3 weeks, before planning permanent restorations.

31, 41 unrestorable teeth were removed. The extraction sites were given time to fully recover before beginning restorative therapy. For teeth 23,32,33,34,35,43,44, endodontic treatment was performed because there was a chance that the pulp would be exposed during tooth

preparation. Additionally, teeth 23, 32, and 42 were restored using a post and core.

#### 2.2.4. Hobo's twin-stage procedure

Two stages of diagnostic wax-up were performed on mounted casts (conditions). When eccentric movements were performed on the wax up of the occlusal morphology under Condition 1, the lower anterior teeth presented a barrier. The anterior portion of the mandibular working cast was made removable in accordance with Hobo's philosophy using dowel pins (Figures 5, 6 and 7). The articulator was calibrated using the values shown in the table 1. To achieve smooth gliding contacts from the CR to protrusive and lateral movements, the lower segment was removed, and wax up was completed for all posterior teeth (Figures 8 and 9). When the anterior guidance is established later, this would guarantee an equal amount of posterior disocclusion during lateral and protrusive excursions. Under condition 1, the typical cusp angle ( $25^{\circ}$ ) was developed on the wax-up without the anterior segment. The lateral wing of the incisal table was adjusted to  $10^{\circ}$ .

It is recommended that the condylar path be adjusted to  $40^{\circ}$  and the anterior guide table be adjusted to  $45^{\circ}$  with lateral wing  $20^{\circ}$  to incorporate the anterior guidance. This was the adjustment value for the articulator to achieve Condition 2.

Anterior segment was placed back on the casts and wax-up was completed to achieve proper tooth contour. Palatal contours were adjusted according to the anterior guidance to provide immediate disocclusion away from CR (Figures 10 and 11).

### 3. Prosthetic Phase

Following the completion of all pre-prosthetic procedures, simultaneous maxillary and mandibular tooth preparation was performed. The desired occlusal clearance for final PFM restorations was determined. Gingival retraction was done (Figures 12 and 13). Using polyvinyl siloxane impression material and the double-mix, two-stage putty wash impression technique, a final full-arch impression of the prepared teeth was created, after which casts were made in die stone. On the finished casts, individual die preparation of prepared teeth was carried out (Figure 14).

Temporary restorations were made from acrylic resin and were split in three segments per arch, one anterior and two bilateral posteriors. An index created from the diagnostic wax-up was used to fabricate the temporary restorations. To achieve the desired occlusion in antero-posterior and lateral excursions, the necessary occlusal adjustments were made in the provisional restorations before these restorations were lute with temporary luting cement (Figure 15).

Utilizing a centric interocclusal record at a previously established restored vertical dimension, the final casts with individual dies were mounted on a semi-adjustable

articulator. Lower anterior teeth's dies were pulled out of the cast while the articulator was set to condition 1. For bilateral upper and lower posterior restorations, individual wax pattern was created on the individual dies. Wax copings were used to create metal copings (Figure 16). To check the fit, occlusal space for ceramic, and marginal integrity, a metal try-in was performed. Before examining the bisque trial, the anterior Provisionals were removed. Corrections were made as necessary to achieve a sufficient group function occlusion (Figure 17).

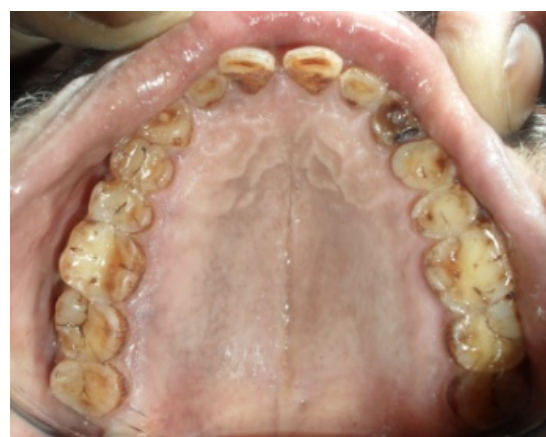Crowns were put back on the cast after checking excursive movements intraorally for posterior restorations. To fabricate final anterior restorations, the articulator was set to condition 2 with anterior dies re-placed on the cast. The anterior crowns were fabricated in such a way that a canine-guided disocclusion in lateral excursions and a standard amount of posterior disocclusion during protrusion was achieved (Figure 20). Intraorally, occlusal adjustments and equilibration were performed. The final crowns were then re-glazed and lute with permanent luting cement (Figures 18 and 19). Post treatment instructions were provided.

### 4. Maintenance Phase

To protect the restorations, a maxillary night guard was fabricated (thermoplastic sheet). The patient was scheduled to return for post insertion recalls and instructed to adhere to his daily night guard regimen.

**Table 1:**

Condition	Condylar path		Anterior guide table	
	Sagittal inclination	Bennett angle	Sagittal inclination	Lateral wing angle
Condition 1	25	15	25	10
Condition 2	40	15	45	20



**Fig. 1:** Pre operative maxillary occlusal

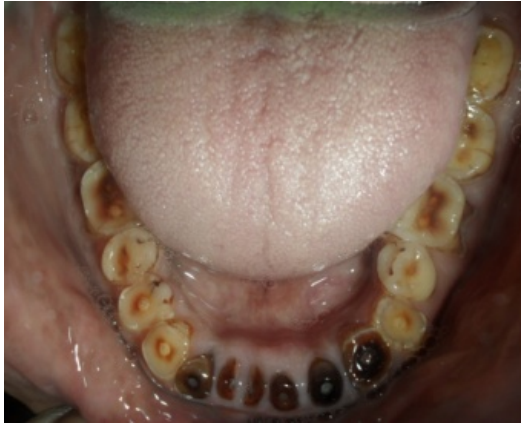

Fig. 2: Pre operative mandibular occlusal




Fig. 5: Condylar guidance set to condition 1 - 25°

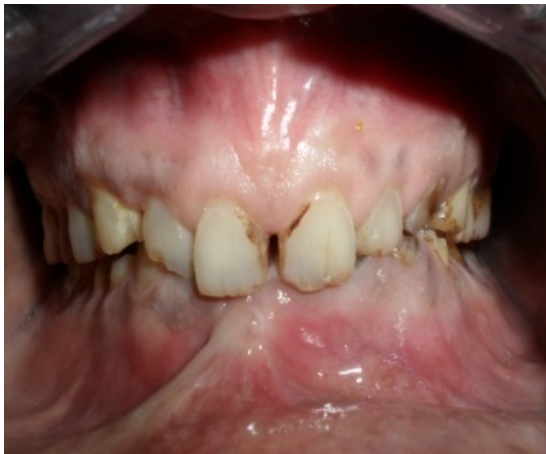

Fig. 3: Pre operative frontal showing over eruption of maxillary incisors



Fig. 6: Anterior guide table set to condition 1- 25°

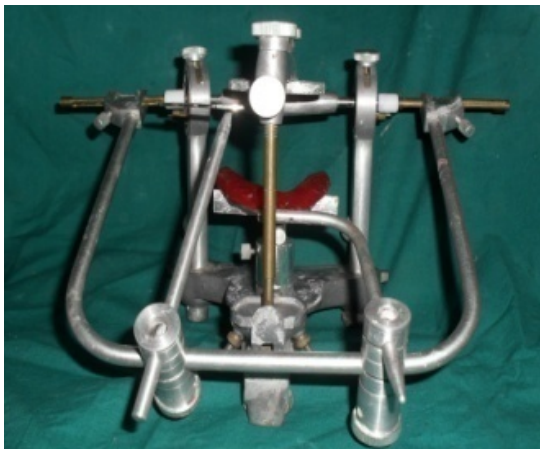
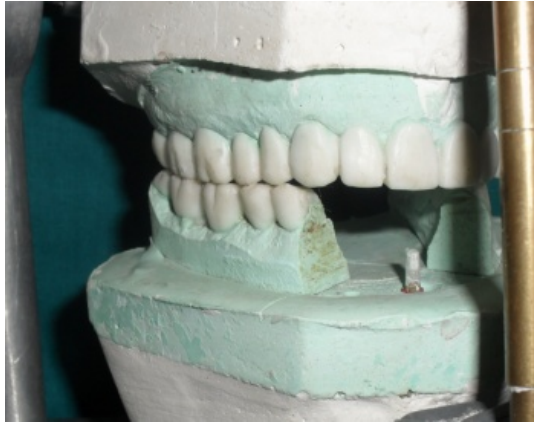
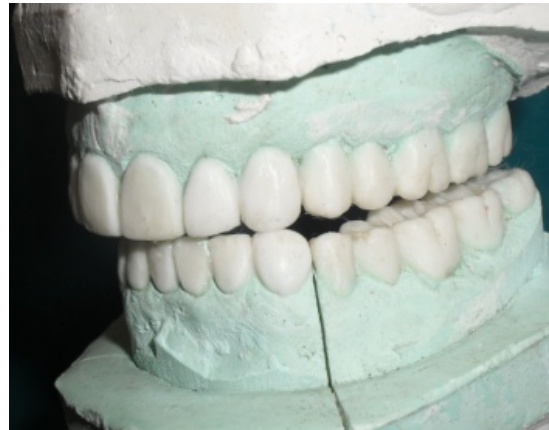Fig. 4: Diagnostic face bow transfer



Fig. 7: Lateral wing set to condition 1- 10°



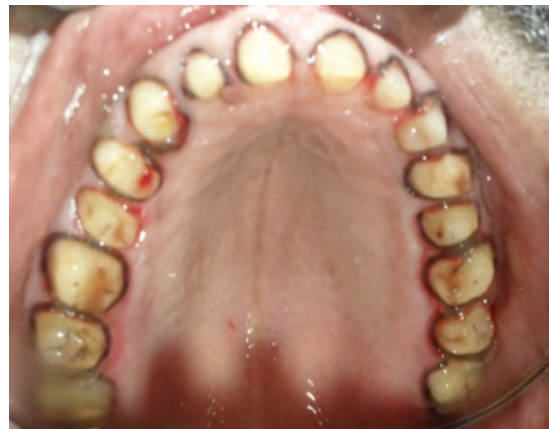**Fig. 8:** Wax up posterior teeth-right



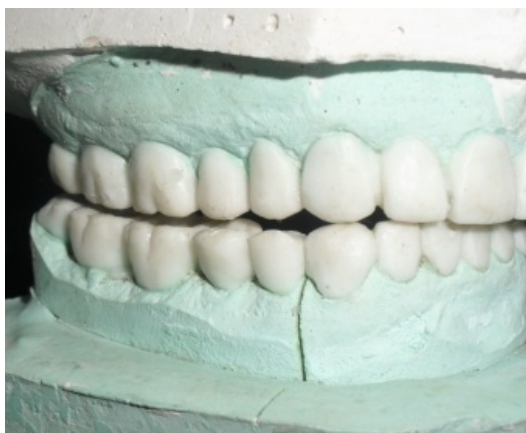**Fig. 11:** Disocclusion in lateral excursions -left



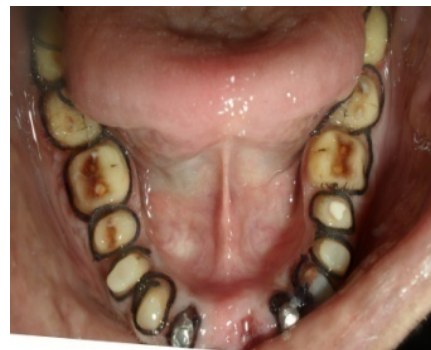**Fig. 9:** Wax up posterior teeth-left



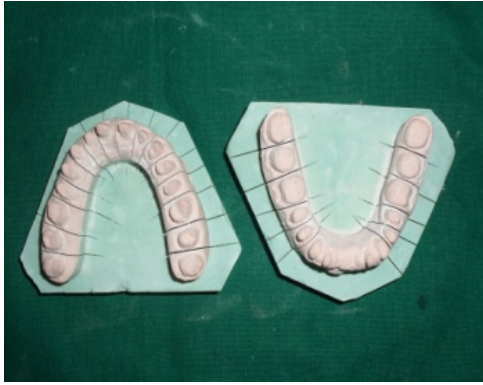**Fig. 12:** Tooth preparation with retraction-maxillary



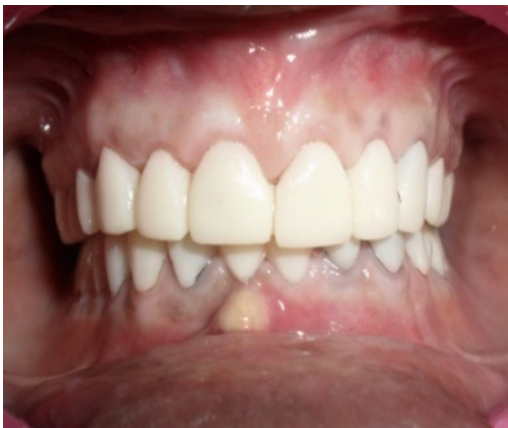**Fig. 10:** Disocclusion in lateral excursions -right



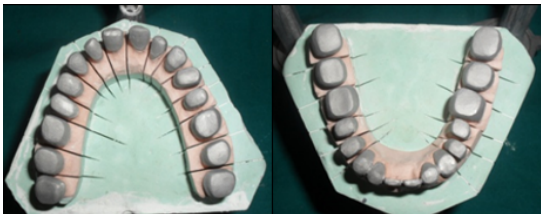
**Fig. 13:** Tooth preparation with retraction-mandibular



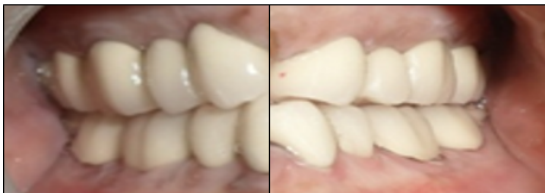**Fig. 14:** Final casts with individual die



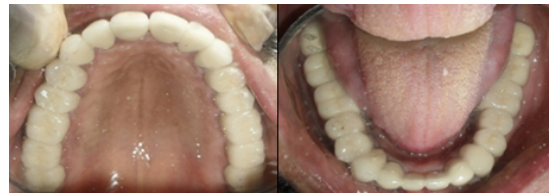**Fig. 15:** Acrylic provisional restorations



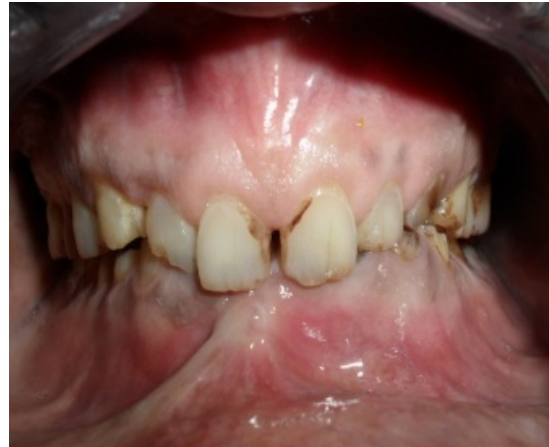**Fig. 16:** Individual metal copings



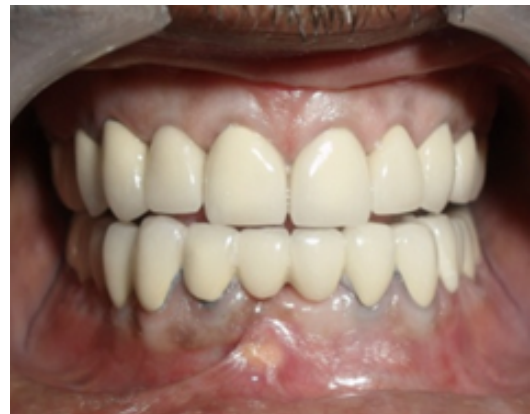**Fig. 17:** Group function occlusion – right & left



**Fig. 18:** Final PFM crowns - maxillary and mandibular



**Fig. 19:** Pre and post operative



**Fig. 20:** Posterior disocclusion in protrusion

## 5. Discussion

Occlusal rehabilitation deals with the restoration of functional integrity of dental arches by the use of inlays, crowns, FPDs and/or partial dentures. The primary objective of full mouth rehabilitation is preservation of oral health, restoring function, achieving aesthetics and patient comfort.<sup>14</sup>

Since the condylar path did not alter during adulthood and the choice of anterior guidance remained solely at the dentist's discretion, it was previously the primary focus of attention for gnathologists. As a result, we regarded the condylar path and anterior guidance as separate

variables. According to Dawson, the condylar path is not a factor in determining anterior guidance, and regardless of whether the anterior path is flat, curved, concave, convex, or parabolic, the lower anterior teeth can follow any number of path variations without being hindered by the rotating condyle sliding down the unchanged condylar path. While in the Pankey mann Schuyler philosophy the restoration of the posterior teeth comes first, followed by the establishment of anterior guidance. Functional generated path technique is used to assist waxing of upper posterior restorations but movement of teeth while making FGP compromised the registration. Area of freedom between centric relation and intercuspal position was also present.<sup>15</sup>

The integrity of the entire stomatognathic system would be preserved by keeping teeth out of contact with one another during excursions, resulting in a long-lasting, functional restoration, in addition to aesthetics and comfort.<sup>16</sup>

As was stated by D'Amico, cuspid protected occlusions and disocclusions were natural adaptations which were used for preventing destructive occlusions.<sup>17</sup>

Condylar guidance and anterior guidance are regarded as the main factors that affect occlusal rehabilitations, according to the literature. Hobo and Takayama investigated how the condylar path, incisal path, and cusp angle affected the degree of disocclusion and concluded that the cusp angle was the most accurate indicator of occlusion. Their research concluded that these two factors were interdependent and showed how anterior guidance affected the working condylar path. Hobo adopted the concept of posterior disocclusion and gave the Twin-tables Technique. According to him, posterior disocclusion depends on the inclination and shape of the posterior cusps, which aid in reducing harmful lateral forces, and the angle of hinge rotation caused by the angle between the anterior guidance and condylar path. Molar disocclusion was achieved using this method by use of two incisal tables.

To create restorations for posterior teeth, the first incisal guide table, also known as the incisal table without disocclusion, was employed. To achieve incisal guidance with posterior disocclusion, the second incisal table, also known as the incisal table with disocclusion, was used. The disadvantage of this idea is that it causes the patient more discomfort because the incisal table must be set at an excessively steep angle due to the excessively steep cusp angle. Furthermore, because the anterior guide table was made by resin, the technique is delicate. Additionally, the Twin-Stage Procedure was created as the upgraded Twin-Table method.

Similar to Schuyler, they noted that anterior guidance and condylar guidance were dependent factors rather than independent ones.<sup>18</sup> Instead of adhering to the PMS philosophy, which states that group function is achieved on the working side, they believed in posterior disocclusion

in eccentric movements. There was no Freedom in centric. Condylar path was not required to be recorded during the twin-stage procedure because cusp angle served as the primary indicator of occlusion. They concluded that cusp angle should be used as the most accurate indicator of occlusion because it does not vary and is four times more accurate than the condylar and incisal paths. A standard value for cusp angle was established, independent of condylar path and incisal path, so that it may account for natural teeth wear brought on by caries, abrasion, and restorative work. It was possible to establish the desired standard cusp angle by eliminating the need for difficult instruments like the pantograph and fully adjustable articulators.

With eccentric movements at a 3-mm protrusion from centric relation, the twin-stage procedure assists in achieving a standard disocclusion of 1.1 mm on protrusion,

1 mm on the nonworking side and 0.5 mm on the working side. However, disocclusion increases if the patient's sagittal condylar path is steeper than the articulator adjustment values (40°). The degree of obstruction decreases if the path is less than 40 degrees. Cusp interferences will happen if the patient's sagittal condylar inclination is less than 16°. Patients complain of discomfort if the incisal path is more than 5° steeper than the condylar path.<sup>6,7</sup>

The posterior cusp morphology was contoured according to standard values established by the inventor of the twin stage technique in the restoration of the aforesaid case using a group function occlusal scheme.

In order to avoid interference during protrusive and latero-trusive movements, anterior guidance was later established in accordance with standard values. Overall, in this type of group function occlusion scheme, the upper and lower posteriors on the working side work together as a unit simultaneously dis-occluding the posteriors on the contralateral nonworking side, hence preventing lateral stresses. This satisfies the criteria for an ideal occlusion, which is necessary for the stomatognathic system to function in harmony.

A fully adjustable articulator is not necessary for the twin stage procedure because it is a fairly simple procedure. It can be used in a range of restorative procedures, including single crowns, fixed prosthodontics, full mouth rehabilitation, complete dentures, and implants.<sup>19</sup>

Contraindications of this procedure are:<sup>20</sup>

1. Abnormal curve of Spee
2. Abnormal curve of Wilson
3. Abnormally rotated tooth
4. Abnormally inclined tooth

## 6. Conclusion

The ideal occlusal form and function must be restored as the primary goal of full mouth rehabilitation. A correct

diagnosis, meticulous planning, and a multidisciplinary approach to treatment are essential for success. When eccentric movements are involved, using the standard cusp angle as the main factor in occlusion yields a more predictable disocclusion. This approach replicates anterior guidance and disocclusion more precisely and scientifically. It helps to stop damaging forces from acting on the teeth and their supporting structures, restoring the patient's ideal oral health in the process.

The uniqueness of this case report and Hobo's technique comes from the fact that the final full mouth prosthesis was fully cemented in a single appointment. The treatment significantly enhanced the patient's mastication and appearance. The patient was ecstatic with the treatment.

## 7. Abbreviation

VDO-vertical dimension of occlusion, CR-centric relation, MIP-maximum intercuspal position, PVS- polyvinyl siloxane, PFM-porcelain fused to metal, TMJ- temporomandibular joint.

## 8. Conflict of Interest

There are no conflicts of interest in this article.

## 9. Source of Funding

None.

## References

- Dawson PE. Functional Occlusion - From TMJ to smile design. 1st edn. Mosby; 2008. p. 430–52.
- Crothers AJ. Tooth wear and facial morphology. *J Dent.* 1992;20(6):333–41.
- Turner KA, Missirlan DM. Restoration of the extremely worn dentition. *J Prosthet Dent.* 1984;52(4):467–74.
- Sadish M, Prasanna PP. Full Mouth Rehabilitation Using Hobos Twin Stage Procedure- A Case Report. *IOSR -J Dent Med Sci.* 2019;18(8):35–40.
- Mann AW, Pankey LD. Concepts of Occlusion: The P.M. Philosophy of Occlusal Rehabilitation. *Dent Clin North Am.* 1963;7(3):621–36.
- Hobo S. Twin-tables technique for occlusal rehabilitation: Part I- Mechanism of anterior guidance. *J Prosthet Dent.* 1991;66(3):299–303.
- Hobo S. Twin-tables technique for occlusal rehabilitation: Part II Clinical procedures. *J Prosthet Dent.* 1991;66(4):471–7.
- Schluger S, Youdelis RA, Page RC. Diseases of the periodontium. In: and others, editor. Periodontal Disease. Philadelphia: Lea & Febiger; 1971. p. 53–71.
- Shetty M, Joshi N, Prasad DK, Sood S. Complete Rehabilitation of a Patient with Occlusal Wear: A Case Report. *J Indian Prosthodont Soc.* 2012;12(3):191–7.
- Gupta T, Banerjee A, Banerjee S, Chakraborty N, Singh R. Full mouth rehabilitation of a patient with severe attrition using Hobo twin-stage procedure. *Int J Prosthodont Restor Dent.* 2011;1(3):177–81.
- Kumar SA, Radhakrishnan V, Sandhu HS, Sahoo NK. Full mouth rehabilitation of a case of rampant caries using a twin-stage procedure. *Med J Armed Forces India.* 2015;71(Suppl 2):429–34.
- Verma K, Gowda EM, Kalra A, Verma R. Full mouth rehabilitation using twin-stage procedure-a case report. *Ann Dent Spec.* 2015;3(3):89–92.
- Shetty BR, Shetty M. Philosophies in Full Mouth Rehabilitation- A Systematic Review. *Int J Dent Case Rep.* 2013;3(3):30–9.
- Dawson P. A systematic and integrated approach is required for a prognosis that is favourable and predictable Dawson P. Functional occlusion from TMJ to smile design. In: Functional occlusion from TMJ to smile design. vol. 7. Mosby, St. Louis.; 2007. p. 49.
- Mann AW, Pankey LD. Oral rehabilitation. Part I. Use of P-M instrument in treatment planning and in restoring the lower posterior teeth. *J Prosthet Dent.* 1960;10:151–62.
- Tiwari B, Ladha K, Lalit A, Naik BD. Occlusal concepts in full mouth rehabilitation: an overview. *J Indian Prosthodont Soc.* 2014;14(4):344–51.
- Damico A. Function occlusion of natural teeth in man. *J Prosthet Dent.* 1961;11:899–915.
- Schuyler CH. Factors of occlusion applicable to restorative dentistry. *J Prosthet Dent.* 1953;3:772–82.
- Choukse V, Parmar A, Sharma N, Srivastava R. Full Mouth Rehabilitation using Hobo Twin-stage Technique. *Int J Prev Clin Dent Res.* 2017;4(4):319–23.
- Hobo S, Takayama H. Oral rehabilitation, Clinical determination of occlusion. vol. 17. Carol Stream, Illinois: Quintessence Publishing Co. Inc; 1997. p. 32–5.

## Author biography

Rahul Patil, Specialist Prosthodontist

**Cite this article:** Patil R. Full mouth prosthetic rehabilitation using hobo's philosophy: A case report. *IP Ann Prosthodont Restor Dent* 2023;9(3):179-186.