

Content available at: <https://www.ipinnovative.com/open-access-journals>

IP Annals of Prosthodontics and Restorative Dentistry

Journal homepage: <https://www.aprd.in/>

Original Research Article

Assessment of maxillary anterior teeth using RED proportion and golden proportion among adult young Gujarati individuals

Bhagyashree H Dave^{1,*}, Shruti P Mehta², Shreyansh P Sutaria³, Setu P Shah²¹Dept. of Prosthodontics, Sidhpur Dental College, Patan, Gujarat, India²College of Dental Science Research Centre, Ahmedabad, Gujarat, India³Class II Dental Surgeon, CHC & RH Tarapur, Anand, Gujarat, India

ARTICLE INFO

Article history:

Received 05-04-2023

Accepted 15-06-2023

Available online 10-10-2023

Keywords:

Maxillary anterior teeth

Dental esthetic

Golden Proportion

RED proportion

ABSTRACT

Introduction: Comprehensive studies assessing the spatial examination of maxillary anterior teeth with respect to various esthetic proportions like RED proportion and Golden proportion are insufficient for Gujarati Individual.

Purpose: The purpose of this study is to assess the validity of Recurring Esthetic Dental (RED) Proportion and Golden proportion in maxillary anterior teeth among young adult Gujarati individual.

Materials and Methods: This clinical Evaluation study included a total of 70 Gujarati individuals that met the inclusion criteria having 40 females and 30 males. Dental casts of the maxillary arches for each individual were made with irreversible hydrocolloid material and dental stone was then poured to get the diagnostic casts. Using a digital caliper, dimensions and the perceived width of the anterior teeth from the front were assessed. The data was analyzed using SPSS.

Results: The RED proportion and Golden proportion were not in co-relation between perceived maxillary anterior teeth widths of Gujarati individuals.

Conclusion: The Golden proportion and the RED proportion cannot be used as constant proportions to create a harmonious smile.

This is an Open Access (OA) journal, and articles are distributed under the terms of the [Creative Commons Attribution-NonCommercial-ShareAlike 4.0 License](https://creativecommons.org/licenses/by-nc-sa/4.0/), which allows others to remix, tweak, and build upon the work non-commercially, as long as appropriate credit is given and the new creations are licensed under the identical terms.

For reprints contact: reprint@ipinnovative.com

1. Introduction

An Individual's self-confidence boots up when someone sees eye-catching smile that sustains and improves an appealing appearance accordingly.¹ Although societies have their own criteria of beauty, evaluation of attractive smiles have shown that repeatable, calculable, and evenly applied principles can be logically used to evaluate and improve dental esthetics.² For great Esthetics, Adequate size, shape, color, biotype, gingival zenith, smile line, minimized negative space; axial inclination gradation, incisal embrasure gradation, and gingival frame contour are essential for patient satisfaction in modern dentistry.^{3,4} To

achieve an well-organized balance between the aesthetic harmony of the face with the dentofacial structures, several guidelines are introduced. These guidelines are the foundation for aesthetic knowledge and are extensively followed by aesthetic, Prosthodontics and restorative practitioners worldwide.^{2,4-10}

One of the widely accepted classic esthetic concepts is the golden proportion (GP) (1.618:1.0), as given by Lombardi⁸ in 1973 and is applied to dentistry by Levin¹¹ in 1978. According to them, golden proportion existed within the dimensions of a smiling face and should be applied at the time of the arrangement of maxillary anterior teeth as the said proportion existed between the dimensions of the

* Corresponding author.

E-mail address: bhagyadave91@gmail.com (B. H. Dave).

central incisor (CI), lateral incisor (LI), and the canine (Ca) to enhance the esthetic.^{9,11}

On the other hand, Preston in 1993 reported that for the average natural dentition, golden proportion was not observed.¹² He stated that the golden proportion cannot be always applied to the relationship of maxillary anterior teeth as tooth dimensions changes with gender and race. Mahshid et al. also stated the clinical application of the golden proportion is very difficult and its use is theoretical in esthetic dentistry.¹³ Moreover, in a survey by Rosenstiel et al., it had been said that the patients with the long teeth can be treated using Golden proportion.⁴ Furthermore, Umer et al. found Golden proportion in 63% of Pakistani population using the Phi dental grid, still he proposed that a range of anterior teeth proportions should be considered to determine dental attractiveness rather than a single value.¹⁴

In dentistry Many researchers have invented their own set of guidelines other than golden proportion for anterior esthetic rehabilitation.^{2,5,6} Studies have suggested that different tooth proportions are associated with gender, ethnicity, and various genetic and environmental factors. Environmental factors such as diet, nutrition, radiation, and chemicals also affect the mesio-distal width of teeth, whereas Genetic factors can affect the calcification of teeth, the shape of a coronal structure, and the composition of minerals in the process of growth and development of teeth.^{9,10,15–18} Also, ethnicity is suggested to have high influence on tooth proportions than gender.^{19–22} However, with variations in the ethnicity of the population it is recommended that the golden principle can be applied if the percentages are adjusted.^{19,23} These results necessitate the assessment of anterior dentition among ethnic group or various populations.

2. Aim & Objective

This study is to evaluate maxillary anterior teeth using golden proportion and RED proportion among young Adult Gujarati Individual.

3. Materials and Methods

70 dental students from the age range 18-30 years were included in the study. All the participants had volunteered themselves for the study, had their natural esthetic maxillary anterior six teeth present, had a full set of natural dentitions, any dentofacial deformity or asymmetry in the anterior region or any restorations, no history of orthodontic or orthognathic treatment, spacing or crowding in the anterior teeth, a history of periodontal treatment or dentoalveolar

trauma. The subjects with problems affecting the teeth and face (trauma, accident, facial or dental operation), gingival or dental irregularity (recession, extrusions), congenital anomalies, or disruption in the original tooth structure because of caries, restoration, erosion, or fracture were excluded. The study protocol was in co-ordinance with the principles of the Declaration of Helsinki approved by the institutional ethics committee. The subjects for this cross-sectional descriptive study were selected through the following non-probability method.

The whole procedure was made simple; Maxillary impressions were made with irreversible hydrocolloid material (Zhermack Tropicalgin Alginate), and dental stone (Kalabhai Ultrarock DieStone) was poured to get the diagnostic casts for the measurements. The cast was positioned on a hard paper such that the mid-palatal raphe is parallel to and along the midsagittal axis (Line 2) and perpendicular to another line parallel to the coronal axis (Line 1) as shown in Figure 1.

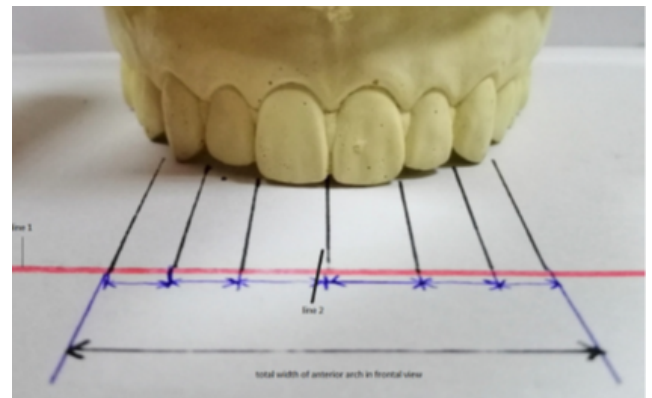


Fig. 1: Showing the method for measurement of widths of anterior teeth and total arch width in frontal view. (Line 1 corresponds to a line parallel to the coronal plane and perpendicular to line 2 that corresponds with the mid-sagittal axis).

From the frontal view, by drawing perpendicular lines on Line 1 from the mesial and distal ends of the teeth visible, the widths of the anterior teeth were measured. With the use of an extra-fine end digital caliper (Zhart Digital Caliper with a precision of 0.01 mm.), dimensions of the anterior teeth were measured with bilaterally. The total width of all the anterior teeth in frontal view was also recorded. Each measurement was repeated thrice by the operator and a mean value taken to obtain accurate results.

The width of anterior teeth was determined using the harmony between the RED and GP proportion. In the RED proportion, 70% of the width of the central incisor was compared with the adjacent lateral incisor, and 49% of the width was compared with the width of the canine. In the GP, 62% of the width of the central incisor was compared

with the adjacent lateral incisor, and 38% of the width was compared with the width of the canine. If these proportions were the same then the RED proportion was considered to exist. These calculations were made bilaterally.

For male and female participants, all these measurements and proportions were assessed separately. These esthetic measurements were checked for the proportions of teeth in a particular Gujarati Individual if they meet with the esthetic standards. Statistical software (IBM SPSS Statistics, v20.0; IBM Corp) was used to perform statistical analysis. Descriptive statistics and a 1-sample t-test were used ($\alpha=0.05$).

4. Results

Table 1 shows the mean dimensions and standard deviations obtained by measuring the maxillary anterior teeth on the cast of 40 female and 30 male students. The width of central incisors was lesser in men than women, but lateral incisor width was higher in men. Right and left teeth shows Differences in the dimensions.

Both in men and women, the ratio of maxillary central incisors to lateral incisors and the ratio of central incisors to canine were significantly different from the golden proportion according to 1-sample t-test (Table 2). Except width of LI to CI in men, the ratios on the right and left sides were different in women and men.

According to the assessment of the RED proportion (Table 3), no recurring proportion was found between right and left adjacent anterior teeth in either women or men according to the 1-sample t test. The proportions between the left and right sides were the different in women and men except for the proportion between the lateral incisor and central incisors in men.

5. Discussion

This study was conducted in Gujarati population (men and women) to evaluate the best mathematical proportion between the maxillary anterior teeth widths if it exists. For the best esthetic and treatment planning, the maxillary anterior teeth have significant implications for the shape and size.

Dental esthetic depends on various factors and there are some relationships amongst them. The Recurring Esthetic Dental proportion and golden proportion can help in the esthetic zone but at the time of teeth selection, clinicians should also consider racial differences. The maxillary central incisors are the dominant teeth in esthetic area, hence a key factor in morphology and dimensions. Years ago, dimensions of teeth were evaluated from extracted

teeth, but now-a-days photographs and casts are used.¹⁷ Therefore, present study was performed on casts made under standard conditions of dentate subjects.

The results of the study show that the Recurring Esthetic Dental (RED) proportion and the Golden Proportion (GP) were significantly different from the dimensional proportions based on the apparent dimensions of maxillary anterior teeth in a sample of the Gujarati population. Determining the geometric or mathematical relationships among the anterior teeth is crucial for successful esthetic result. This result can be useful to evaluate reliable statistical data, exist in currently available theories.^{23,24}

Rosenstiel et al⁴ reported that, 0.80 is preferred ratio for tall or very tall teeth which was worst for shorter or normal height teeth. Ward reported that a ratio of ratio of 0.618 was not acceptable as 0.70, as latter could give more acceptable outcomes.⁶ In their study, according to the authors the dimensions of anterior teeth was significantly different from the golden proportion, similar to those of other studies.^{17,23,25–27}

Mahshid et al¹³ reported after assessing the photographs of 157 participants that no the conformity between the GP and the apparent dimensions of the maxillary anterior teeth. Results are totally different in women and men in the present study. Hence for the assessment of maxillary anterior teeth, the golden proportion cannot be used as a general esthetic parameter,²⁸ as some individuals can rarely have the golden proportion while they may have definite correlation between esthetic maxillary anterior teeth and other parameters.

Recurring Esthetic Dental (RED) proportion concept was introduced by Ward.⁶ According to him, the ratio should be constant which is 0.7 for the width of the successive tooth to the width of the mesial neighboring tooth, when viewed from the facial aspect.⁶ Pitel et al²⁹ evaluated the for the RED proportion, the preferences experts and non-experts in dentistry. In their study, they reported that if the found ratio was below 0.7, the experts did not have a bias into the choice of RED proportion for both men and women. The present study found that the ratio is different than 0.7 for the maxillary anterior adjacent teeth. The ratio from lateral to central incisor is similar on left and right sides in men and the ratios in women and men on the right and left sides were different.

6. Conclusion

In esthetic dentistry, for ages, the golden proportion has been seen as a tool of beauty and harmony and has served as a standard or guide. However, its universal application

Table 1: Maxillary anterior teeth width in men and women.

	Width of CI		Width of LI		Width of C	
	Right	Left	Right	Left	Right	Left
Women	8.49	8.47	6.44	6.57	3.91	3.73
Men	8.38	8.41	6.53	6.55	4.22	4.03

C- canine; CI- central incisor; LI- lateral incisor.

Table 2: For comparison with golden proportion (GP) in women and men, significance level of one-sample t test and Proportions of maxillary anterior tooth width relative to each other

Proportions	Mean	Right			Mean	Left	
		SD	P	SD		SD	P
Women							
Width of LI To CI (62%)	0.75	0.05	<0.001	0.77	0.05	<0.001	
Width of C To CI (38%)	0.46	0.03	<0.001	0.44	0.05	<0.001	
Men							
Width of LI To CI (62%)	0.77	0.04	<0.001	0.77	0.05	<0.001	
Width of C To CI (38%)	0.51	0.10	<0.001	0.48	0.04	<0.001	

C-canine; CI-central incisor; LI-lateral incisor; SD-standard deviation.

Table 3: Significance level of one-sample t test for comparison with recurrent esthetic dental (RED) proportion in men and women and proportions of maxillary anterior tooth width adjacent to each other.

Proportions	Mean	Right			Mean	Left	
		SD	P	SD		SD	P
Women							
Width of LI To CI (70%)	0.75	0.05	<0.001	0.77	0.05	<0.001	
Width of C To LI (49%)	0.60	0.05	<0.001	0.57	0.07	<0.001	
Men							
Width of LI To CI (70%)	0.77	0.04	<0.001	0.77	0.05	<0.001	
Width of C To LI (49%)	0.66	0.13	<0.001	0.62	0.05	<0.001	

C-canine; CI-central incisor; LI-lateral incisor; SD-standard deviation.

is still in a doubt. Although many researchers studied and applied various geometric patterns in the maxillary anterior teeth, due to variations in the variables incorporated and racial differences, it was hard to match our results with theirs. There is no RED or GP proportion in the maxillary anterior teeth in either gender in the young Gujarati population, based on the findings of this clinical study. Therefore, in order to evaluate esthetics, perception of a pleasant smile and specific population characteristics should be taken into an account in addition to the golden proportion measurement for the future studies.

7. Conflict of Interest

None.

8. Source of Funding

None.

References

- Moskowitz ME, Nayyar A. Determinants of dental esthetics: a rational for smile analysis and treatment. *Compend Contin Educ Dent.* 1995;16(12):1164–6.
- Snow SR. Esthetic smile analysis of maxillary anterior tooth width: the golden percentage. *J Esthet Dent.* 1999;11(4):177–84. doi:10.1111/j.1708-8240.1999.tb00397.x.
- Ahmed N, Abbasi MS, Khan DA, Khalid S, Jawed W, Mahmood M, et al. Determination of mesiodistal width of maxillary anterior teeth using inner canthal distance. *Pak Armed Forces Med J.* 2021;71(1):164–9.
- Rosenstiel SF, Ward DH, Rashid RG. Dentists' preferences of anterior tooth proportion—a web-based study. *J Prosthodont.* 2000;9(3):123–36.
- Erdemir U, Yucel T, Yildiz E, Germec DG, Sayinsu K. Dental analysis. In: *Esthetic and Functional Management of Diastema*, 1st edn. Cham, Switzerland: Springer International Publishing; 2016. p. 101–20.
- Ward DH. Proportional smile design using the recurring esthetic dental (RED) proportion. *Dent Clin N Am.* 2001;45(1):143–54.
- Liao P, Fan Y, Nathanson D. Evaluation of maxillary anterior teeth width: A systematic review. *J Prosthet Dent.* 2019;122(3):275–81. doi:10.1016/j.prosdent.2018.10.015.
- Lombardi RE. The principles of visual perception and their clinical application to denture esthetics. *J Prosthet Dent.* 1973;29(4):358–82. doi:10.1016/s0022-3913(73)80013-7.
- Dehesa-Santos A, Iber-Diaz P, Iglesias-Linares A. Genetic factors contributing to skeletal class III malocclusion: a systematic review and meta-analysis. *Clin Oral Investig.* 2021;25(4):1587–612. doi:10.1007/s00784-020-03731-5.
- George AM, Felicita AS, Tania SD, Priyadharsini JV. Systematic review on the genetic factors associated with skeletal Class II malocclusion. *Indian J Dent Res.* 2021;32(3):399–406. doi:10.4103/ijdr.IJDR_59_20.

11. Levin EI. Dental esthetics and the golden proportion. *J Prosthet Dent.* 1978;40(3):244–52.
12. Preston JD. The golden proportion Revisited. *J Esthet Restor Dent.* 1993;5(6):247–51. doi:10.1111/j.1708-8240.1993.tb00788.x.
13. Mahshid M, Khoshvaghti A, Varshosaz M, Vallaei N. Evaluation of "golden proportion" in individuals with an esthetic smile. *J Esthet Restor Dent.* 2004;16(3):185–92.
14. Umer F, Khan FR, Khan A. Golden Proportion in Visual Dental Smile in Pakistani Population: A Pilot Study. *Acta Stomatologica Croatica.* 2010;44(3):168–75.
15. Muhammad S, Shahid R, Siddiqui MI. Tooth Morphology and Aesthetics While Smiling in Accordance to Golden Proportion. *J Med Health Sci.* 2016;10(1):281–4.
16. Niranjana NT, Kanaparthi A, Kanaparthi R, Kiran HY. Photographic and manual evaluation of golden percentage and recurrent aesthetic dental proportion in aesthetic smiles. *J Evol Med Dent Sci.* 2016;5(38):2267–70.
17. Hasanreisoglu U, Berksun S, Aras K, Arslan I. An analysis of maxillary anterior teeth: facial and dental proportions. *J Prosthet Dent.* 2005;94(6):530–8. doi:10.1016/j.prosdent.2005.10.007.
18. Shetty TB, Beyuo F, Wilson NH. Upper anterior tooth dimensions in a young-adult Indian population in the UK: Implications for aesthetic dentistry. *Br Dent J.* 2017;223(10):781–86. doi:10.1038/sj.bdj.2017.986.
19. Ramani N, Murthy BS. Evaluation of natural smile: Golden proportion, RED or Golden percentage. *J Conserv Dent.* 2008;11(1):16–21. doi:10.4103/0972-0707.43413.
20. Sandeep N, Satwalekar P, Srinivas S, Reddy CS, Reddy GR, Reddy BA, et al. An Analysis of Maxillary Anterior Teeth Dimensions for the Existence of Golden Proportion: Clinical Study. *J Int Oral Health.* 2015;7(9):18–21.
21. Al-Marzok MI, Majeed KRA, Ibrahim IK. Evaluation of maxillary anterior teeth and their relation to the golden proportion in Malaysian population. *BMC Oral Health.* 2013;13:9–9. doi:10.1186/1472-6831-13-9.
22. Alhababah AM, Aburumman KK, Al-Shamout R, Almanaseer WA, Zyod AI. Evaluating the validity of mathematical proportions in maxillary anterior teeth in Jordanian population. *Pak Oral Dent J.* 2016;36(2):295–300.
23. Fayyad MA, Jamani KD, Agrabawi J. Geometric and mathematical proportions and their relations to maxillary anterior teeth. *J Contemp Dent Pract.* 2006;7(5):62–70.
24. Sah SJ, Zhang HD, Chang T, Dhungana M, Acharya L, Chen LL, et al. Maxillary anterior teeth dimensions and proportions in a central mainland Chinese population. *Chinese J Dent Res.* 2014;17(2):117–24.
25. Murthi BVS, Ramani N. Evaluation of natural smile: golden proportion, RED or golden percentage. *J Conserv Dent.* 2008;11(1):16–21.
26. Raj V, Heymann HO, Hershey HG, Ritter AV, Casco JS. The apparent contact dimension and covariates among orthodontically treated and untreated subjects. *J Esthet Restor Dent.* 2009;21(2):96–111. doi:10.1111/j.1708-8240.2009.00240.x.
27. Petricevic N, Stipetic J, Antonic R, Borcic J, Strujic M, Kovacic I, et al. Relations between anterior permanent teeth, dental arches and hard palate. *Coll Antropol.* 2008;32(4):1099–104.
28. Raj V. Esthetic paradigms in the interdisciplinary management of maxillary anterior dentition—a review. *J Esth Rest Dent.* 2013;25(5):295–304.
29. Pitel ML, Raley-Susman KM, Rubinov A. Preferences of lay persons and dental professionals regarding the recurring esthetic dental proportion. *J Esthet Restor Dent.* 2016;28(2):102–9.

Author biography

Bhagyashree H Dave, Associate Professor, PhD Scholar, Gujarat University

Shruti P Mehta, Professor and HOD, PhD Guide, Gujarat University

Shreyansh P Sutaria, PhD Scholar

Setu P Shah, Reader

Cite this article: Dave BH, Mehta SP, Sutaria SP, Shah SP. Assessment of maxillary anterior teeth using RED proportion and golden proportion among adult young Gujarati individuals. *IP Ann Prosthodont Restor Dent* 2023;9(3):170-174.