

Content available at: <https://www.ipinnovative.com/open-access-journals>

IP Annals of Prosthodontics and Restorative Dentistry

Journal homepage: <https://www.aprd.in/>

Review Article

Customised cheek plumper for completely edentulous patient- A clinical report

Soujanya Patil^{1,*}, Rajeshwari CL¹, Srivatsa G¹

¹Dept. of Prosthodontics, KLE Society's Institute of Dental Sciences, Bengaluru, Karnataka, India



ARTICLE INFO

Article history:

Received 20-12-2022

Accepted 08-02-2023

Available online 21-03-2023

Keywords:

Complete denture

Cheek plumper

Customised Attachments

ABSTRACT

Facial aesthetics is of utmost importance in person's life. Aging is associated with loss of teeth, residual ridge resorption and reduced tonicity of the facial muscles, leading to an unesthetic appearance and sunken cheeks in some individuals. Aesthetics in such individuals seeking complete dentures can be improved with the help of cheek plumper by supporting and lifting the cheeks. This article describes an innovative, simple, cost-effective attachment system made by modifying the casted sprue as mode of attachment in completely edentulous patient requiring complete denture prostheses with detachable cheek plumper.

This is an Open Access (OA) journal, and articles are distributed under the terms of the [Creative Commons Attribution-NonCommercial-ShareAlike 4.0 License](https://creativecommons.org/licenses/by-nc-sa/4.0/), which allows others to remix, tweak, and build upon the work non-commercially, as long as appropriate credit is given and the new creations are licensed under the identical terms.

For reprints contact: reprint@ipinnovative.com

1. Introduction

In present era, individuals are more concerned with aesthetics. Aging has a significant impact on external facial aesthetics, due to early tooth loss, alveolar resorption, and reduced tonicity of musculature resulting in sunken or hollow cheeks and undesirable facial aesthetics.^{1,2}

Prosthodontic rehabilitation does not mean to simply replace the missing teeth, but also restore the facial support. Conventional procedures can fulfil replacement of missing teeth. But in some cases, where the patient has sunken cheeks an extra support to the dentures can be provided. This can be achieved by using cheek plumpers which can be detachable and undetachable.³ Undetachable cheek plumpers are not commonly used due to its increased weight and also adds discomfort to patient during mastication. This prosthesis becomes more challenging in patients with limited mouth opening. These flaws can be overcome by using a detachable cheek plumper.⁴

The detachable cheek plumpers are attached to complete denture by various modes such as magnets,^{3,5-8} ball

end clasps, press buttons,^{3,9} customized friction lock attachment,¹⁰ die pins,¹¹ hooks and loops¹² and by customizing orthodontic wire springs all of which are available in the literature and used by various authors.¹²

Though many methods have been described in the literature, this clinical report describes an innovative technique for fabricating detachable maxillary cheek plumpers in a completely edentulous patient by using the left out casted sprues as a mode of attachment.

2. Case Report

A 67-year-old male patient reported to the Department of prosthodontics with the chief complaint of missing teeth and a sunken cheek appearance. Medical history revealed no significant findings, and previous dental history revealed that patient lost his teeth due to periodontal problems and had been edentulous for the past 6 months.

Extraoral examination revealed straight profile with hollow cheeks. On intraoral examination, the patient had a u-shaped, well-rounded maxillary arch and a V-shaped, well-rounded mandibular arch, class I ridge relation with adequate inter-arch space. Hard and soft palates were normal with House classification of Class I. The tongue

* Corresponding author.

E-mail address: soujanyapatil16@gmail.com (S. Patil).

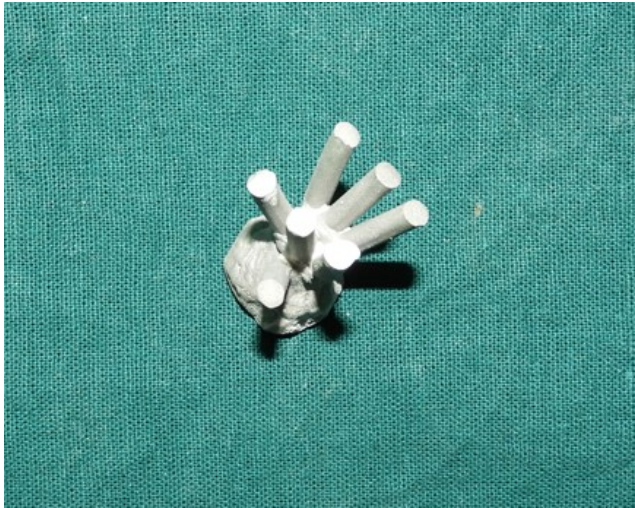

Fig. 1: Metal casted sprue

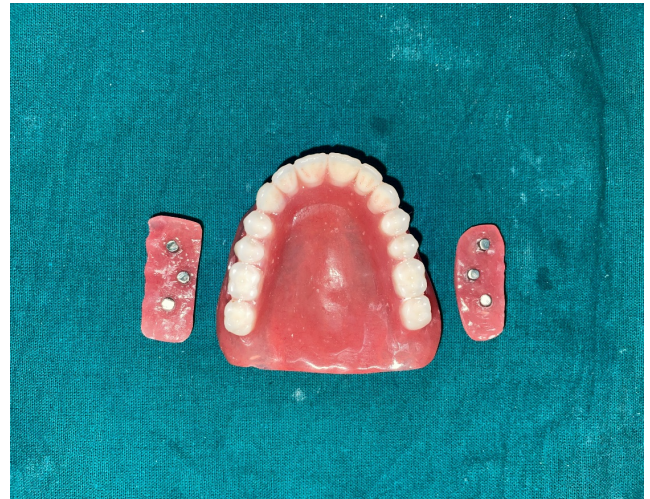

Fig. 4: Heat cured acrylized maxillary complete dentures and cheek plumpers



Fig. 2: Metal casted sprue of length 5mm.

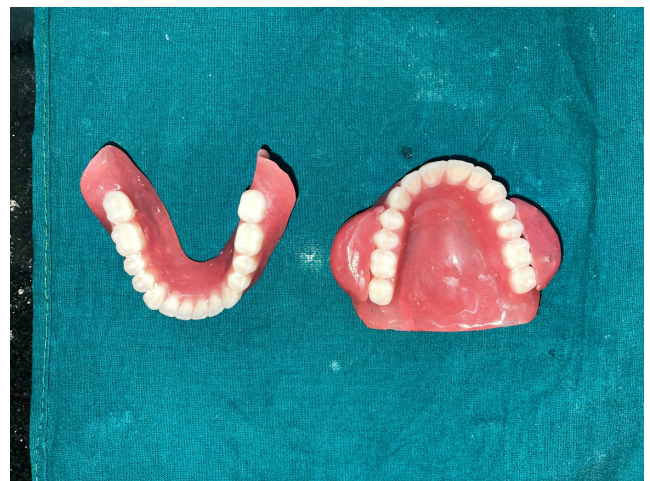

Fig. 5: Cheek plumper attached to maxillary complete denture

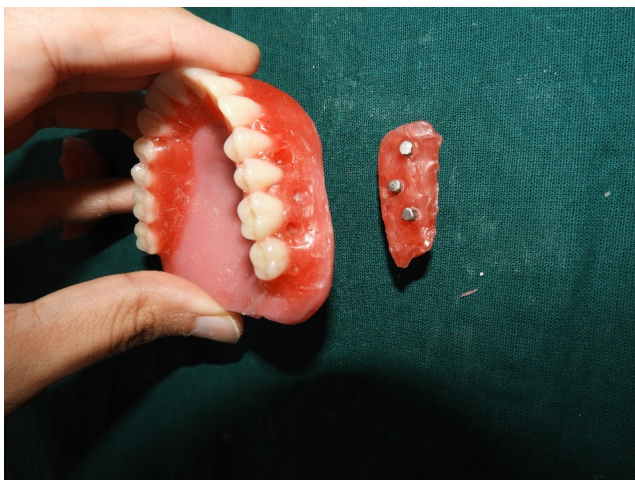

Fig. 3: Trial waxed up denture and detachable cheek plumper.

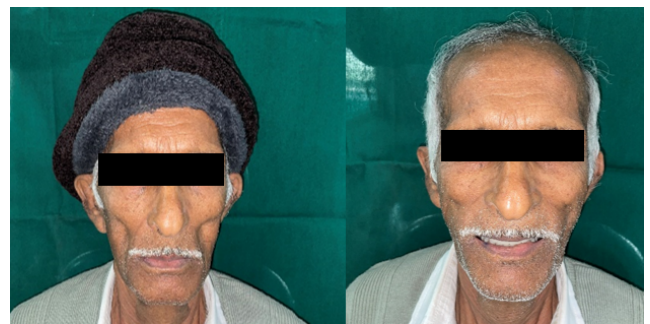

Fig. 6: Pre-treatment photograph and post-treatment photograph (frontal view)

position was Wright Class II and the size (House class II) was normal. The Lateral throat form was moderate with class II (Neil's classification) and the mucosa was normal (House Class I) with mixed saliva.

The treatment plan was to fabricate a complete denture prosthesis with a detachable cheek plumper on either side of the maxillary denture.

2.1. Procedure

Maxillary and mandibular impressions were made using impression compound (Y Dents Impression Compound, MDM Corp.) and special trays were fabricated using auto polymerizing acrylic resin (DPI RR Cold Cure Acrylic). Border moulding was made using low fusing impression compound (DPI Pinnacle tracing stick) followed by final impressions with light body addition silicone elastomeric impression material (Zhermark Hydrolase Light body, PVS).

Jaw relations were recorded. During the try-in appointment, the waxed denture was first tried for occlusion, phonetics, and aesthetics. At the same appointment, the modelling wax was added on either side of the maxillary trial denture from the premolar to molar region till the sunken cheek got required fullness and patient was assessed to do functional movements. Patient's consent was obtained for facial appearance and the denture.

2.2. Customization of attachments (metal sprue)

Metal-cast sprues obtained from previous castings of fixed partial dentures were used for attachments [Figure 1]. Three sprues were cut into equal lengths of about 5mm. [Figure 2] They were trimmed, finished, polished and incorporated into the cheek plumper part, leaving about 2-3 mm outside the plumper. On one end of metal sprue small grooves were made and surface was roughened. They were placed in a tripod configuration (one above and two below) on the inner side of cheek plumper and were oriented parallel to each other. [Figure 3] The corresponding part of the denture was softened and depressions were created by repeated placement and removal of the projections of the cheek plumper [Figure 3].

The dentures and cheek plumpers were fabricated separately using the compression moulding technique. Dentures and cheek plumpers were trimmed, finished and polished. [Figures 4 and 5]. On the day of placement, cheek plumpers were attached to the denture extra orally and tried in the patient's mouth. Retention, stability, support, aesthetics, occlusion, and function were evaluated and found to be satisfactory. The patient was given instructions regarding how to use and maintain the cheek plumpers. The patient was asked to follow-up after 24 hours, 3 days, 1 week and accordingly, complaints were addressed. [Figure 6].

3. Discussion

A cheek plumper, or cheek lifting appliance, is a prosthesis which is used as an adjunct to artificial dentures to support the sunken cheeks to improve facial aesthetics. It can be incorporated either as fixed or removable and can be attached either to maxillary or mandibular dentures as per the requirements of the case without compromising retention and aesthetics.⁴

Undetachable cheek plumpers have their own disadvantages. They could cause muscle fatigue with continuous use. Muscle fatigue can be prevented if the patient has the option of removing the cheek plumpers when experiencing discomfort.⁴

Previous clinical reports have discussed the use of press-stud fasteners and magnets.^{3,5-8} A few authors have used stud attachments,³ friction lock attachment,¹⁰ wire-retained cheek plumpers,¹² and orthodontic elastic modules.^{5,6,13}

Magnets used intraorally are of small compact size and have strong attractive forces but they often require replacement due to lack of long-term durability in oral condition.³ Press button retained cheek plumpers have poor corrosion resistance, food lodgements, and a minimum of 2 buttons for each plumper is preferred for better stability. The press buttons are not medical grade or approved for use in the oral cavity.^{3,9}

Keni et al. described a technique to support shrunken cheeks with a detachable cheek plumper using customised attachments made of Co-Cr alloys and orthodontic separators. Customized attachments such as brackets, castings, and keys and keyways are too tedious for fabrication and are expensive.¹³

Attachments should be economical, long-lasting, and detachable. Taking into account all of these factors, an innovative clinical technique was tried for fabricating a complete denture with a detachable cheek plumper that is comparatively easy, affordable, and efficient.

The metal-casted sprue is made of a cobalt-chromium alloy and usually these casted sprues are discarded or reused by adding certain proportions for next casting.^{14,15} In our case report we used these sprues as an attachment for cheek plumper to support the concept of recycle/reuse.

The cobalt-chromium alloy is readily available in a dental laboratory, so the overall cost of the attachment is reduced. It has the properties of biocompatibility and corrosion resistance and a reported lower number of allergies compared to other metals.^{16,17}

Also, these customised attachments were incorporated on the inner part of cheek plumper, it has added advantage that if the patient removes the plumper, it will not cause any irritation to the cheek. Grooves were made in one end of the cut sprue for retention to the cheek plumper part. Three sprues were used and were oriented parallel to each other for ease of placement and removal. Additionally, because it was detachable, the patient could use the denture without

the plumpers if necessary.

However, this technique has a few limitations, including the accumulation of food in the holes of the denture and needs frequent cleaning, patient discomfort resulting from the additional weight due to metal casted sprue.

4. Conclusion

Prosthodontic rehabilitation does not mean to simply replace the missing teeth, but also restore the facial support. Cheek plumper are simple to fabricate and provide a non-invasive and cost-effective treatment option to enhance facial aesthetics in patients with sunken cheeks. This innovative method helped to achieve overall well-being of the patient.

5. Conflict of Interest

None.


6. Source of Funding

None.

References

1. Tautin FS. Denture esthetics is more than tooth selection. *J Prosthet Dent.* 1978;40(2):127–30. doi:10.1016/0022-3913(78)90003-3.
2. Jamieson CH. Geriatrics and the denture patient. *J Prosthet Dent.* 1958;8(1):8–13. doi:10.1016/0022-3913(58)90004-0.
3. Deogade SC. Magnet retained cheek plumper in complete denture esthetics: a case report. *J Dent (Tehran).* 2014;11(1):100–5.
4. Viridiya NM, Palaskar JN, Wankhade J, Joshi N. Detachable cheek plumpers with different attachments for improving esthetics in a conventional complete denture: A clinical report. *J Prosthet Dent.* 2017;117(5):592–6. doi:10.1016/j.prosdent.2016.08.021.
5. Punia V, Mishra R, Khandelwal M, Verma N, Handa M. Magnet retained detachable cheek plumper: innovation personified-A case report. *Int J Prosthet Dent.* 2013;4(1):16–20.
6. Riley MA, Walmsley AD, Harris IR. Magnets in prosthetic dentistry. *J Prosthet Dent.* 2001;86(2):137–42. doi:10.1067/mpd.2001.115533.
7. Venkatachalapathy SR, Chander GN, Gnanam P. A magnetically retained cheek plumper in a maxillary single complete denture: A clinical report. *J Interdisciplinary Dent.* 2019;9(1):25–30. doi:10.4103/jid.jid_37_18.
8. Verma N, Chitre V, Aras M. Enhancing appearance in complete dentures using magnetic retained cheek plumpers. *J Indian Prosthodont Soc.* 2004;4(2):35–8.
9. Aggarwal P, Gupta MR, Pawah S, Singh A. An innovative technique to improve complete denture aesthetics using cheek plumper appliance: A case report. *Int J Oral Health Med Res.* 2016;3:51–4.
10. Bhushan P, Aras MA, Coutinho I, Rajagopal P, Mysore AR, Kumar S, et al. Customised cheek plumper with friction lock attachment for a completely edentulous patient to enhance aesthetics: A clinical report. *J Prosthodont.* 2019;28(1):1–5.
11. Pudi S, Kota S, Ch KK, Kaladi SR, Gade RR. An innovative technique using a stainless steel double die pin retained cheek plumper in complete denture esthetics: A case report. *Cureus.* 2019;11(11):e6197. doi:10.7759/cureus.6197.
12. Kumar D, Rajeswari CL, Srivatsa G, Shetty RM. Hooks retained detachable Cheek plumper to enhance aesthetics in a completely edentulous patient-A case report. *Int J Oral Health Dent.* 2019;5(3):136–9.
13. Keni NN, Aras MA, Chitre V. Customised attachments retained cheek plumper prosthesis: a case report. *J Indian Prosthodont Soc.* 2012;12(3):198–200. doi:10.1007/s13191-012-0132-y.
14. Vaillant-Corroy AS, Corne P, March D, Fleutot P, Cleymand S, F. Influence of recasting on the quality of dental alloys: A systematic review. *J Prosthetic Dent.* 2015;114(2):205–11.
15. Bauer J, Cella S, Pinto MM, Costa JF, Reis A, Loguercio AD, et al. *Resour Conserv Recycling.* 2010;54(12):1312–6. doi:10.1016/j.resconrec.2010.05.008.
16. Khamis E, Seddik M. Corrosion evaluation of recasting non-precious dental alloys. *Int Dent J.* 1995;45(3):209–17.
17. Takeda T, Shigami K, Shimada A, Ohki K. A study of discoloration of the gingiva by artificial crowns. *Int J Prosthodont.* 1996;9(2):197–202.

Author biography

Soujanya Patil, Post Graduate Student  <https://orcid.org/0000-0001-6937-069X>

Rajeshwari CL, Professor  <https://orcid.org/0000-0003-2866-1268>

Srivatsa G, Professor and Principal  <https://orcid.org/0000-0001-7996-3763>

Cite this article: Patil S, Rajeshwari CL, Srivatsa G. Customised cheek plumper for completely edentulous patient- A clinical report. *IP Ann Prosthodont Restor Dent* 2023;9(1):3-6.