

Radix- The Elusive Third Musketeer

Radhika Rastogi^{1,*}, Vishal Bhoiwala², Aditi Mishra³, Prerna Thareja⁴

^{1,3,4}Senior Resident, Dept. of Dentistry, All India Institute of Medical Sciences, Jodhpur

²Private Practitioner, Surat

*Corresponding Author

Radhika Rastogi

Senior Resident, Dept. of Dentistry, AIIMS, Jodhpur

E-mail: drradhika.rastogi@gmail.com

Abstract

The root canal treatment of teeth with aberrant canal configuration can be challenging to treat successfully. Mandibular molars can have an additional root which may be termed on the basis of location as radix entomolaris (RE) if located lingually or the radix paramolaris (RP) if arose buccally. This report discusses endodontic treatment of three mandibular molars with (RE). Success of conservative endodontic approach depends on the proper identification and thorough chemo-mechanical preparation of all the three canals, master cone confirmation by radiograph followed by three dimensional obturation with bonding agent. This article presents three case reports of mandibular first molars with extra roots.

Key words: Anatomical variation, Extra root, Mandibular molar, Radix Entomolaris.

Introduction

Failure of root canal treatment occurs due to improper cleaning and shaping of canals, failure of establishment of hermetic seal, under filling, overfilling and also due to improper identification of canals and lack of understanding of root canal morphology. An awareness and understanding of the presence of unusual root canal morphology significantly contributes to the success of root canal treatment 1.

The majority of mandibular first molars are two rooted with one mesial root and one distal root². A developmental variation can occur in mandibular molars which is associated with an extra root or third root, usually arise as a division of the apical third of the mesial root or rarely from the distal root.³

An additional third root in mandibular molar, first mentioned by Carabelli, is called the Radix Entomolaris (RE).² In RE the supernumerary root is located distolingual to the mesial root of the mandibular molars. Similar variation is Radix Paramolaris (RP) where an additional root arises at the mesiobuccal side of the distal root of the mandibular molar.³ A separate RE in the first mandibular molar is frequently observed to be present in certain ethnic groups. In white Caucasian (UK, Dutch, Finnish, German), African (Bantu Bushmen), Eurasian and Indian populations the reported frequency of RE is less than 5%. In populations with Mongoloid traits, such as the Chinese, Eskimos, and native American populations, the frequency is found to be 5 to more than 30%^{4,5}.

Case Report 1

A 35 year old male patient reported to Department of Conservative Dentistry and Endodontics with a chief complaint of severe pain in the lower right posterior tooth region since six days. Pain was intermittent which aggravated on taking cold and hot food. Clinically the

tooth was deeply carious. The diagnostic radiograph showed no periapical changes but there appeared to be an additional root. Hence another radiograph was taken which with image localization technique which confirmed the presence of an extra root. Local anesthesia was administered. Under rubber dam tooth was isolated and access preparation was done with an endo access bur no.1 (Dentsply, Switzerland). The root canals were located with DG- 16 endodontic explorer (Dentsply, Switzerland). The orifice of the fourth canal was present far from distal root canal orifices. Patency of canals was made with 10 number K -file. The working length of all the canals was determined radiographically. The irrigants used to clean were 2.5% sodium hypochlorite and EDTA. Shaping was done with Protaper rotary system (Dentsply, Switzerland) till a size of F-2 for distal canals and F-1 for mesial canals. At the next appointment, patient had no complaints. Master cone radiograph revealed proper fitting of cones. Canals were dried with paper point and obturation done by using zinc oxide eugenol sealer.

Case Report 2

A 20 years old female came with deeply carious right mandibular first molar. Radiograph of mandibular right first molar was normal without any periapical changes. The access preparation was done after anaesthetizing the tooth. Canal orifices were located with DG 16 endodontic explorer (Dentsply, Switzerland). Initial negotiation of the canals was made with K-file 10. The fourth disto-lingual canal orifice was identified. The canal lengths were determined radiographically with K file 15 size. They were cleaned with 2.5% sodium hypochlorite along with EDTA and shaped with Protaper rotary system (Dentsply, Switzerland). On subsequent visit, patient was asymptomatic. Canals were dried with paper point and

obturation was done by using zinc oxide eugenol sealer.

Case Report 3

A 35 year old male patient came with chief complaint of severe pain in the right mandibular molar region. Pain was continuous which aggravated on taking hot substances and on mastication. Diagnostic radiograph shows no periapical changes but shows radiolucency involving pulp. After administering local anesthesia the tooth was isolated under rubber dam. Access opening was done with Endo access bur. Three canals were located but the dentinal map was slightly extending in a distolingual direction. Access preparation was modified in that direction. The fourth canal was explored with DG 16 explorer. Working length was determined radiographically, cleaning and shaping was performed with rotary ProTaper instruments. Obturation was performed in the next appointment when the patient was asymptomatic.

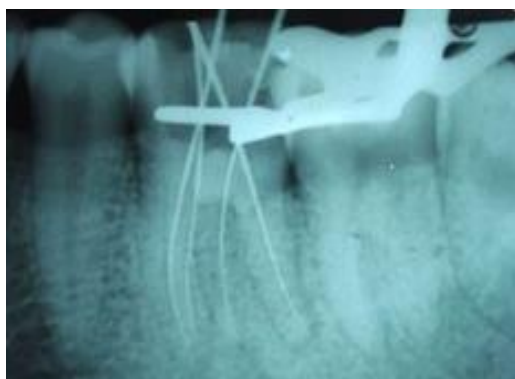

Fig. 1a: Working length radiograph

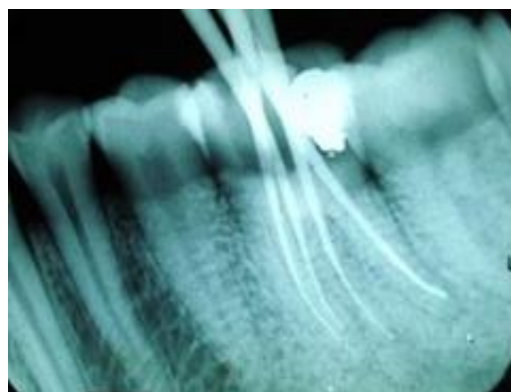


Fig. 1b: Master cone radiograph

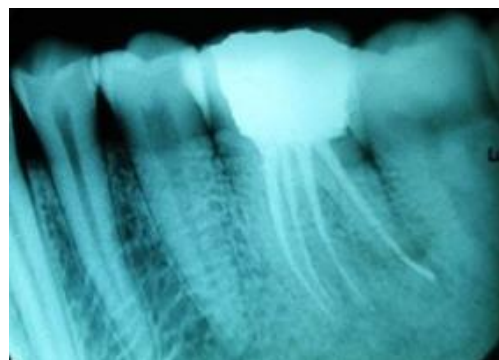


Fig. 1c: Obturation radiograph

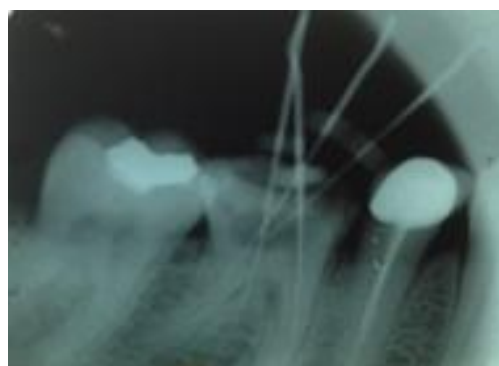


Fig. 2a: Working length radiograph

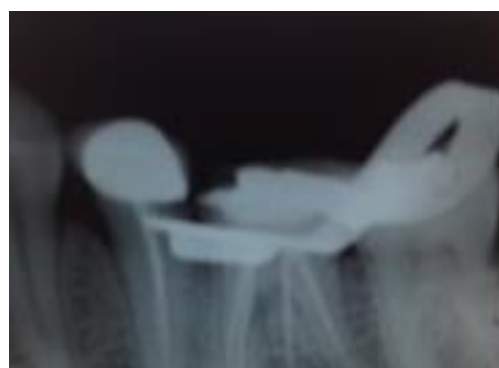


Fig. 2b: Master cone radiograph

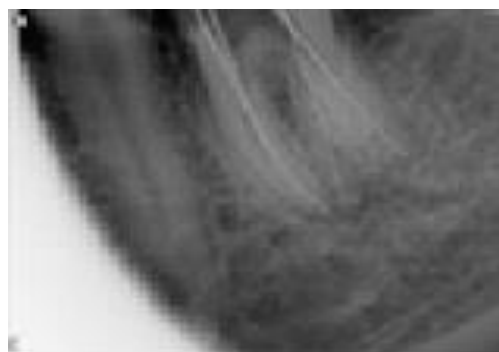

Fig. 3a: Working length radiograph

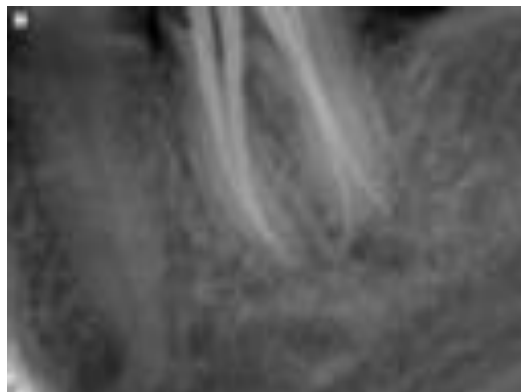


Fig. 3b: Master cone radiograph

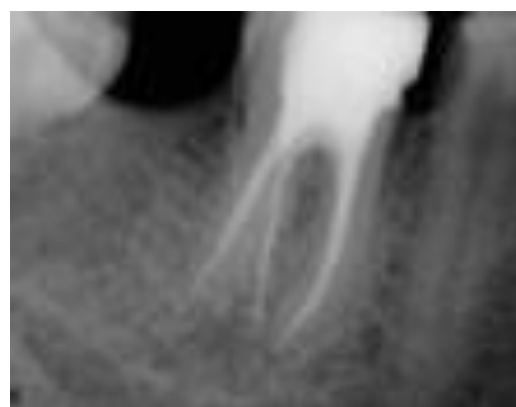

Fig. 3c: Obturation radiograph

Discussion

Radix entomolaris and Radix paramolaris can be found on the first, second and third mandibular molar, least frequently associated with second molar. There is 50 to 67% occurrence of bilateral the RE¹. The etiology of RE is still not very clear. Etiology of supernumerary roots formation is not very clear. It is thought to be multifactorial i.e. could be either due to external factors during odontogenesis, or cause of penetrance of an atavistic gene or influence of polygenetic system. Ethnic or racial genetic factors influence the profound expression of a particular gene in eumorphic roots resulting in the more pronounced phenotypic manifestation.⁶

The dimensions of RE and RP root may vary from a short conical extension to a 'mature' root with normal length and root canal.

Carlsen and Alexandersen classification describes four different types of RE based on the location of the cervical part of the RE which helps in the identification of separate and non-separate RE⁷

1. Type A: The RE is located lingually to the distal root complex, which has two cone-shaped Macrostructure.
2. Type B: The RE is located lingually in the distal complex, which has one cone-shaped Macrostructure.
3. Type C: The RE is located lingually to the

mesial root

4. Type AC: The RE is located lingually between the mesial and distal root complexes.

Based on curvature in buccolingual orientation, De Moor et al classified into three types:

1. Type I – Refers to straight root/root canal
2. Type II – Refers to initially curved entrance which continuous as a straight root/root canal.
3. Type III – Refers to an initial curve in the coronal third of the root canal and a second buccally oriented curve starting from middle to apical third.

Carlson and Alexandersen describes and classify RP into two different types:

1. Type A – Refers to an RP in which the cervical part is located on the mesial root complex.
2. Type B – Refers to an RP if cervical part is located centrally between the mesial and distal root complexes.

Generally RE is smaller than the disto-buccal and mesial roots and can be separate or partially fused with the other roots. The location of the orifice of the RE is disto- to mesiolingually from the main canal in the distal root. In case of RP the orifice of the buccal root is situated mesiobuccally from the distal canal (center of the line connecting mesiobuccal and distal canal orifices). When the presence of a supernumerary root is suspected, accurate radiographic diagnosis, clinical inspection, and pulp chamber opening have to be considered.

Conclusion

The initial diagnosis of Radix Entomolaris or Paramolaris before root canal treatment is important to avoid 'missed' canals. Preoperative periapical radiographs taken at two different horizontal angulations to identify the additional roots. Knowledge of the location of the additional root, root canal orifice as well as curvature will result in a modified opening cavity. A careful and adapted diagnostic and clinical approach is necessary avoid or overcome procedural errors during endodontic therapy.

Conflict of Interest: None

Source of Support: Nil

References

1. Giuseppe Cantatore, Elio Berutti & Arnaldo Castellucci. Endodontic Topics 2009;15,3-31.
2. Vertucci FJ. Root canal anatomy of the human permanent teeth. Oral Surgery, Oral Medicine, Oral Pathology 1984;58(5):589-99.
3. Calberson FL, De Moore RJ, Deroose CA. The radix entomolaris and paramolaris: clinical approach in endodontics. Journal of Endodontics. 2007;33:58-63.
4. De Moor R.J et al, International Endodontic Journal. 2004 Nov;37(11):789-99.
5. Yew SC, Chan K. A retrospective study of endodontically

- treated mandibular first molars in a Chinese population. *Journal of Endodontics* 1993;19(9):471-473.
6. Reichart PA, Metah D. Three-rooted permanent mandibular first molars in the Thai. *Community Dental Oral Epidemiology*. 1981;9:191-192.
 7. Carlsen O, Alexandersen V. Radix Entomolaris: identification morphology. *Journal of Dental Research* 1990;98:363-373.