

Content available at: <https://www.ipinnovative.com/open-access-journals>

IP Annals of Prosthodontics and Restorative Dentistry

Journal homepage: <https://www.aprd.in/>

Case Report

Enhancing aesthetics using detachable cheek plumper in conventional dentures- A clinical report

Drishti Nagi^{1,*}, Haritha Suresh¹, Rajeshwari C L¹, Srivatsa G¹

¹Dept. of Prosthodontics, KLE Society's Institute of Dental Sciences, Bengaluru, Karnataka, India



ARTICLE INFO

Article history:

Received 26-08-2022

Accepted 10-11-2022

Available online 24-11-2022

Keywords:

Cheek plumper

Denture

Hollow Cheek

Aesthetics

ABSTRACT

In the current scenario, facial appearance of the patient is of prime consideration during rehabilitation. The aesthetics of the edentulous patient are greatly affected due loss of alveolar bone, loss of muscle tonicity which may lead to undesirable hollowing of cheeks with age. Cheek plumper is a frequently used, non-invasive, simple prosthesis to support the sunken cheeks and help its cost effectiveness.

This is an Open Access (OA) journal, and articles are distributed under the terms of the [Creative Commons Attribution-NonCommercial-ShareAlike 4.0 License](#), which allows others to remix, tweak, and build upon the work non-commercially, as long as appropriate credit is given and the new creations are licensed under the identical terms.

For reprints contact: reprint@ipinnovative.com

1. Introduction

The appearance is a noteworthy component of body image; and those with facial defacement, self-esteem and self-confidence are strongly dishevelled. It carries on how one is perceived and judged by others, guiding their impressions and behaviour.¹

Facial aesthetics is of supreme importance in person's professional and communal life.²

In current set-up, facial aesthetics has become a crucial part of complete denture prosthetic rehabilitation and doesn't restrict to just replacement of missing teeth. The natural dentition or artificial prosthesis provides support to the facial muscular structure which is accountable for the peripheral form of the lips and cheeks. If these structures are unsupported, muscles become frail and do not function appropriately which leads to creasing of skin and sagging of lips and cheeks that can augment to a person's age and hence have a negative psychological effect on the patient's living.³

With progressive age, rapid resorption of bone takes place after loss of teeth. Patients who have lost molars may

appear as sunken or "hollow" cheeks.⁴ Individuals with hollow cheeks require additional support to the fascia in addition to conventional denture

As Jamieson stated, "fitting the personality of the aged patient is often more difficult than fitting the denture to the mouth." If the psychology of the patient is not considered, one's best efforts fail to deliver outcomes. Denture aesthetics is not a new term in the field of dentistry. It is defined as the effect produced by a dental prosthesis that affects the beauty and attractiveness of a person.⁵

Conventional denture prosthesis provide support to the circum-oral musculature but do not deliver adequate provision to support the cheek muscles. Thus, a cheek plumper can augment the facial appearance and forestall the flaccidity of the cheek muscles.⁶

This case report demonstrates the use of detachable cheek plumper in the conventional complete denture with customized attachments using soft liner in a patient with hollow cheeks.

2. Clinical Report

A 67-year aged male patient reported to the Department of Prosthodontics with the chief complaint of sunken cheeks.

* Corresponding author.

E-mail address: drishti709@gmail.com (D. Nagi).

Intraoral examination revealed completely edentulous maxillary and mandibular arches. Extraoral examination revealed sunken cheeks. (Figure 1) Patient had no systemic disorders.

As patient was seeking improvement in his facial appearance, a treatment plan was formulated for maxillary complete denture with detachable cheek plumper with patient's consent.

Maxillary and mandibular impressions were made using impression compound (Y Dents Impression Compound, MDM Corp.) Custom trays were made using autopolymerising acrylic resin (DPI RR Cold Cure Acrylic). Border moulding was done using low fusing impression compound (DPI Pinnacle tracing stick) and wash impressions were made with light body addition silicone (Zhermark Hydrolise Light body, PVS). Master casts were poured in Type III dental stone (Gold Stone Type III). Jaw relations were recorded and transferred to the articulator. Teeth arrangement was done according to aesthetics and phonetics.

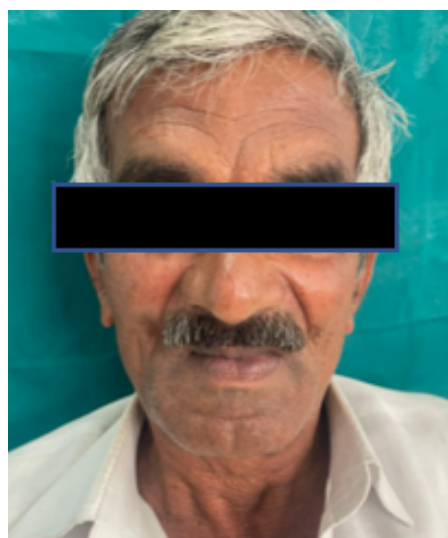

Fig. 1: Pre operative

2.1. Recording cheek plumper- (Figure 2)

Modelling wax (Hindustan Modelling Wax No. 2) was adapted on the corresponding region of maxillary trial denture. Hollowness of cheeks was evaluated from the frontal and occlusal view. While the wax up was done, it was extended till the occlusal surface and any interference was removed during eccentric movement. The patient was asked to stimulate all muscles by executing functions like movement of the cheek, licking, smiling, sucking and pursing of lips with the modelling wax block and was removed from trial denture once found satisfactory.

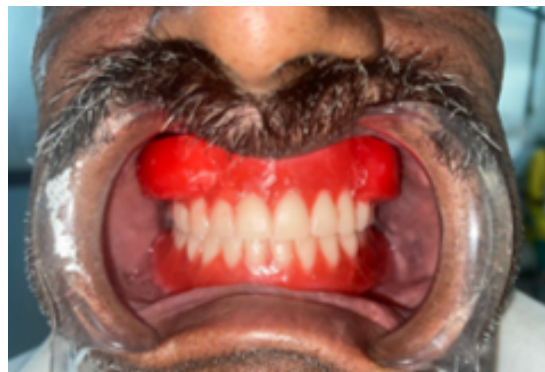

Fig. 2: Moulding of plumper.

2.2. Fabrication of attachment on denture base – (Figure 3)

A 10mm long round casting sprue wax (Renfert GEO CroWax) was cut corresponding to the cheek plumper dimensions. Four pieces of the same dimensions were cut. One sprue wax was heated and attached onto second sprue wax. The attachment between two sprues created an undercut which was used for retention. Similarly, one more set of sprue wax attachment was fabricated. These two sprue attachment sets were heated and attached to trial denture base in relation to cheek plumper.



Fig. 3: Sprue wax attachment.

2.3. Processing of dentures and cheek plumper

After attachment of sprue wax on the maxillary trial denture, the dentures were flaked, packed and cured with heat cure acrylic (Ruthinium Group AcryPolR) The cheek plumper was separately flaked, packed and cured in heat cure acrylic.

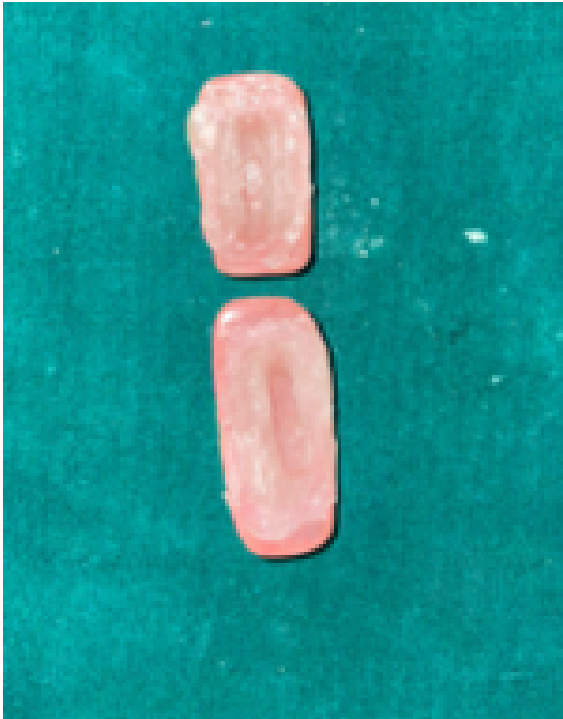


Fig. 4: Cheek plumper with tissue conditioner.

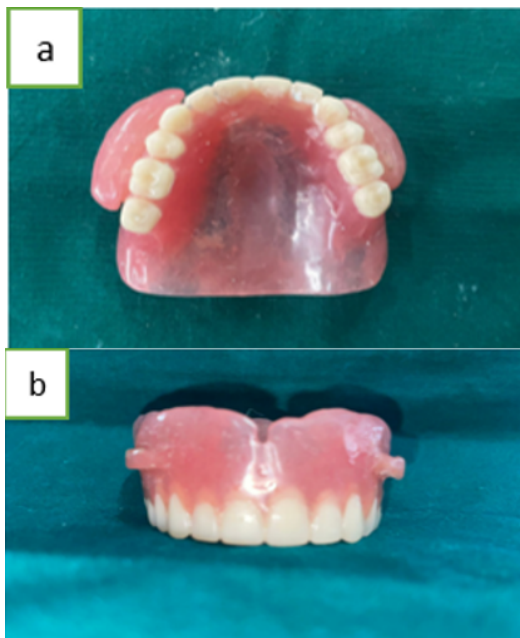


Fig. 5: Maxillary denture with; **a:** Attachment and **b:** Cheek plumper



Fig. 6: Post operative

2.4. Retention using tissue conditioner – (Figure 4)

After retrieval of dentures with attachment and cheek plumper, they were trimmed and polished. The surface of plumper contacting the maxillary denture attachment were trimmed to accommodate for the space for attachment. Tissue conditioner (GC soft Line) was mixed and filled into the trimmed cheek plumper and was approximated onto the attachment creating intimate contact between denture and cheek plumper. It was allowed to set for 20 minutes. After this, the plumpers were detached and trimmed to remove any excess tissue conditioner. Tissue conditioners allowed close approximation of the plumper with the denture and also facilitated easy removal from it.

2.5. Denture placement – (Figure 5)

Complete denture with detachable cheek plumper was inserted in the patient's mouth. The patient was given instructions related to the attachment and detachment of the cheek plumper and was asked to visit for regular follow up.

Patient's sunken cheeks were restored with detachable cheek plumper for aesthetics. (Figure 6)

3. Discussion

Denture aesthetics have a front-line, it is more of synchronization of artificial with natural.^{7,8}

Cheek plumper is one-piece prosthesis with its' attachments near the premolar-molar region that supports the cheek. Cheek plumper is essentially the prosthesis for supplementing and lifting the cheeks.⁹

Such appliances are a vital part of the silhouette of maxillary denture flanges planned by extending the denture

flanges in the mediolateral and anteroposterior directions within physiologic limits.

This is principally for supporting and plumping the cheek to enhance aesthetics. A cheek plumper can be of two types: detachable and undetachable.

It is seen that undetachable cheek plumper have certain drawbacks like increased weight which could hinder retention of the maxillary denture and make it problematic to insert. Furthermore, it cannot be used in patients with restricted mouth opening.¹⁰ Also, undetachable prosthesis is difficult to clean.

To overcome the shortcomings of undetachable cheek plumper, detachable cheek plumper has proved to be more advantageous. In a detachable plumper prosthesis, plumper part can be separated from the complete denture as per the patient's requirements.

The conventional cheek plumper can also lead to muscle fatigue due to constant use. In the present case detachable plumper prosthesis not only reduce weight of the final prosthesis but allow for comfort in placement of the prosthesis.

In the past, various attachments have been used for a detachable cheek plumper like magnets, clips, buttons. Few authors have used stud attachments, wire-retained cheek plumper, and orthodontic elastic modules.¹¹ Clinician can choose the appropriate attachment as per patient's dexterity.

The magnet retained prosthesis have been used but they display poor corrosion resistance and loss of magnetism over a period of usage.¹² To overawed these disadvantages, soft liner has been used. Due to the resiliency of the soft liner, it can be used for close approximation of the plumper with the denture and simplified exclusion from the denture when required.

Nevertheless, there are certain boundaries allied with the soft liner like loss of resiliency over a period of time that necessitates its replacement over a period of 6-8 months.

But the aesthetic enhancement and comfort brought lifts the self-esteem of patient surpassing the disadvantages of this procedure.

4. Conclusion

Prosthodontic rehabilitation of an edentulous patient doesn't edge to mere replacement of missing teeth. Patients are gradually demanding enhancement in appearance. This article presents a simple, cost effective, non-invasive technique to improve esthetics in completely edentulous individuals with sunken cheeks. The prosthesis acts as a substitute to improve facial appearance in patients with hollow cheeks. Detachable cheek plumpers can successfully reinstate the cheek contours to suitable parameters without affecting the purpose of conventional denture.

5. Source of Funding

No financial support was received for the work within this manuscript.

6. Conflict of Interest

None declared.


References

1. Rifkin WJ, Kantar RS, Ali-Khan S. Facial disfigurement and identity: A review of the literature and implications for facial transplantation. *AMA J Ethics*. 2018;20(4):309–23.
2. Tautin S. Denture esthetics is more than tooth selection. *J Prosthet Dent*. 1978;40(2):127–30.
3. Bains JW, Elia JP. The role of facial skeletal augmentation and dental restoration in facial rejuvenation. *Aesthetic Plast Surg*. 1994;18(3):243–6. doi:10.1007/BF00449788.
4. Jamieson C. Geriatrics and the denture patient. *J Prosthet Dent*. 1958;8(1):8–13. doi:10.1016/0022-3913(58)90004-0.
5. Young HA. Denture esthetics. *J Prosthet Dent*. 1956;6(6):748–55. doi:10.1016/0022-3913(56)90071-3.
6. Zwetchkenbaum SR, Shay K. Prosthodontic considerations for the older patient. *Dent Clin North Am*. 1997;41(4):817–45.
7. Clairf P. Complete denture esthetics. *J Prosthet Dent*. 2005;93:386–94.
8. Waliszewski M. Restoring dentate appearance: A literature review for modern complete denture esthetics. *J Prosthet Dent*. 2005;93(4):386–94. doi:10.1016/j.prosdent.2005.01.004.
9. Natarajan P, Kumar SM, Natarajan S, Raza FB. Management of shrunken cheeks by hollow buccal cheek plumper prosthesis. *J Pharm Bioallied Sci*. 2021;13(Supple 1):S875–7.
10. Verma N, Chitre V, Aras M. Enhancing appearance in complete dentures using magnet retained cheek plumpers. *J Indian Prosth Soc*. 2004;4(J Indian Prosth Soc):35–8.
11. Keni NN, Keni NN, Chitre V. Customised attachments retained cheek plumper prosthesis: a case report. *J Indian Prosthodont Soc*. 2012;12(3):198–200. doi:10.1007/s13191-012-0132-y.
12. Riley M, Williams A, Speight J, Walmsley A, Harris I. Investigations into the failure of dental magnets. *Int J Prosthodont*. 1999;12(3):249–54.

Author biography

Drishti Nagi, Post Graduate  <https://orcid.org/0000-0001-9679-2812>

Haritha Suresh, Post Graduate

Rajeshwari C L, Professor  <https://orcid.org/0000-0003-2866-1268>

Srivatsa G, Professor and Principal  <https://orcid.org/0000-0001-7996-3763>

Cite this article: Nagi D, Suresh H, Rajeshwari C L, Srivatsa G. Enhancing aesthetics using detachable cheek plumper in conventional dentures- A clinical report. *IP Ann Prosthodont Restor Dent* 2022;8(4):233-236.