

Prosthodontic Rehabilitation - Past, Present and Future

Rajeev Gupta^{1,*}, Archana Nagpal², Vibhuti Sharda³, Shraddha Swain⁴,
Monica Bhadwal⁵

¹Professor, ²Professor & HOD, ^{3,4,5}Post Graduate Student, Dept. of Prosthodontics
Himachal Dental College, Sundernagar, HP

*Corresponding Author

Rajeev Gupta

Professor, Dept. of Prosthodontics, Himachal Dental College, Himachal Pradesh

E-mail: drajeev123@gmail.com

Abstract

Prosthodontics has come a long way, from ivory teeth to Ivoclar, from mere denture making to bionics, from plaster impressions to Dentascan, from laborious lab procedures to CAD-CAM and Rapid Prototyping, yet each day is bringing in its wake a new advancement, equipping the Prosthodontist with novel concepts, materials, technology and techniques for improved rehabilitation of patients. As we discover new vistas of evolution, this article briefly overviews the journey from the past, through the present and into the bright future of the diverse field of Prosthodontics.

Key words: Prosthodontic rehabilitation, Evolution of prosthodontics, Paradigm shift in prosthodontics.

Introduction

The human civilization has developed drastically, from the stone-age to this era of super computers and heart transplants. The field of Prosthodontics has not been left untouched by this evolution. So rapid has been this progress, it is apt to call it revolution. Although tooth replacement started as early as 3000BC, in the early 1500s dentistry expanded from mere ablation to reconstruction, marking the advent of "Prosthodontics". The first book about teeth, "Artzney Buchlein", was published in 1530 while the dental text in English appeared in 1685, titled "The operator for the teeth".¹

The ADA defines Prosthodontics as "the dental specialty pertaining to the diagnosis, treatment planning, rehabilitation and maintenance of the oral function, comfort, appearance and health of patients with clinical conditions associated with missing or deficient teeth and/or oral and maxillofacial tissues using biocompatible substitutes."²

History has recorded the use of beeswax by Pfaff in 1736³ and Plaster of Paris & Gutta Percha as impression materials.⁴ Prosthodontic rehabilitation of edentulous patients began with wooden and ivory dentures, until they were replaced by metal and subsequently vulcanite in 1851. Denture teeth were made of ivory, sea shells and bone. Ancient Egyptians had wired these materials to remaining teeth- the ancient fixed partial denture perhaps! The earliest implants were seashells hammered into the jaw as early as 3000BC by the Mayans.

Once limited to denture fabrication, prosthetic rehabilitation has grown and diversified to encompass fixed restorations, implants, aesthetic enhancements, smile designing, full mouth rehabilitation, surgical stents, maxillofacial prosthesis for congenital and trauma generated defects, occlusal rehabilitation, amelioration of Temporomandibular joint disorders and even sleep apnea. The future holds new vistas for further expansion.



Fig 1. Dentures showcased in the Harvard Dental School Museum Collection (HDSM 1874) in the Francis A. Count way Library of Medicine

Current Demographics of Edentulousness in India:
Owing to spread of education and awareness, increasing

per capita income and more life expectancy India's geriatric population has reached 77 million, comprising

7.7% of the total population. Out of the 500 randomly selected subjects for the study, 32% were found to be either partially or completely edentulous.⁵ With the oral-systemic connection well established, increasing life-expectancy and changing lifestyles more patients are now turning up at the Prosthodontists' doorstep. Prosthodontic rehabilitation has metamorphosed in all its aspects, which will be discussed in brief under various ramifications of Prosthodontics.

Diagnosis and Treatment Planning: In diagnosis and treatment planning, the faculties of sight and palpation were all that our predecessors had, until they were equipped with mouth-mirrors and probes; we are now progressing from the age of roentgenography to the age of radiovisuography, 3D CBCT, Interactive Computed Tomography, Dentascan and bone mapping. Easy access to knowledge worldwide has enabled the Prosthodontist to reach accurate diagnosis, plan efficacious treatment and render prosthetic rehabilitation par excellence.

Dental Materials and Techniques

This revolution can also be attributed to advances in dental materials and procedures, which have been devised and improved in order to save time and money. Also, they ensure patient comfort and rehabilitation with a durable, functional and aesthetic prosthesis. Accurate prosthetic rehabilitation starts with making an accurate impression. In the early twentieth century the concepts of border moulding and posterior palatal seal emerged and low fusing impression compound, zinc oxide eugenol and agar gained popularity as impression materials. World War II triggered the discovery of alginate as an impression material, which today is available in flavoured, chromatic and a myriad of other forms to choose from. Elastomers, introduced in the 1960s, include polyethers, polysulfides, condensation silicones and most recently introduced addition silicones⁶. Simultaneously, impression techniques have also advanced to selective-pressure technique, wet-field technique, laminate technique, putty-wash technique and a host of techniques to choose from for every clinical situation, be it flabby ridges, or highly resorbed ones, be it for FPDs or implants. We are now standing on the brink of the era of digital and laser impression making, which will radicalize prosthodontic rehabilitation by allowing single sitting rehabilitations in future.

Many resinous and thermoplastic materials were tried as denture base resins, until Dr. Walter Wright introduced Polymethyl methacrylate in 1937. Heat activated PMMA came to be processed by two techniques, namely Compression Moulding and Injection Moulding. The latter, although more expensive, provides stronger and more accurate

dentures. Chemically activated, light activated and microwave polymerized variants of acrylates were also developed over the years. Denture teeth have also been evolved to provide best rehabilitation of form, function and esthetics. Variations like monoplane, semi-anatomic, cross-bite, IPN resin and porcelain teeth have been developed for varied clinical conditions.

Alloys used in prosthodontics have also seen a drift from noble metal alloys to cheaper base metal alloys with controllable properties. Titanium has emerged as an excellent material for implants and has also found its use in RPD frameworks. Investment materials have been updated from silicate bonded investment materials and gypsum bonded investment materials to carbon free phosphate bonded investment materials.

Impression trays, bite registration materials, gypsum products, finishing & polishing materials and other dental materials have been undergoing constant improvisations too. "Fit-checker" materials to indicate pressure points, tissue conditioners and relining materials have simplified post-insertion care of removable prosthodontic patients.

Back in the day, dentures were made purely on the operator's judgement until gradually, in the 19th century concepts of retention, resistance and support were understood, relationship between musculature and dentures was established, the importance of maxillomandibular relations was emphasized and the abstractions of occlusion were developed and comprehended for better rehabilitation. This expansion in knowledge was accompanied by an elaboration of clinical and laboratory processes involved in denture fabrication but today, owing to digital impressions, subtractive CAD-CAM and the additive 3D printing, all these steps can be amalgamated into two clinical appointments.⁷

Complete and Partial Removable Prosthodontics:

Unconventional Complete Dentures like immediate dentures, tooth supported and implant supported overdentures, neutral zone dentures, characterized dentures, Cu-Sil dentures, hollow dentures, metal weighed dentures, prong dentures, hinged dentures, dentures with cheek-plumpers and saliva reservoirs have diversified prosthodontic rehabilitation to cater to every clinical situation. The more recently introduced Biofunctional Prosthetic System dentures, with their unique Ivoclar teeth and microwave polymerized GC Arcon MC dentures meet esthetic demands as well as that of strength and durability. Avenues in CAD-CAM and 3D printed dentures are yet to be explored to their full potential. The future promises even better materials and techniques for rehabilitation of completely edentulous patients and perhaps, a single sitting treatment for even the most complicated clinical situations.

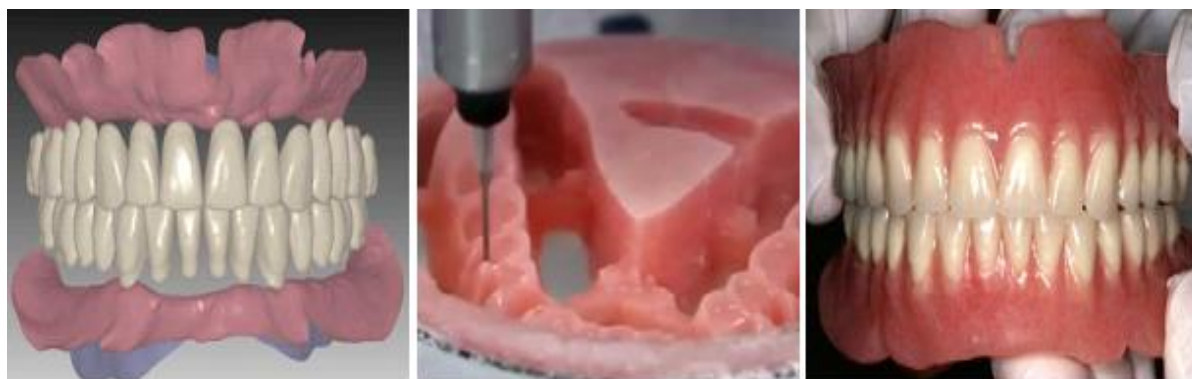


Fig. 2: Dentures being fabricated using CAD-CAM

With the growth in the geriatric population, including a high percentage of partially edentulous patients, the use of Removable Partial Dentures in clinical treatment will continue to be predictable treatment option in clinical dentistry. As rightly stated by Dr. M. M. DeVan, "the preservation of that which remains, is more important than the meticulous replacement of that which has been lost."⁸ This statement has formed the foundation for present removable partial prosthodontics, as in the past, injudicious use of RPDs has led to more harm than good.

The gradual discovery of principles of RPD designing over the past century has led to the formulation, diversification and appropriate placement of each component of the prosthesis, be it direct and indirect retainers or rests and rest seats, major and minor connectors or denture base and replacement teeth. Modified impression techniques have evolved, especially for the distal extension partial dentures, like Selective Pressure Functional Dual Impression technique and the Altered Cast technique. Optical and digital surveyors are replacing conventional surveyors. Polyamide, developed in 1971, is used in "flexible dentures" for clinical situations wherein undercuts are inevitable. Immediate, implant supported, rotational path, Titanium and CAD/CAM RPDs are the current modalities that are dominating removable partial prosthodontic rehabilitation, the future is bringing in laser designed Laser met RPDs offering better aesthetics, precision, strength and refinement.

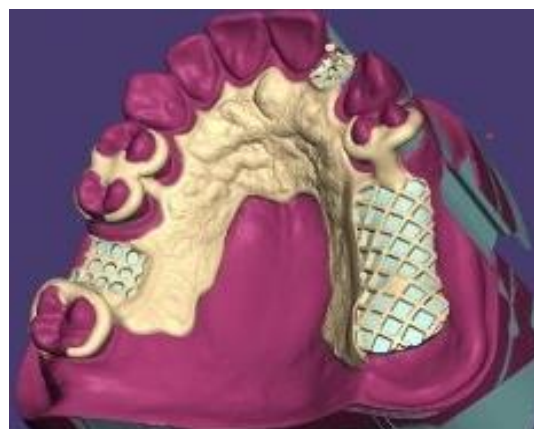


Fig. 3: Exocad's partial denture technology preview software in development

Fixed Prosthodontics

J. Ben Stolpa, in 1975, described an adhesive technique for Fixed Partial Dentures by using aluminium foil and acrylic resin teeth stabilized by a matrix attached to prepared abutment teeth. This marked the beginning of an era of fixed prosthodontics. In 1977, a technique for replacing anterior teeth without tooth preparation, using acid etching was described.⁹ As time progressed various principles of tooth preparation emerged, better impression, temporary and permanent restorative materials have been devised and crowns, bridges, inlays, onlays and veneers have become the order of the day in prosthodontic rehabilitation. With the demand for aesthetics, porcelains emerged as popular restorative materials. Over the years the choice of porcelain has shifted from feldspathic to zirconia, Cerec and more recent all ceramic systems that allow chairside single visit restorations using CAD-CAM. The concept of Dynesthetics and the invention of shade guides, followed by colorimeters and Chromascan have taken esthetics to a whole new level¹⁰. Advances in metallurgy and ceramics have enabled prosthodontists to combine the strength of metal with the esthetics of porcelain. Lasers and air abrasion has revolutionized tooth preparation, while gingival retraction has been simplified by retraction foams and sprays. We are equipped with numerous alternatives like metal, metal-

ceramic, all-ceramic restorations and the more recent, high strength all-ceramics, porcelain laminate veneers and lumineers, which are only likely to diversify in the future.

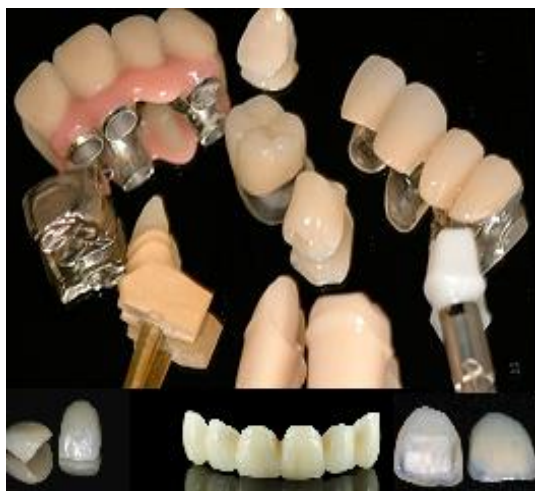

Fig. 4: Fixed Prosthodontics is now replete with novel materials and techniques for the Prosthodontist to choose from

Implant Prosthodontics

From trimmed seashells being hammered into the jaw in 3000BC to flapless, computer-guided implant placement and “teeth-in-an-hour”, implantology has come a long way. In 1952, the milestone discovery of osseointegration was made by Dr. Per-Ingvar Branemark. Ever since implant materials have upgraded from ceramics, carbon and metals to bioglass, plasma sprayed and hydroxyapatite coated titanium. Understanding biological interaction at the implant tissue interface, novel surgical techniques and implant designs have led to meteoric progress. The order of the day has shifted from subperiosteal and transosteal implants to endosseous ones; from osseointegration to osseointegration and osseointegration.

Concepts like platform switching and all-on-four, implant surface modifications and immediate loading protocols are still under the scanner for future advancements.¹¹ Platform Switching has been shown to reduce crestal bone loss around implants by using smaller diameter abutments over wide implant platforms. The concept of “All-on-four” comes with the advantage of decreased number of implants, which are angulated, averting the need for augmentation surgeries in many cases. Once Prosthodontists feared early loading of implants and a delayed, progressive loading approach was embraced; today, research has paved the way for immediate loading protocols, decreasing psychological impact of edentulousness and providing early restoration of esthetics and function. Today, implants are recognized as the treatment of choice for tooth replacement in widely varying cases previously considered hopeless. They are even being used as

denture abutments and are providing retention for maxillofacial prosthesis; new vistas are unfolding every day.

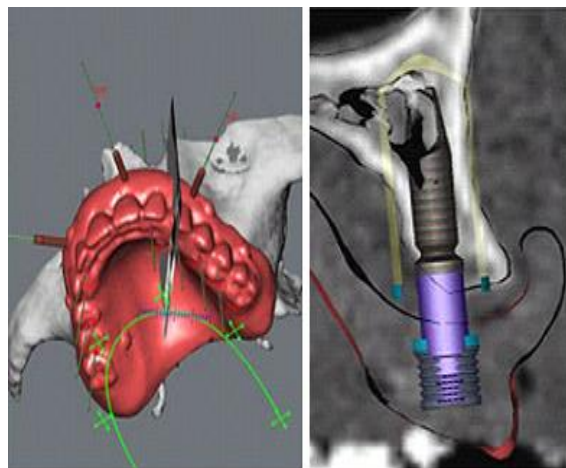


Fig. 5: Computer guided implant placement

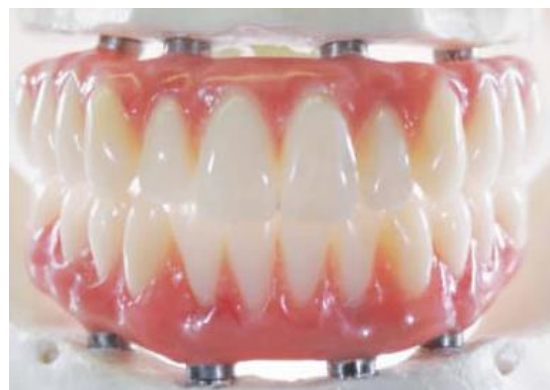

Fig. 6: “All-on-Four”

Maxillofacial Prosthetics

Earlier the loss of an organ was associated with immense psychological trauma and permanent loss of both, form and function but silicon based materials and stereo lithography have led to true rehabilitation of patients with such defects; the future is likely to bring not only the restoration of form but also of function, like not only the replacement of an eyeball, but also the restoration of vision. We are thus moving from mere prosthetics to an era of bionics.




Fig. 7: Prosthetic eyes my soon be able to restore vision

The Future

Who knows, the future of prosthodontic rehabilitation may have tooth regeneration in store. Unlike the dentist of the past, today's prosthodontist has access to state of the art instruments, machinery and techniques like CAD-CAM and Stereo lithography. The future is likely to bring in its wake, an era of bionics, nanotechnology, tissue engineering and stem cell therapy¹². Nanodentistry includes various applications, ranging from the use of nanomaterials for rehabilitation, to drug release with nanospheres that realize tissue formation and possibly even nanorobots for diagnostic and therapeutic purposes.




Fig. 8: Nanorobots for tooth preparation- the possible future of nanodentistry¹³

Conclusion

With the paradigm shift from removable to fixed and ultimately "integrated" or implant based prosthodontic rehabilitation; one must remember that current trends cannot be the answer to every clinical situation. Removable prosthodontics can never be a thing of the past. It is an inseparable part of prosthodontic rehabilitation that we must carry into the future, with all possible additions, advancements and expansions. As we usher in an era of fixed and integrated prosthodontics, an era of digitalization and nanotechnology an even brighter future awaits us.

Conflict of Interest: None

Source of Support: Nil

References

1. Hobkirk JA. Prosthodontics: A Past with a Future? J Can Dent Assoc. 2005;71(5):326. American Dental Association. "Specialty Definitions: Definitions of Recognized Dental Specialties"
2. Ward G. Impression materials and impression taking—an historical survey. Brit Dent J. 1961;110(4):118-119.
3. Giordano R. Impression materials: basic properties. Gen Dent. 2000;48:510-516.
4. Reddy et al. Epidemiological survey on edentulousness. The Journal of Contemporary Dental Practice. July-Aug. 2012. 13(4):562-570.
5. Asgar K. Elastic impression materials. Dent Clin N Am. 1971;15(1):81-98.
6. Maeda Y, Minoura M, Tsutsumi S, Okada M, Nokubi T. A CAD/CAM system for removable denture. Part I: Fabrication of complete dentures. Int J Prosthodont 1994;7:17-21.
7. Stewart KL, Rudd KD, Kuebker WA. Clinical Removable Partial Prosthodontics 2nd ed. Chennai: All India Publishers and Distributer; 2003
8. Donald F. Howe and Gerald E. Denehy: Anterior fixed partial denture utilizing the acid etch technique and a cast metal frame work. J. Prosthet. Dent., 37(1):28-31, 1977.
9. J.D. Brewer et al. Dent Clin N Am 48 (2004) 341-358.
10. Misch CE. Contemporary implant dentistry. 3rd ed. St. Louis: Mosby; 2007.
11. Zandparsa R. Latest biomaterials and technology in dentistry. Dent Clin N Am 2014;58:113-134.
12. Frutas RA. JR. What is nano medicine? Nanomedicine. 200;1:2-9.
13. Verma, et al.: A critical review of the implication of nanotechnology in modern dental practice. Natl J Maxillofac Surg. 2010;1:41-4.