

Content available at: <https://www.ipinnovative.com/open-access-journals>

IP Annals of Prosthodontics and Restorative Dentistry

Journal homepage: <https://www.aprd.in/>

## Case Report

# Obturator prosthesis with esthetic retainer for hemimaxillectomy patient: A case report

R. Ranjith<sup>1</sup>, B. Devi Parameswari<sup>1,\*</sup>, H. Annapoorni<sup>1</sup>, S. Dhevishri<sup>1</sup>

<sup>1</sup>Dept. of Prosthodontist, Meenakshi Ammal Dental College and Hospital, Chennai, Tamil Nadu, India



### ARTICLE INFO

#### Article history:

Received 16-07-2022

Accepted 03-11-2022

Available online 24-11-2022

#### Keywords:

Obturator

Modeling wax

### ABSTRACT

Congenital or acquired, intraoral or extraoral, traumas or carcinomas are known to produce psychological imbalances in patients with the least expectations of returning to their normal lives. Oral carcinomas are the fifth most common of all. The major goals of rehabilitation are such patients are to restore function, speech, swallowing, and aesthetics. However, there are many limitations in achieving these goals, an obturator prosthesis remains as the first line of choice in these maxillectomy patients.

This is an Open Access (OA) journal, and articles are distributed under the terms of the [Creative Commons Attribution-NonCommercial-ShareAlike 4.0 License](https://creativecommons.org/licenses/by-nc-sa/4.0/), which allows others to remix, tweak, and build upon the work non-commercially, as long as appropriate credit is given and the new creations are licensed under the identical terms.

For reprints contact: [reprint@ipinnovative.com](mailto:reprint@ipinnovative.com)

## 1. Introduction

The maxillary defect is the most common intraoral defect, arising due to the resection of carcinomas. The surgical resection leads to defects involving any portion of the hard and soft palate, alveolar ridges and nasal floor. This leads to restricted mouth opening, impaired speech and impaired function with leakage of fluid into the nasal cavity.<sup>1</sup> The rehabilitation of intraoral defect can be done either surgically or prosthetically. The prosthesis for these types of defects is obturator prostheses. An obturator is a disc or plate which is used to cover the maxillary defect or opening post-removal of total or partial maxillary structures.<sup>1</sup>

Prosthetic rehabilitation of these defects has been in practice for many years. This was used by Ambrose Pare in the 1500s to close a maxillary defect using artificial material. These obturator prostheses were used most often for congenital than acquired defects. In 1956, Steadman described the use of acrylic resin prosthesis to close palatal defects.<sup>2</sup>

The most common indications for an obturator prosthesis are –

1. Serves as a temporary prosthesis during the healing period from surgical intervention
2. When surgical primary closure is contraindicated
3. To restore aesthetics for social and psychological support
4. When reconstructive surgery is contraindicated due to the patient's age and local avascular condition of tissues
5. To restore masticatory function
6. When the patient is susceptible to recurrence of the lesion.<sup>3</sup>

All palatal defects are mostly acquired due to the resection of carcinomas of the palate and paranasal sinuses. The extent of the resection plays an important role in achieving the prosthesis's retention, stability, and support. The presence of remaining natural teeth improves the retention and stability of the prosthesis. Prosthodontic treatment for acquired defects patients is divided into three rehabilitation phases namely surgical, interim, or post-surgical and definitive prosthetic phases.<sup>4</sup>

\* Corresponding author.

E-mail address: [drdeviparameswari@gmail.com](mailto:drdeviparameswari@gmail.com) (B. D. Parameswari).

This case report details a patient with one such palatal defect who was rehabilitated with a definitive prosthesis for restoring her aesthetics and functional harmony.

## 2. Case Report

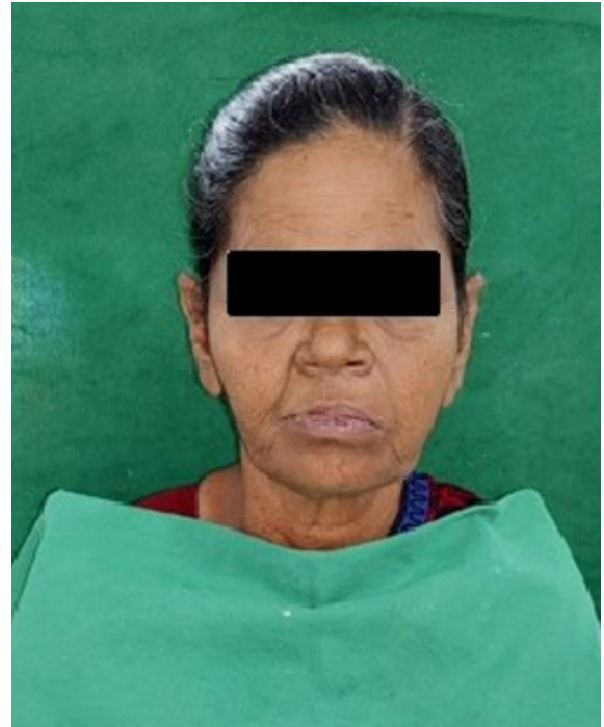A 55-year-old female patient reported to the department of prosthodontics six months after surgery (Figure 1). Her chief complaint was the inability to masticate food and the unlikely appearance since the surgery. The patient has undergone Hemi-maxillectomy for carcinoma of the palate post histopathological findings and clinical correlations. The surgical site was the right maxillary palate and buccal sulcus area involving the teeth in the right maxillary region. (Figure 2)

On intraoral examination, complete healing of the surgical site was evident. The missing teeth were 11, 12, 13, 14, 15, 16, 17 & 18.

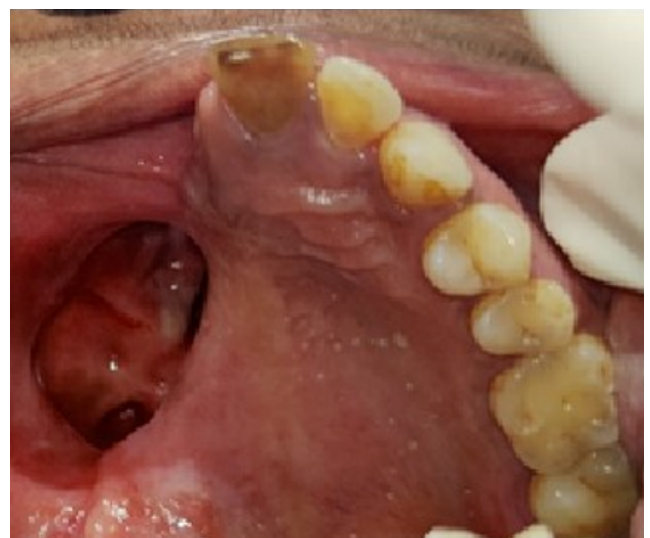The treatment plan was rehabilitation using a definitive obturator.

1. The primary maxillary and mandibular impressions were taken using irreversible hydrocolloid alginate (Hydrogum 5, Zhermack, Italy) and the defect was recorded using an impression compound. The impression was poured with dental stone (Gyproc, Prevest Denpro, Jammu, India) to produce the positive cast.
2. The primary cast was surveyed and the design of the prosthesis was planned. (Figure 3)
3. Splinted crowns were planned in 21, 22, and 23 where the necessary clinical steps were followed and the final impression was made using polyvinyl siloxane impression material (Aquasil Lv ultra, smart wetting impression, Dentsply, Detrey GmbH, Germany) along the defect been recorded using green stick compound. (Figures 4 and 5)
4. Metal try -in with precision ball attachments were checked for fit and clearance (Figures 6 and 7)
5. Splinted metal-ceramic crowns were cemented using glass ionomer luting cement (GC Fuji II - GC Corporation, Tokyo) (Figure 8) and picked up with polyvinyl siloxane impression material.
6. The chrome-cobalt framework trial with rest and rest seats in 24, 25, and 26, 27 regions with embrasure clasps as added retention was checked intraorally. (Figure 9)
7. Interocclusal record registration was done along the defect side using occlusal rims fabricated using modeling wax (Hindustan Modelling wax no:2, India). (Figure 10)
8. Acrylic denture teeth were set on modeling wax and a trial for teeth arrangement and occlusion was verified (Figure 11)

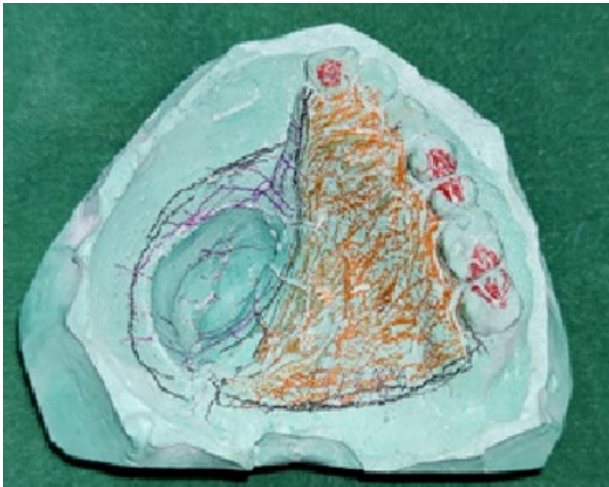
9. The final hollow bulb definitive obturator prosthesis was processed conventionally and inserted into the patient's mouth and the prosthesis was checked for occlusion, retention, and stability (Figures 12 and 13)
10. The patient was reviewed and recalled at regular intervals for hygiene maintenance and tissue health.



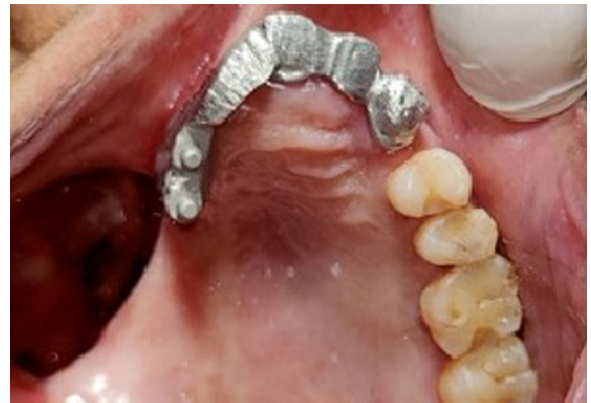**Fig. 1:** Extraoral view



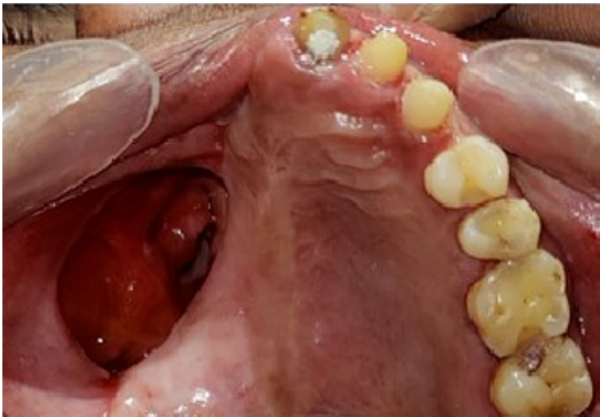**Fig. 2:** Intraoral maxilla view with defect.



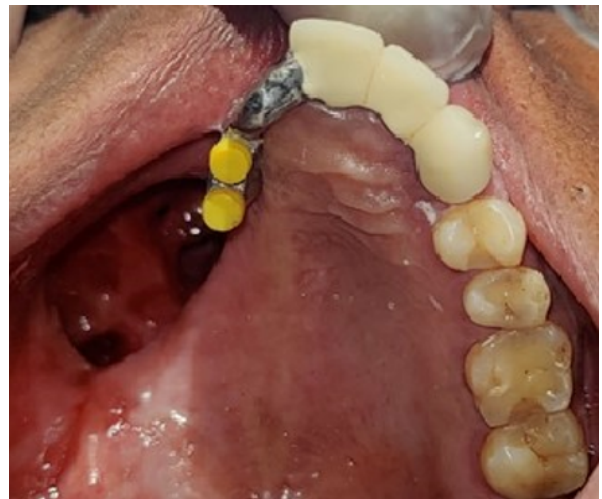**Fig. 3:** Surveyed master cast.



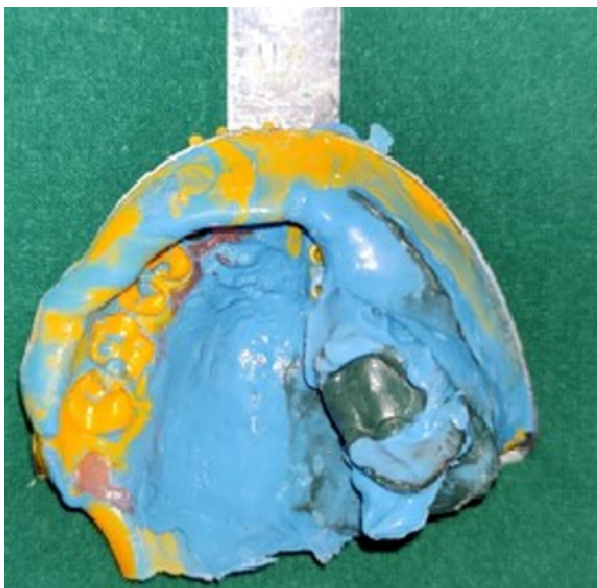
**Fig. 6:** Metal trial with ball attachments;



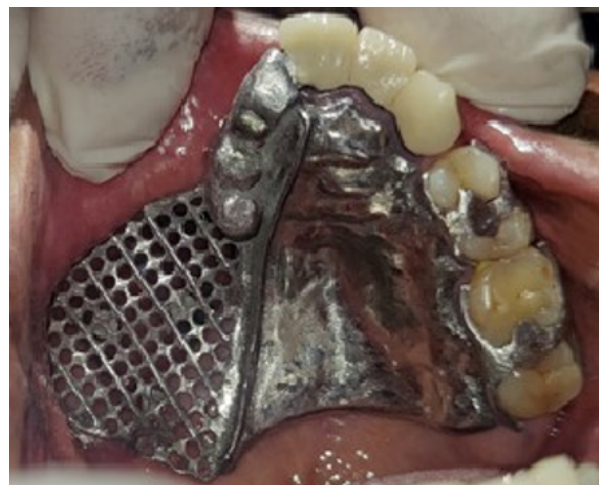**Fig. 4:** Mouth preparation.



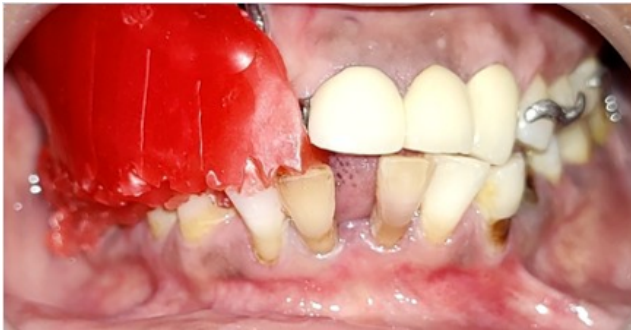**Fig. 7:** Splinted crowns with housings



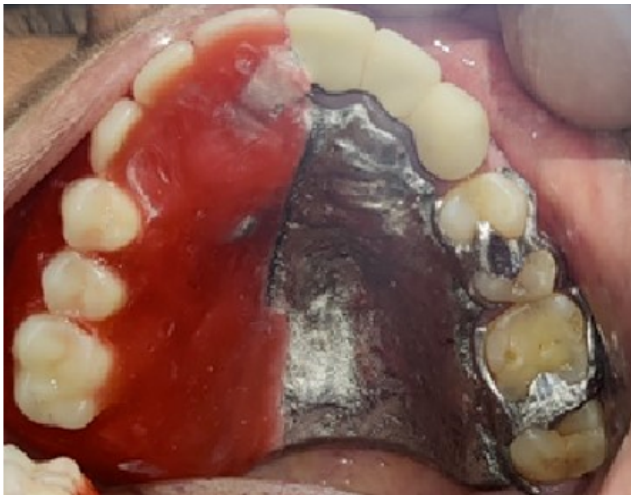**Fig. 5:** Final impression



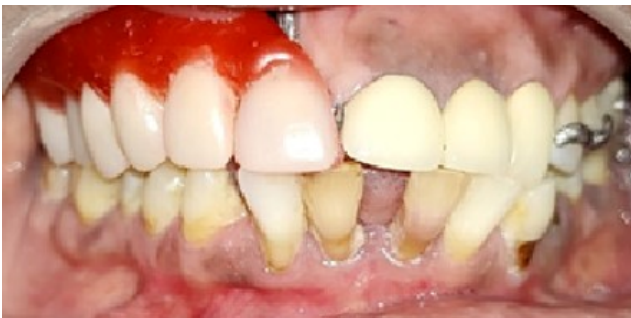**Fig. 8:** Framework trial



**Fig. 9:** Interocclusal record registration



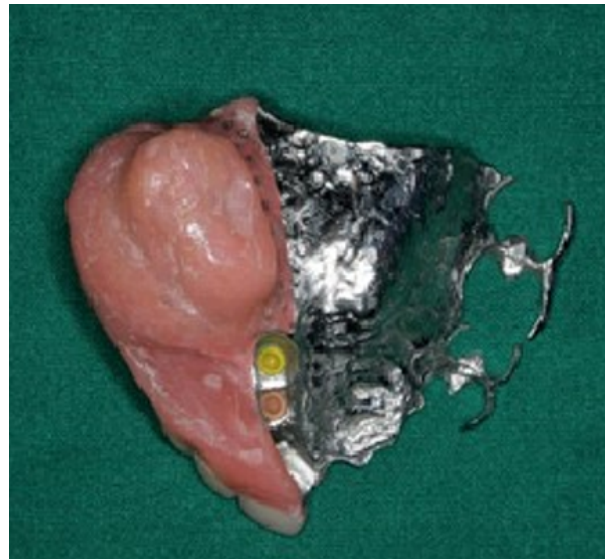**Fig. 10:** Wax trial – occlusal view



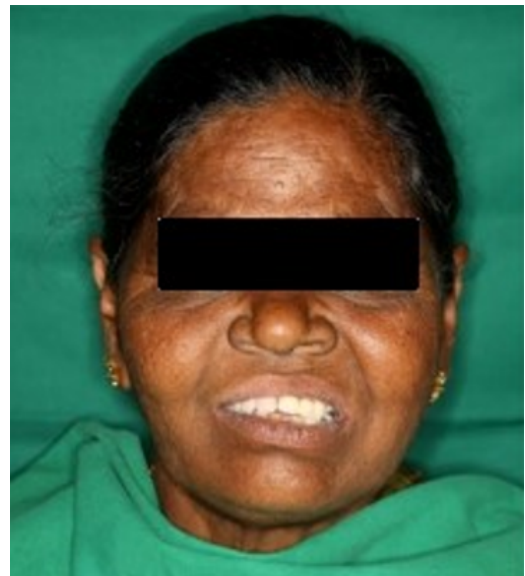**Fig. 11:** Wax trial – frontal view

### 3. Discussion

A definitive obturator is indicated only when the surgical scar tissue heals completely. Obturator might get displaced superiorly along the defect due to the masticatory stress or tend to drop lacking occlusal contact.<sup>5</sup> This degree of movement varies according to the remaining number of natural teeth, their position, size and extent of the defect, the amount and configuration of the remaining palatal area, the height of the alveolar ridge, lining of the mucosal defect, and



**Fig. 12:** Final definitive obturator



**Fig. 13:** Post op – at the smile

the available undercuts. Compromised retention, stability and support are the common issues for rehabilitating patients who have had a maxillectomy.<sup>6</sup> The height and contour of the residual ridge, remaining natural teeth and preservation of alveolar bone adjacent to the defect are important restorative factors. Sound natural teeth provide retention by the bracing components of the framework and the attachments. This help to reduce the movements in three different planes.

Obturator abutments adjacent to the defects are subjected to excessive rotational forces, hence fixed splinting of some or all teeth is indicated for stress dissipation which is directed towards the primary abutment teeth. When the

remaining teeth are located unilaterally, an extra-coronal retainer might provide huge benefits in minimizing the vertical movement of the prosthesis within the defect.<sup>7</sup>

The basic principles of the design of removable partial dentures should be followed while designing the framework of an obturator prosthesis.<sup>8</sup> Major connectors should be rigid, rests and rest seats should direct the forces along the long axis of the teeth, guiding planes should facilitate stability and retention should be within the limits of periodontal support. The height of the lateral wall of the defect can be utilized for indirect retention.

Direct retainers used commonly are the cast clasps. In this case, As the abutment tooth which aids in retention is the central incisor in the esthetic zone, retainer planned is the extra coronal precision ball attachment.<sup>9</sup> These attachments do not display metal in the esthetic zone and still provide better retention.

The critical factor for stability is occlusion.<sup>10</sup> Maximal occlusal forces in centric and eccentric movements are necessary to minimize the displacement of the prosthesis and resultant forces on the underlying structures. Acrylic resin teeth with reduced occlusal contact are often indicated in this kind of situations.<sup>11</sup>

#### 4. Conclusion

Obturator prosthesis with precision attachment as direct retainer prevents the display of metal in the esthetic zone. The denture also achieves better stability and support. The patient is comfortable with denture, which aids in improved speech, prevents fluid regurgitation and enhances esthetics. Though it is challenging to improve the quality of life for these patients compared to other inabilities, these can be achieved with the skill, knowledge, and experience of the clinicians.<sup>12</sup> Hence, these problems can be minimized with a team approach of skill and experience at all stages of this treatment to keep the patient under regular review and healthy function.

#### 5. Source of Funding

No financial support was received for the work within this manuscript.

#### 6. Conflict of Interest


None declared.

#### References

- Chalian VA, Drane JB, Standish SM. Multidisciplinary practice. In: Maxillofacial prosthetics. Baltimore: The Williams and Wilkins Co; 1971. p. 133–48.
- Desjardins RP. Obturator prosthesis design for acquired maxillary defects. *J Prosthet Dent.* 1978;39(4):424–35. doi:10.1016/s0022-3913(78)80161-9.
- Nidiffer TJ, Shipmon TH. The hollow bulb obturator for acquired palatal openings. *J Prosthet Dent.* 1957;7:126–34. doi:10.1016/0022-3913(57)90016-1.
- Beumer III, Curtis TA, Firtell DN. Maxillofacial rehabilitation. Prosthodontic and surgical considerations. Toronto, London: The C.V. Mosby Co., St Louis; 1979. p. 188–243.
- Parameswari BD, Rajakumar M, Jagadesaan N, Annapoorni H. Case presentation of two maxillectomy patients restored with two-piece hollow bulb obturator retained using two different types of magnets. *J Pharm Bioallied Sci.* 2017;9(Suppl 1):S252–6. doi:10.4103/jpbs.JPBS\_85\_17.
- Dhevishri S, Parameswari BD, Annapoorni H, Shankar MSS. Immediate and interim prosthodontic management of the post-surgical maxillectomy patient using obturator prosthesis: A case report. *Int Dent J Stud Res.* 2021;9(4):188–93.
- Armany MA. Basic principles of obturator design for partially edentulous patients. Part II: design principles. *J Prosthet Dent.* 1978;40(6):554–62. doi:10.1016/0022-3913(78)90065-3.
- Armany MA. Basic principles of obturator design for partially edentulous patients. Part II: Design principles. *J Prosthet Dent.* 1978;40(6):656–62. doi:10.1016/0022-3913(78)90065-3.
- Academy of denture prosthetics principles, concepts, and practices in prosthodontics. *J Prosthet Dent.* 1989;61(1):88–109.
- Wiens JP. Acquired maxillofacial defects from motor vehicle accidents: Statistics and prosthodontic considerations. *J Prosthet Dent.* 1990;63(2):172–81. doi:10.1016/0022-3913(90)90102-i.
- Zarb GA. The maxillary resection and its prosthetic replacement. *J Prosthet Dent.* 1967;18(3):268–81. doi:10.1016/0022-3913(67)90193-x.
- Buckner H. Construction of a denture with hollow obturator, lid, and soft acrylic lining. *J Prosthet Dent.* 1974;31(1):95–9. doi:10.1016/0022-3913(74)90224-8.

#### Author biography

**R. Ranjith**, Post Graduate

**B. Devi Parameswari**, Associate Professor  <https://orcid.org/0000-0002-7593-4591>

**H. Annapoorni**, Professor and HOD

**S. Dhevishri**, Post Graduate

**Cite this article:** Ranjith R, Parameswari BD, Annapoorni H, Dhevishri S. Obturator prosthesis with esthetic retainer for hemimaxillectomy patient: A case report. *IP Ann Prosthodont Restor Dent* 2022;8(4):228-232.