

Content available at: <https://www.ipinnovative.com/open-access-journals>

IP Annals of Prosthodontics and Restorative Dentistry

Journal homepage: <https://www.aprd.in/>

Case Report

Comprehensive management of mutilated dentition with fixed mandibular implant prosthesis and maxillary overdenture- A 6 year follow-up case report

Kiran Awchat^{1,*}, Parag Dua², I D Roy², Deepa Vinod Bhat³

¹Dental Centre, Leh, India

²Armed Forces Medical College, Pune, Maharashtra, India

³Awadh Dental College and Hospital, Jamshedpur, Jharkhand, India



ARTICLE INFO

Article history:

Received 12-07-2022

Accepted 23-08-2022

Available online 30-09-2022

Keywords:

Mutilated Dentition

Maxillary Overdenture

Mandibular Implant fixed prosthesis

ABSTRACT

Rehabilitation of mutilated dentition is esthetic and functional challenge. The present condition of dentition, patient's level of motivation for maintaining oral hygiene, social status etc are the key factors to successful rehabilitation. Maxillary teeth supported overdenture against mandibular complete denture is a potential risk for enhancing residual ridge resorption of mandibular arch. In such situation mandibular implant prosthesis is a better treatment option. In this case report a comprehensive management of patient with mutilated dentition has been carried out in phased manner. Here three roots with healthy periodontium were preserved in maxillary arch. Fixed implant prosthesis was made in mandibular arch. Presently patient has been followed up for 6 years and found to be highly satisfied and having a good oral hygiene. Maxillary overdenture against mandibular fixed implant prosthesis should be considered as effective rehabilitative modality in rehabilitating such cases.

This is an Open Access (OA) journal, and articles are distributed under the terms of the [Creative Commons Attribution-NonCommercial-ShareAlike 4.0 License](https://creativecommons.org/licenses/by-nc-sa/4.0/), which allows others to remix, tweak, and build upon the work non-commercially, as long as appropriate credit is given and the new creations are licensed under the identical terms.

For reprints contact: reprint@ipinnovative.com

1. Introduction

Rehabilitation of a failing dentition to esthetic and functional state is a challenge. The present condition of dentition, patient's level of motivation for maintaining oral hygiene and social status are key factors to successful rehabilitation. Maxillary tooth supported overdenture opposing a conventional mandibular complete denture is a potential risk for enhancing residual ridge resorption of mandibular arch.¹ In such situation mandibular implant prosthesis is a better treatment option. In this case report a comprehensive rehabilitation of patient with mutilated dentition was carried out in a staged manner. It involved complete rehabilitation of partially edentulous maxillary arch with a teeth supported overdenture and completely edentulous mandibular arch with fixed implant prosthesis

with special emphasis on prosthetically driven implant placement. Further the patient was on a regular follow up till 6 years, with minimal complaints.

2. Case Report

A 58 year old male patient reported with inability to chew due to multiple decayed and broken teeth and poor aesthetics. Patient had poor oral hygiene maintenance. He had visited dentist very few times due to fear of unknown. There was no history of radiotherapy or any systemic illness. Intraoral examination revealed multiple carious, fractured teeth and root stumps in maxillary and mandibular arch. The clinical findings were correlated with the radiographic finding (Figure 1).

* Corresponding author.

E-mail address: drklawchat@gmail.com (K. Awchat).

2.1. Diagnosis

Based on clinical and radiographic finding of patient, a diagnosis of mutilated dentition with chronic apical periodontitis with multiple teeth was made.

2.2. Treatment objectives

Restoration of aesthetics and function. Patient education on oral hygiene maintenance.

2.3. Treatment plan

Fabrication of maxillary overdenture opposing a mandibular implant supported fixed prosthesis was planned in four phases. Phase 1 involved extraction of teeth with poor prognosis and counselling for maintaining oral hygiene and diet. Phase 2 included endodontic treatment, tooth preparation and fabrication of dome shaped primary copings with respect to 15, 11 and 25. Following this was fabrication of interim maxillary teeth supported overdenture and mandibular complete denture. Phase 3 involved evaluation of mandible through Cone beam computed tomography (CBCT) for implant planning and ideal position for implant placement. Placement of eight endosteal implant in mandibular arch as planned through diagnostic cast, CBCT and surgical guide for mandibular fixed prosthesis (Figure 2). Then fabrication of maxillary definitive prosthesis. In last phase patient was put on regular follow-up.

2.4. Treatment progress

All the teeth with poor prognosis were extracted. Extraction of teeth resulted into completely edentulous mandible and partially edentulous maxilla with remaining 15, 21 and 25. Endodontic treatment of 15, 21 and 25 was completed and the teeth were prepared for dome shape primary copings (Figure 2). The teeth were prepared such that its occluso-gingival height was minimal, approximately 2mm. The height of primary coping was kept minimal to avoid lateral forces. Interim maxillary overdenture and mandibular complete denture was then fabricated. This interim prosthesis was continued till 3 months. After 3 months the status of maxillary abutment and oral hygiene was observed to be good.

Definitive treatment phase was initiated. Herein mandibular FP-2 prosthesis supported by eight implants and maxillary cast metal denture base over denture was planned. As per Misch the treatment option 5 for mandibular fixed prosthesis was chosen.² Holes of 2 mm diameter were prepared on the mandibular denture at tentative location of implants. These were filled with a radio-opaque marker (gutta-percha). Cone beamed computed tomography was taken with dentures in situ. The CBCT data was co-related with the mandibular diagnostic cast. The data

from mandibular cast was transferred to maxillary denture through 18 gauze stainless steel wire to serve as implant placement guide (Figure 3).

Crestal Incision was placed and extending from left mandibular buccal frenum to right buccal frenum. Mucoperiosteal flap elevated and lingual flaps were tied to each other for unhindered visualisation (Figure 3D). Implant position indicator fabricated earlier was placed and eight endosteal implants (Indident™, Dental Implant System) were placed in mandibular arch and sutures placed. Figure 3E shows post-operative OPG.

After 4 months, second stage surgery was done and prosthetic phase was initiated. A cement retained prosthesis was fabricated. Abutment level Impression made with single step Putty light body (Betasil). The Abutments were checked for parallelism and occlusal clearance. Orientation jaw relation was recorded using existing maxillary denture and transferred to semi-adjustable articulator (Figure 4). The centric relation was made over the acrylic plate fabricated on the implant abutment. The prosthesis was made in three sections as an anterior segment, left posterior and right posterior segment. The left segment was rehabilitated on two implants, anterior segment rehabilitated on four implants and right segment was rehabilitated using two implants (Figure 5). The mandibular fixed prosthesis was cement retained and ensured to have a passive fit.

Border moulding of maxillary arch was done with low fusing impression compound. Tray adhesive (Coltene) was applied to impression tray and light body elastomeric impression material (Betasil) was used for making impression. The maxillary metal denture base was fabricated. Maxillary Complete denture was fabricated against mandibular implant prosthesis with bilateral balanced occlusal scheme.

Presently patient has been followed up for 6 years (Figure 6) and found to be highly satisfied and managing a good oral hygiene. The patient had reported with de-cementation of primary coping of 15.

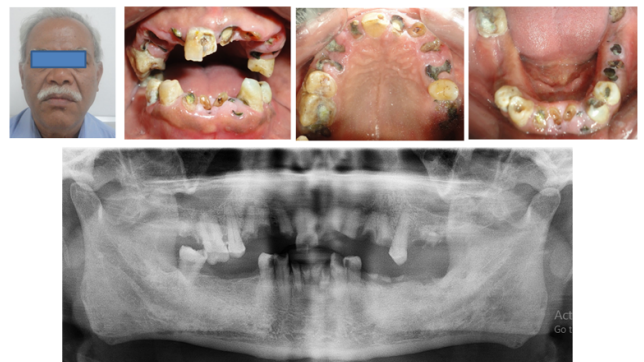


Fig. 1: Clinical photographs and pre-treatment OPG.

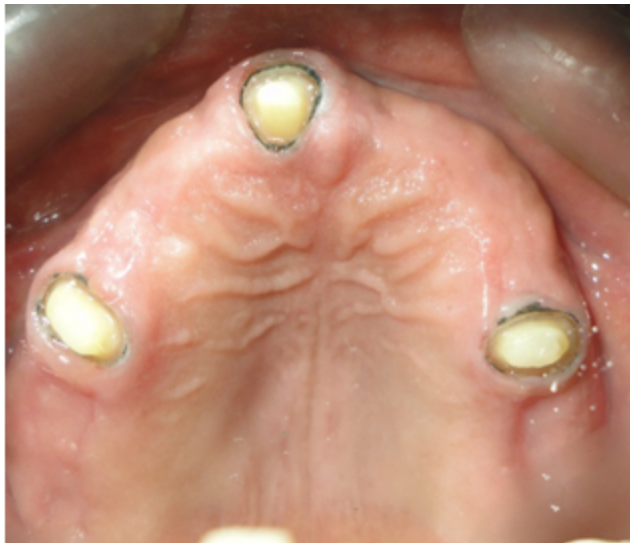

Fig. 2: Prepared maxillary abutment for primary coping.

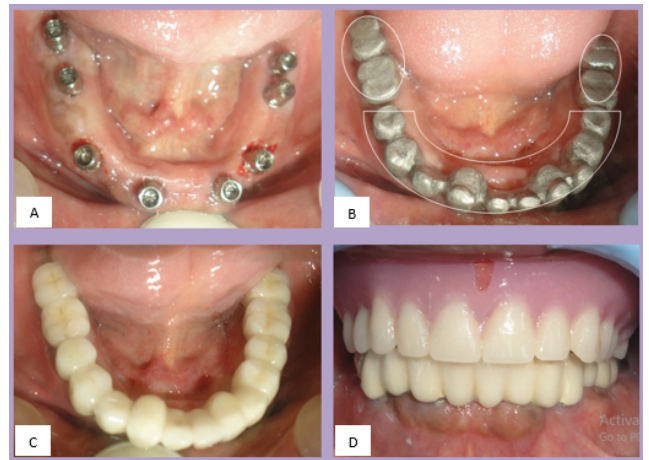


Fig. 4: **A:** Abutment placed; **B:** Metal coping try-in three segments i.e, right posterior, Anterior and left posterior; **C and D:** Completed prosthesis.

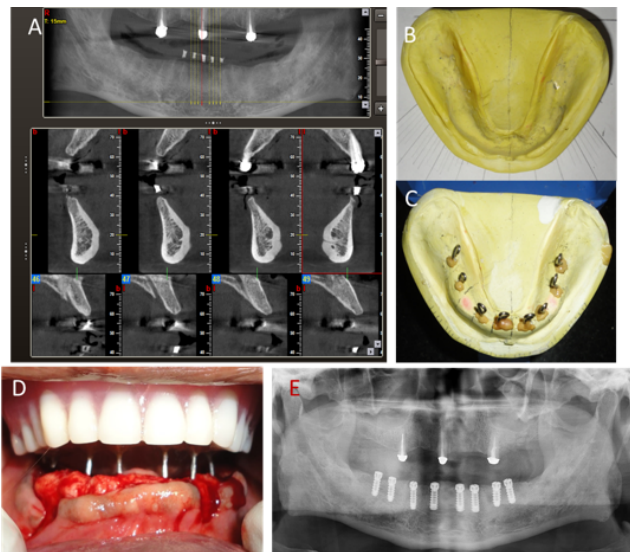


Fig. 3: **A:** Evaluation of bone height, width and density through cone beam computed tomography; **B:** Transferring data to mandibular cast; **C:** Stainless steel wire to make implant placement guide; **D:** Implant placement guide in-situ and **E:** Post-operative OPG.

3. Discussion

In rehabilitating patients with mutilated dentition, the most important factor is boosting their confidence that they are curable. The cause for grossly carious dentition is ignorance of oral hygiene. Patient needs to be motivated for the same to reverse the situation. But when the damage is irreversible returning to normal health is challenging. In this case patient had grossly mutilated dentition leading to multiple extractions resulted into a completely edentulous mandible and maxillary arch with

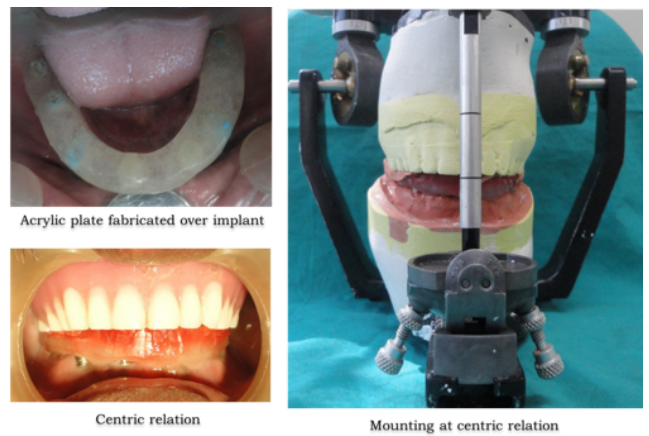


Fig. 5: Recording centric relation.

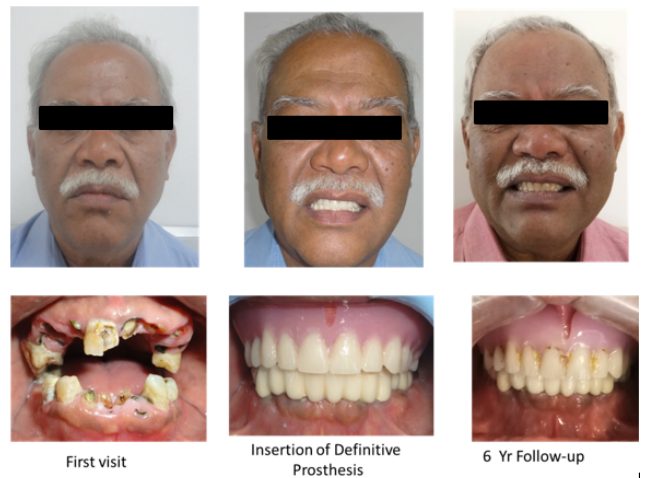

Fig. 6: Pre-operative, post insertion of Definitive Prosthesis and six year follow-up photograph.

remaining tripod abutment (Figure 2) A staged treatment approach was followed for rehabilitating this patient.³

The average denture base area for maxillary arch is more compared to mandible. Adding three teeth as abutments to maxillary arch added to the prosthetic support. led to excessive resorption of mandibular arch.¹ So maxillary tooth supported overdenture against mandibular implant prosthesis was a better option. The options available for rehabilitation of mandibular arch were fixed implant prosthesis or removable implant overdenture. go ahead with fixed implant prosthesis option.

The three abutments in maxillary arch are widely separated giving a tripod support. The average root surface area for maxillary premolar is 213 mm² and 227 mm² respectively which will add to support of the maxillary prosthesis.⁴ Cast metal denture base as it affords maximum rigidity in thin sections, well tolerated by patient and better thermal perception.⁵ In maxillary decreased thickness of acrylic in the abutment region. Cast fracture of denture base when opposing mandibular natural or fixed prosthesis.

The implant system used was Indident™. The number of implants is most crucial for mandibular implant prosthesis. More the number of implants better will be the support. Ideally one implant per missing tooth should be considered for fixed implant prosthesis.²

The choice for selection of cement retained prosthesis over screw retained implant prosthesis was done because literature suggest decreased bone resorption around cement retained prosthesis compared to screw retained prosthesis and these simple to fabricate.⁶

The patient has been regularly followed up on monthly basis for initial months, 3 monthly follow-up for next one year and further 6 monthly follow. Patient had been followed up for 6 years. The mandibular implant showed some amount of crestal bone loss but no signs of failure were observed.

4. Conclusion

In this report the patient has been followed for 6 years. Presence of three widely spaced overdenture abutment in maxillary arch tolerate the forces from mandibular fixed implant prosthesis well. Minimal resorption was seen

in a follow-up of 6 years with no significant complaints from patient. Therefore, maxillary overdenture against mandibular fixed implant prosthesis should be considered as effective rehabilitative modality in rehabilitating such cases.

5. Source of Funding

None.

6. Conflict of Interest


None.


References


1. Sharry J. Complete denture prosthodontics. New York: McGraw-Hill; 1974.
2. Misch C. Contemporary implant dentistry. St. Louis: Mosby Elsevier; 2008.
3. Papaspyridakos P, Chronopoulos V. Transition from failing dentition to complete-arch implant rehabilitation with a staged approach: a 3-year clinical report. *J Prosthet Dent*. 2014;112(3):423–8. doi:10.1016/j.prosdent.2014.01.003.
4. Lakhani K, Vashishth V, Gugnani N. Root surface area measurement of permanent dentition in Indian population - CBCT analysis. *Inform Med Unlocked*. 2017;9:1–5. doi:10.1016/j.imu.2017.05.003.
5. Piermatti J, Winkler S. Metal bases for implant overdentures. *Gen Dent*. 2010;58(5):404–5.
6. Lemos CA, Batista VDS, Almeida DA, Júnior JS, Verri FR, Pellizzer EP, et al. Evaluation of cement-retained versus screw-retained implant-supported restorations for marginal bone loss: A systematic review and meta-analysis. *J Prosthet Dent*. 2016;115(4):419–27.

Author biography

Kiran Awchat, Assistant Professor  <https://orcid.org/0000-0003-2650-9836>

Parag Dua, Associate Professor  <https://orcid.org/0000-0002-9467-1176>

ID Roy, Professor  <https://orcid.org/0000-0001-9099-5723>

Deepa Vinod Bhat, Associate Professor  <https://orcid.org/0000-0002-9527-7269>

Cite this article: Awchat K, Dua P, Roy ID, Bhat DV. Comprehensive management of mutilated dentition with fixed mandibular implant prosthesis and maxillary overdenture- A 6 year follow-up case report. *IP Ann Prosthodont Restor Dent* 2022;8(3):161-164.