

Content available at: <https://www.ipinnovative.com/open-access-journals>

IP Annals of Prosthodontics and Restorative Dentistry

Journal homepage: <https://www.aprd.in/>

## Case Report

# Hollow denture-a solution to post covid total maxillectomy patients: A case report

Aswathi Raghuthaman<sup>1</sup>, Prema<sup>1</sup>, Anu Raveendran<sup>2,\*</sup>

<sup>1</sup>Dept. of Prosthodontics, Rajiv Gandhi University of Health Sciences, Bengaluru, Karnataka, India

<sup>2</sup>The Tamil Nadu Dr. M.G.R. Medical University, Chennai, Tamil Nadu, India



### ARTICLE INFO

#### Article history:

Received 18-03-2022

Accepted 25-04-2022

Available online 21-05-2022

#### Keywords:

Hollow denture

Light weight denture

Resorbed ridge

Inter arch distance

### ABSTRACT

Retention, stability and support are the basic principles on which the success of a complete denture. The ability lies in applying these principles professionally in cases with total maxillectomy that are narrow and constricted with increased interarch space. This will provide decreased support, retention and stability and also increased weight of the processed denture will compromise them further and try to dislodge denture. This article highlights a technique for the fabrication of a hollow maxillary complete denture in situation where there is no ridge tissue due to total maxillectomy followed by post covid mucormycosis. Weight of a denture may be a contributing factor to the successful resolution of a patient's problem; the hollow denture can be considered as one of the treatment modalities. The advantage of a hollow maxillary or mandibular denture is the reduction of excessive weight of acrylic resin, which normally replaces lost alveolar ridge in the interridge space of the denture wearer. This clinical report describes a case report of Total maxillectomy patient with resorbed ridges where a simplified technique of fabricating a light weight hollow maxillary complete denture was used for prosthodontics rehabilitation.

This is an Open Access (OA) journal, and articles are distributed under the terms of the [Creative Commons Attribution-NonCommercial-ShareAlike 4.0 License](https://creativecommons.org/licenses/by-nc-sa/4.0/), which allows others to remix, tweak, and build upon the work non-commercially, as long as appropriate credit is given and the new creations are licensed under the identical terms.

For reprints contact: [reprint@ipinnovative.com](mailto:reprint@ipinnovative.com)

## 1. Introduction

Maxillectomy carried out in bilateral mucormycosis, spares very less hard and soft tissue in the oral cavity. Such defects are usually treated with surgical and prosthetic rehabilitation. Prosthodontic management of maxillary arch defects is fundamental to improving patients' quality of life. Total maxillectomy usually leaves no ridge tissues behind and causes increased interarch space, this in turn affects the support and stability of dentures. Increase interridge space compounds this problem. Reduction in the weight of the prosthesis found to be advantageous in lessening the leverage forces. The goal of prosthodontics is rehabilitation of missing oral and extraoral structures along with restoration of the normal functions of mastication, speech, swallowing, appearance, and so on.<sup>1</sup>

As there is minimal or no ridge tissue is left behind in total maxillectomy cases, retaining a denture intraorally is a difficult task. This is usually due to lack of hard tissue support and secondly due to the weight of the prosthesis.<sup>2</sup> A hollow maxillary denture gives the advantage of reduction of excessive weight of heat cure denture material. It also improves function. However, the undesirable weight of the prosthesis is often a dislodging force and affects its retention, stability and support.

## 2. Case Report

A 37-year-old female patient reported to the Department of Prosthodontics, Government Dental College and Research institute, with chief complain of inability to chew, difficulty in speech, due to maxillectomy consequent to COVID 19 associated mucormycosis. Medical and dental history revealed surgical resection of the anterior and left and right

\* Corresponding author.

E-mail address: [aswathiraghu@gmail.com](mailto:aswathiraghu@gmail.com) (A. Raveendran).

posterior maxillary alveolar bone due to mucormycosis infection 6 months ago.

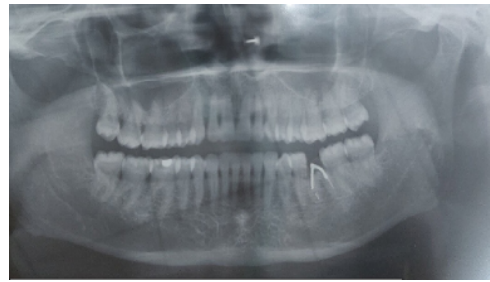
The intraoral examination revealed flat, narrow and constricted and resorbed edentulous maxillary ridge and with increased interridge distance in class-3 relationship with firm and resilient mucosa.

Primary impression of upper and lower arches were made using alginate. The custom tray was fabricated with autopolymerizing acrylic resin. Border molding was performed with greenstick and a alginate wash impression was made as the patient had intolerance to eugenol. In neutral zone recording, the softened compound and greenstick rims (admixed technique) were softened kneaded and placed in the patient's mouth, and the patient was asked to perform functional movements so that these compound rims got molded. Jaw relation was recorded as to assist in teeth arrangement. Teeth arrangement was done using semi anatomic teeth and checked with the help of plaster indice. Carving and festooning of wax was done. Try in procedure was carried out. Trial denture base was reinserted into the patient's mouth and the patient was instructed to perform various orofacial movements so as to record the polished surface of the denture in harmony with the orofacial musculature. After the try in procedure, written consent was taken.

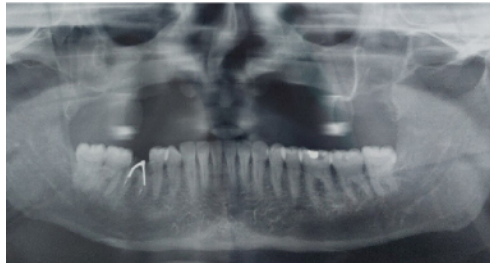
The lost salt technique was used to flask and process the maxillary trial denture. To obtain a hollow denture, half of the heat cure PMMA at the dough stage was precisely positioned over the dewaxed mould, and then salt crystals were placed over it. The remaining heat cure resin was packed and cured above that. Two holes were drilled in the thickest palatal portion of the cured denture. By flushing water through the holes with a high-pressure syringe, all of the remaining salt crystals were eliminated. The escape holes were sealed with autopolymerizing resin after all of the salt crystals had been removed. By immersing the denture in water and looking for air bubbles, the hollow cavity seal was confirmed to be satisfactory. The hollow cavity seal was checked by immersing the denture in water; if no air bubbles are seen, the seal is considered sufficient. The dentures were placed in the patient's mouth, and care, cleanliness, and maintenance instructions were given. The patient indicated that she was happy with the denture and had experienced no difficulties after a three-month follow-up.

### 3. Discussion

No ridge tissue subsequent to surgery, leads to difficulty in deciding Arch form, Position, Occlusal plane, Interridge space, and also makes it tough to judge Vertical Dimension of the patient. As there is an increase in interridge space, occlusal plane is far away from the denture base, which is also not in a desirable form creates problems in deciding position of occlusal plane and division of interridge space.



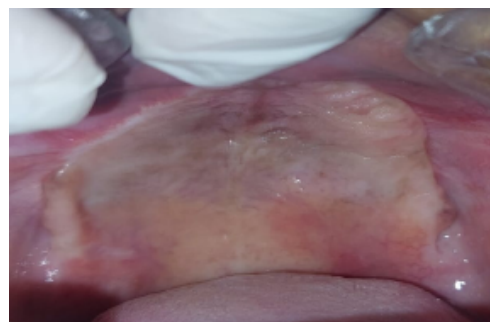
**Fig. 1:** Radiograph before total maxillectomy



**Fig. 2:** Radiograph taken after total Maxillectomy



**Fig. 3:** Patient's operative view



**Fig. 4:** Intra oral view

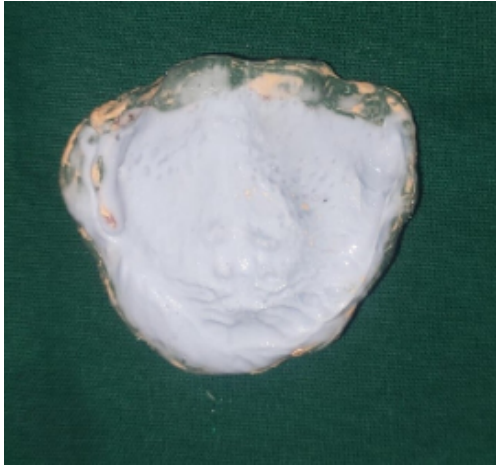


Fig. 5: Secondary impression

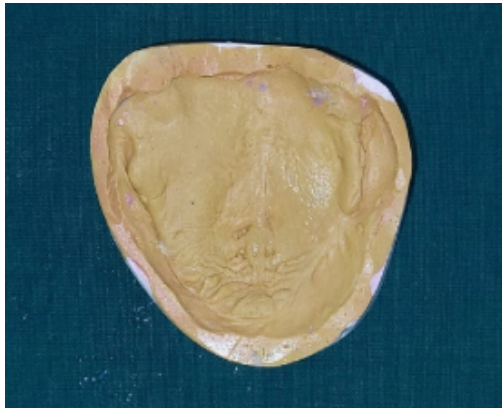


Fig. 6: Master cast

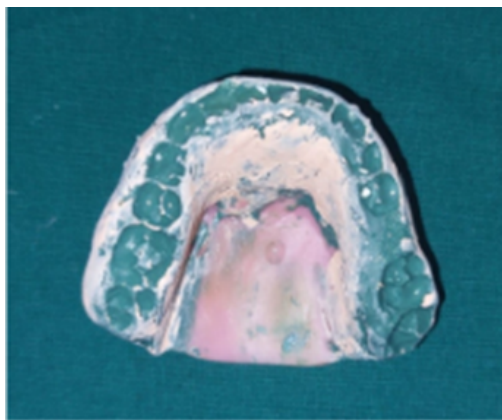


Fig. 7: Rims made with a mixed technique

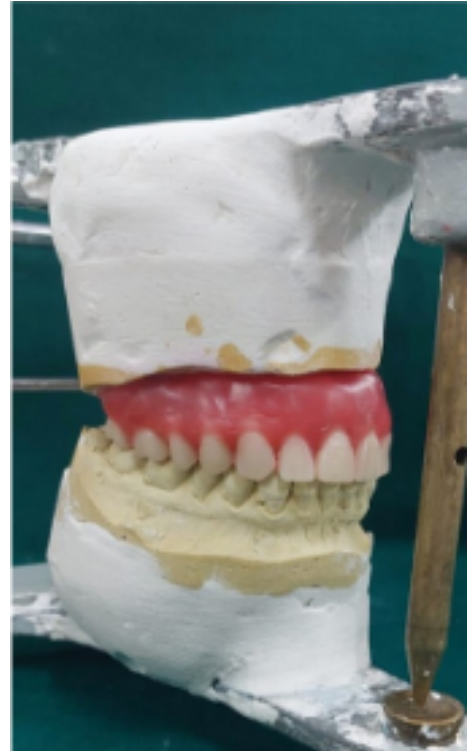

Fig. 8: Teeth arrangement

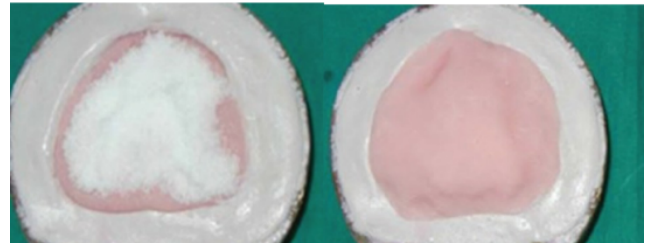

Fig. 9: Lost salt technique

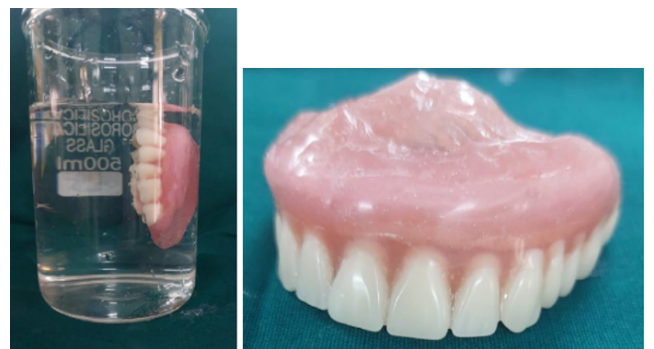
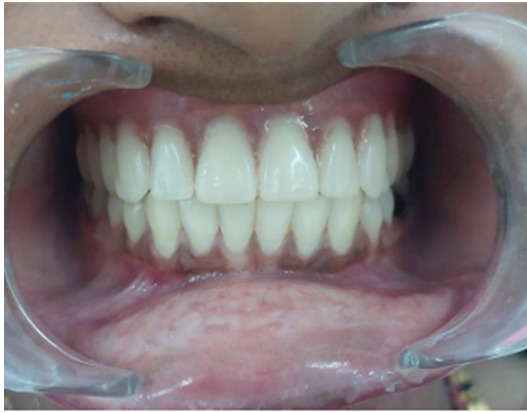
Fig. 10: Processed denture



**Fig. 11:** Trial



**Fig. 12:** Post operative

The weight of a hollow maxillary complete denture is significantly reduced, which eliminates the transfer of harmful forces that would otherwise be passed from a traditional heavy prosthesis to the underlying tissue and bone. As a result, it aids in the preservation of underlying tissue and bone. The method described has advantages as the salt crystals being melted during the curing procedure and thorough flushing after curing results in no crystals remaining in the denture, thereby maintaining the integrity of the denture, avoiding the tedious effort to remove the spacer material from the denture.<sup>1</sup> This technique of lost

salt technique is modest to perform and very economical and uses easily accessible spacer material.

#### 4. Summary

Hollow maxillary denture is the best method of rehabilitating the patient with severely resorbed ridge, increased interarch distance and long lip length.<sup>3</sup> It not only lessens the weight of the denture but also the leverage action and makes the patient feel more comfortable.<sup>4</sup> This eventually outcomes in increased retention and stability and upto some degree it is also possible to preserve the existing residual alveolar ridge. This technique is modest to perform and allows control of spacer thickness.<sup>5</sup>

#### 5. Conflict of Interest

The authors declare no relevant conflicts of interest.

#### 6. Source of Funding

None.

#### References

1. Singh M, Bhushan A, Kumar N, Chand S. Obturator prosthesis for hemimaxillectomy patients. *Natl J Maxillofac Surg.* 2013;4(1):117–20. doi:10.4103/0975-5950.117814.
2. Kumar UK, Murgod S. Hollow complete denture for resorbed ridges. *Int J Oral Health Sci.* 2018;8(2):60–2.
3. Dr PR, Patil, Dr, Aruna J, Bhandari, Dr, et al. Dhope Hollow Maxillary Denture: A case report. *Pravara Med Rev.* 2015;7(4).
4. Mani UM, Mohamed K, Kumar AK, Inbarajan A. A modified technique to fabricate a complete hollow obturator for bilateral maxillectomy in a patient with mucormycosis-A technical case report. *Special Care in Dentistry.* 2019;.
5. Kaira LS, Singh R, Jain M, Mishra R. Light weight hollow maxillary complete denture: A case series. *J Orofac Sci.* 2012;4:143–150.

#### Author biography

**Aswathi Raghuthaman**, Post Graduate Student

**Prema**, Professor and Head

**Anu Raveendran**, Senior Lecturer

**Cite this article:** Raghuthaman A, Prema, Raveendran A. Hollow denture-a solution to post covid total maxillectomy patients: A case report. *IP Ann Prosthodont Restor Dent* 2022;8(2):104-107.