

Content available at: <https://www.ipinnovative.com/open-access-journals>

IP Annals of Prosthodontics and Restorative Dentistry

Journal homepage: <https://www.aprd.in/>

## Review Article

# Reliability of aesthetic diagnostic tools in prosthodontics: A systematic review

Khamlich Kenza<sup>1,\*</sup>, Chafii Amine<sup>2</sup>, Andoh Abderahmane<sup>2</sup>

<sup>1</sup>Dept. of Dentofacial Orthopedics, Faculty of Dental Medicine, Hassan II University, Morocco

<sup>2</sup>Dept. of Prosthodontics, Faculty of Dental Medicine, Hassan II University, Morocco



### ARTICLE INFO

#### Article history:

Received 31-01-2022

Accepted 22-02-2022

Available online 21-05-2022

#### Keywords:

Computer assisted diagnoses

Dental diagnoses

Dental esthetics

Dental prosthesis

Software tools

### ABSTRACT

**Aim:** A systematic review of the literature to highlight the reliability of different tools used for the aesthetic diagnosis in fixed prosthesis.

**Materials and Methods:** Our literature research was performed using electronic databases PubMed, Cochrane library and Embase. We selected studies dating back 10 years. Eligible studies included scientific articles that met the selected inclusion criteria.

**Results:** The 28 studies selected allowed us to provide a critical analysis of the various aesthetic diagnostic tools. These studies have dismissed some tools and admitted others. The diagnosis phase requires different tools divides into documentation tools, aesthetic analysis tools, planning tools and preview tools.

**Conclusion:** Based on the analysis of the results of our studies, not all aesthetic diagnosis tools are valid. Some are rejected and others are adopted. Current tools offer a larger dimension to the creation of the new smile. Modern dentistry provides the clinician with the necessary aids to reach excellence.

This is an Open Access (OA) journal, and articles are distributed under the terms of the [Creative Commons Attribution-NonCommercial-ShareAlike 4.0 License](https://creativecommons.org/licenses/by-nc-sa/4.0/), which allows others to remix, tweak, and build upon the work non-commercially, as long as appropriate credit is given and the new creations are licensed under the identical terms.

For reprints contact: [reprint@ipinnovative.com](mailto:reprint@ipinnovative.com)

## 1. Introduction

The aesthetic diagnosis in prosthodontics is the key factor to the success of the final aesthetic project.

The success of a restorative treatment in the anterior sector is ensured when the results obtained correspond to the expectations of the patient and the practitioner. This success should be obtained by defining the aesthetic project as early as possible, and as clearly as possible, through a biomimetic and systematic approach, combining diagnosis, communication and treatment planning.

Creating a smile of harmonious proportions requires complete documentation and precise analysis. Special considerations on criteria and principles must be determined including the face, dental aspects, and the curvature of the lips, the incisal plane, and the gingival architecture.

Prosthodontists have to be able to identify the various styles of smiling and to use a set of objectively measurable parameters to undertake clinical solutions.

With the new diagnostic tools, the clinician is able to create and offer his patient an outline of the aesthetic project, allowing a prediction of the final result. In other words, this prediction ensures clear patient involvement with a less abstract definition of their requirements and expectations. However, not all of these promising aid tools are valid. They require a certain expertise in order to employ them as well as possible.

This systematic review examines current data in the literature to expose and analyze decision-making, digital and analog diagnostic tools used for any aesthetic prosthetic reconstruction. In the present study, it was attempted to evaluate the reliability of these aesthetic diagnostic tools in prosthodontics.

\* Corresponding author.

E-mail address: [kenza.khamlich94@gmail.com](mailto:kenza.khamlich94@gmail.com) (K. Kenza).

## 2. Materials and Methods

To complete the review, two authors completed two independent searches using PubMed, EMBASE and Cochrane library databases. The PubMed search was completed through the 31th of March 2020, using the following keyword combinations: “Dental diagnoses AND dental esthetics”; “Dental esthetics AND dental prosthesis”; “Dental prosthesis AND software tools”; “Dental esthetics AND software tools”; “Dental prosthesis AND computer assisted diagnoses”; “Dental esthetics AND computer assisted diagnoses”; “Dental esthetics AND dental prosthesis AND software tools”; “Dental esthetics AND dental prosthesis AND computer assisted diagnoses”.

The EMBASE and Cochrane library searches were completed at the same day using combinations of “Dental esthetics”, “Dental prosthesis” and “Software tools” search terms. Abstracts of the articles found using the prescribed protocol were reviewed. Opinions, case reports, letters to the editors, news and articles merely describing a technique or non-human studies were excluded. Only studies using esthetic diagnostic tools in prosthodontics were included and then selected for full-text review. Only articles published in English language were included. The final articles were selected with the agreement of the first two reviewers. The third reviewer was asked to review the article when there was a disagreement between the first two reviewers.

## 3. Results

A total of 4363 articles resulting from database searches were reviewed. The redundant articles were removed. The main reasons for exclusion include publications that do not study esthetic diagnostic tools in prosthodontics. Twenty-eight articles were selected for full- text review. (Figure 1)

Several tools have been studied, we have proposed to group these tools into 4 large families. The tools for complete documentation, careful aesthetic analysis, aesthetic planning tools and finally the preview tools offering a dynamic evaluation of the treatment plan. Tables 1,2,3,4 summarized and abstracted the information.

The reliability of the documentation tools was assessed in 5 studies: 4 descriptive studies, and one double-blind clinical trial. For the analytical tools, it was assessed in 8 studies: one systematic review, 2 literature reviews, 3 cross-sectional studies and 2 descriptive studies. The reliability of aesthetic planning tools has been considered in 10 studies: 2 literature reviews, 5 descriptive studies and 3 cross-sectional studies and the validity of the preview tools was assessed in 5 studies: a systematic review, a descriptive study, 2 cross-sectional studies and a comparative in vitro study.

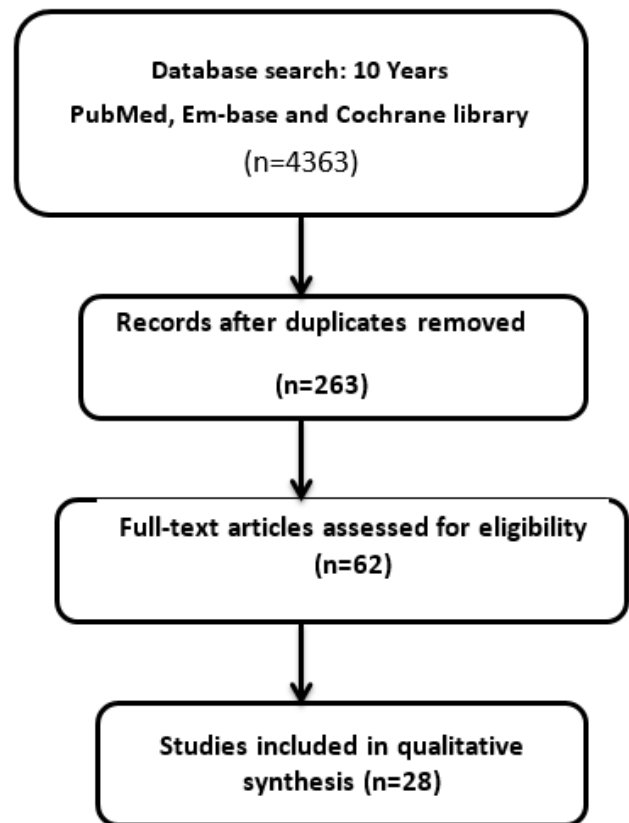


Fig. 1: FlowChart

## 4. Discussion

### 4.1. Documentation tools

It is important to note according to McLaren that documentation with an SLR camera remains the gold standard. He believes that a high-quality macro image is obtained only with a DSLR (DSLR) camera.<sup>23</sup>

The APR delivers distortion-free images calibrated with a fixed magnification ratio. He adds that the APR requires adequate configuration and a judicious choice of its components.<sup>23</sup>

Goodlin, on the other hand, confirms the importance of parameterization in successful documentation.<sup>4</sup> These authors in their studies, consider a well-parameterized APR a reliable documentation tool.<sup>4,23</sup>

These authors thus agree on the following criteria: • Components of the APR: - SLR type camera - A lens with a focal length of 80 to 105 mm - A mid-range Canon or Nikon camera - A macro lens - Side flashes with support for the anterior sector or Ring flash for the posterior sector - Compatible components (same brand preferred) • Parameterization of the APR: - ISO between 100 to 200 - An aperture of: 2.8 - Shutter speed of 1 / 125s - A magnification ratio of 1:10 for a front photo; of 1: 2 for the smile and occlusal photos; 1: 1 for close-ups. – Manual mode - No

**Table 1:** Documentation tools description

Documentation tools				
Study /Reference	Type of study	Sample size	Tools	Conclusion
Christian Coachman and al, 2017 <sup>1</sup>	Descriptive study	—————	1- Smartphone 2- DSD software	- Dynamic documentation provides better analysis - Sufficient smartphone
Sajjadi and al, 2016 <sup>2</sup>	Double blind clinical trial	40 female participants whose smile was evaluated by 12 practitioners: 6 orthodontists, 3 prosthodontists and 3 specialists in conservative dentistry	1- 3 SLR cameras: EOS 5D Mark II, EOS 550D, Powershot G12 (Canon) 2- 3 different sensors: Full Frame 21.1 Megapixel Half Frame 18.0 Megapixel Compact 10.4 Megapixel Distributed respectively at the level of the 3 devices mentioned above	-The quality of the image results directly from the technology of the sensor used - The Full Frame sensor is more efficient than the Half frame or compact sensors - The aesthetic evaluation of a smile is affected by the quality of the image - The clinicians of the 3 specialties studied have the same standards in the aesthetic evaluation of a smile
Edward A. McLaren and al, 2013 <sup>3</sup>	Descriptive study	—————	1-SLR camera 2- lenses 3-Flash 4- Photos and videos for the Smile Design	- SLR cameras are the most suitable - Canon and Nikon midrange with macro lenses are recommended - Lenses with a focal length of 100 mm are suitable - Side flashes with support are the most suitable for the anterior sector - Ring flash for the posterior sector - Standardize the documentation protocol - Combine dynamic and static documentation
Goodlin and al, 2011 <sup>4</sup>	Descriptive study	—————	1- SLR camera 2- Lentils 3- Flash 4-Parameteri-zation of the box	The reliable parameters for correct documentation: - ISO between 100 to 200 - Aperture at f: 2.8 - Shutter speed at 1/125 s - Side flashes set to maximum for the Ant sector - Ring flash for the posterior sector - No autofocus - Nikon or canon case - Focal distance between 90 and 105 mm - Magnification ratios depending on the type of photos: + Front = 1: 10 + Smile, occlusal or with retractors = 1: 2 + Close-ups = 1:1
Louis Hardan and al, 2020 <sup>5</sup>	Descriptive study	—————	1-Smartphone 2- Smile Lite MDP (Mobile Dental Photography)	The smartphone is reliable for documentation - Adjusting the light on the Smile Lite is essential - The combination is necessary

autofocus

Sajjadi and al add that the quality of the image also depends on the type of sensor used. He recommends a Full Frame sensor rather than a Half Frame or Compact. He proves, through his double-blind study, that the quality of the image directly influences the perception of a smile. This assessment was carried out by 3 prosthodontists, 6 orthodontists and 3 specialists in restorative dentistry.<sup>2</sup> McLaren, Goodlin and Sajjadi confirm that the APR offers very high image quality and thus good documentation.<sup>2,4,23</sup>

Coachman and al believe, on the other hand, that a smartphone is sufficient for documentation. They advocate dynamic documentation. This is based on videos. They believe that dynamic documentation increases the

chances of capturing the patient's uninhibited smile unlike simple static photos. According to these authors, a one-second video covers 29 shots of photos.<sup>1</sup> This dynamic documentation follows a standardized protocol: With 4 initial videos: a face-to-face video with and without retractors, a profile video at rest and with a smile, a video "at noon" above the head to visualize the incisal line of the 6 teeth, and a video in occlusal view. These videos are completed by 4 others: a recorded interview, a close-up phonetic video where the patient counts from 0 to 10, a video with retractors recording the laterality movements on the working side and not, and a video of the 2 arches.<sup>1</sup>

Louis hardan, in the same view, considers that the smartphone is suitable for professional documentation.

**Table 2:** Aesthetic analysis tools description

Aesthetic analysis tools Study /Reference	Type of study	Sample size	Tools	Conclusion
Srivastava and al, 2020 <sup>6</sup>	Systematic review	14 selected articles	1- CEI 2- PES/WES 3- ICAI 4- PI 5- IAS	The PES / WES index is the most reliable Consensus is needed to determine reliable indices.
LB Azevedo and al, 2018 <sup>7</sup>	Cross-sectional study	74 students with aesthetic natural smiles	1- PES/WES	PES / WES is valid Its maximum score is not observed in natural dentition WES is more prevalent than PES with natural teeth
Calamia and al, 2015 <sup>8</sup>	Narrative review	—————	Aesthetic checklist or Smile Evaluation Form	The aesthetic evaluation sheet is a reliable tool It ensures a complete and efficient analysis
Hof and al, 2018 <sup>9</sup>	Cross-sectional study	189 patients with 189 supra-implant crowns at ANT level + 2 Evaluations made by 5 examiners 4 weeks apart	8 clues: 1- Papilla index (PI) 2- Pink Esthetic Score (PES) 3- Crown Aesthetic Implant Index (ICAI) 4- Pink and White Esthetic Score (PES / WES) 5- Complex Esthetic Index (CEI) 6- Implant Aesthetic Score (IAS) 7- Subjective Esthetic Score (SES) 8- Rompen Index	There is no correlation between the different results obtained between the 5 examiners. There is no reproducibility between the results compared to 4 weeks. The authors note an effect of specialization of the evaluators
Sampaio and al, 2018 <sup>10</sup>	Descriptive study	5 different shade guides = including 11 selected shades	1- Vita classical shade guide 2- IPS e.max Ceram shade guide (Ivoclar Vivadent) 3- IPS d.SIGN shade guide (Ivoclar Vivadent) 4- Initial ZI shade guide (GC) 5- Creation CC shade guide (Creation Willi Geller)	No shade guide has been able to provide a perfect match in terms of hue, saturation and lightness.
Igiel and al, 2017 <sup>11</sup>	Cross-sectional study	40 observers 10 dentists (5F; 5H) 10 prosthetists (3F; 7H) 10 students (5F; 5H) 10 assistants (10 F)	1- VITA Classical shade guide 2- VITA 3D Master shade guide 3- VITA EasyShade spectrophotometer	The spectrophotometer allows better reproducibility and reliability.
Hein and al, 2017 <sup>12</sup>	Narrative review	336 participants including clinicians and laboratory technicians who attended 30 training courses in dental photography over a period of 3 years	1- A reflex camera 2-macro lens 3- macro flash 4-Polarizing filter	The eLABor_aid protocol is a process for objectively reading the shade without resorting to a spectrophotometer.
McLaren and al, 2017 <sup>13</sup>	Descriptive study	—————	1- Reflex camera (APR) 2- Flash 3- macro lens 4- Photoshop software 5-Adobe Camera Raw software 6-WhiBal Gray Card = Gray chart 7-Smile line glaze = lubricating gel	Reliable shade measurement technique from clinical photos calibrated using a gray chart.

**Table 3:** Aesthetic planning toolsdescription

Aesthetic planning tools Study /Reference	Type of study	Sample size	Tools	Conclusion
Vishnu Raj and al, 2013 <sup>14</sup>	Narrative review	—————	1- The Golden Proportion (GP) 2- The RED Proportion 3- W: H Ratio = Ratio width: height 4- The vertical position of the lateral incisor 5- The apparent contact surface "ACD"	The GP and the RED proportion are invalid The W: H ratio, the vertical position of the lateral incisor and the ACD are references for planning
Christian Coachman and al, 2017 <sup>15</sup>	Descriptive study	—————	1- DSD® 2- Smartphone	DSD® is a reliable and essential software for planning
Zebac Jafri and al, 2020 <sup>16</sup>	Descriptive study	—————	1-DSD® 2-Smartphone 3- Retractor	DSD® is simple and efficient software
Patrik K Sharma and al, 2012 <sup>17</sup>	Narrative review	—————	1- The dental form 2- size and proportion 3- Axial inclinations 4- The shade progression at the sector level 5- Contact areas 6- Incisal embrasures 7-Characteri-zation of teeth	These aesthetic guidelines are essential for planning
Nold S and al, 2014 <sup>18</sup>	Cross-sectional study	106 Caucasian adult (54 women and 52 men) with an average age of 24.5 years	1- The correlation of the median lines 2- The position and curvature of the upper lip 3- The relation between the maxillary anterior sector and the lower lip 4- The width of the smile	These aesthetic guidelines are reliable
Maharjan and al, 2018 <sup>19</sup>	Cross-sectional study	63 participants (18-35 years old)	1- the Golden proportions 2- the RED proportions Reccurent Esthetic Dental 3- the Golden percentage	These tools are invalid
Crescenzo and al, 2015 <sup>20</sup>	Descriptive study	—————	1- VEP® 2- Presentation software: Keynote and PowerPoint	DSD-inspired design Demanding Photo Protocol with a professional camera
Jang Chou and al, 2016 <sup>21</sup>	Cross-sectional study	1 male participant + 50 evaluators belonging to 4 different age groups: 15-24 / 25-39 / 40-54 / 55 +	1- Smile Index (SI) 2- Incisal Edge Position (IEP) 3-D7000 NIKON reflex camera 4- Macro lens 5- Sigma ring flash 6- Photoshop CS5 software	Le SI et le IEP sont des outils fiables et reproductibles
Valerio Bini and al, 2014 <sup>22</sup>	Descriptive study	—————	1- ADSD® 2- Photoshop software	Conception basée sur la distorsion de sourire numérique fournis par la bibliothèque du logiciel. Système FATS pour l'étalonnage (Face Analogic Transfer Support)
Edward McLaren and al, 2013 <sup>23</sup>	Descriptive study	—————	1- Photoshop Smile Design Technique® 2- Photoshop software	Design based on a "dental template" adaptable to the patient's smile. Creation of the template from the image of an attractive smile

**Table 4:** Preview tools description

Preview tools Study /Reference	Type of study	Sample size	Tools	Conclusion
Cattoni and al, 2019 <sup>24</sup>	Comparative analysis In vitro	1 participant = 52 resin models	1- PhOTOS 2- Impregnated impressions 3-DSD software: DDS-2D + DSS-3D 4- wax up 5- mock-up 6- CAD / CAM software	The milled mockup is more precise and reproducible than the molded mockup
Tim Joda and al, 2015 <sup>25</sup>	Systematic review	18 articles treated with a total number of 112 patients	3D Virtual Dental Patient software	The fusion of 3D images of the facial skeleton, extraoral soft tissues and dentolabial data leads to a Virtual Patient in static condition. This software allows preview of the case
Hongqiang Ye and al, 2020 <sup>26</sup>	Descriptive study	—————	1- AP Reflex (Canon EOS 70D) 2- Intra-oral scanner: TRIOS; 3 shape 3- Extra-oral scanner: FaceSCAN3D; 3D shape GmbH 4- Software: Geomagic studio 2012; 3D systems = for processing 3D images Dental system; 3Shape = for the design of new restorations iMovie; Apple Corp = for editing videos	New 4D technique allowing visualization of aesthetic results in virtual reality using intraoral and facial scanners and software.
Abduo and al, 2016 <sup>27</sup>	Cross-sectional study	13 participants nécessitant une réhabilitation antérieure esthétique	1- digital wax up 2- analog wax up	Both types of wax up can ensure the same aesthetic result is obtained. The digital wax up is more reliable. The analog wax up ensures a character custom surface risation.
Sancho-Puchades and al, 2015 <sup>28</sup>	Cross-sectional study	3 participants requiring anterior aesthetic rehabilitation	1- Wax up 2- Mock up 3- 3D printers 4- CAD / CAM system	Analogue wax ups and mock ups are unreliable A printed or milled mock up is no longer valid for preview

He adds that the adjustment of the brightness with the device Smile Lite MDP is the same condition for the success of the documentation. Thus Harden considers a smartphone equipped with the Smile Lite a reliable tool for documentation.<sup>5</sup>

#### 4.2. Aesthetic analysis tools

Calamia and Wolff state that the Aesthetic Assessment Sheet or Aesthetic Checklist is a reliable analytical tool.<sup>8</sup> This evaluation sheet according to the authors allows a complete and efficient aesthetic analysis.

In addition to the clinical elements to be noted, some authors use aesthetic evaluation indices. These indices are generally used to assess the success of prosthetic implant

treatment or not in the anterior sector.<sup>6,7,9</sup>

Several clues are found in the literature. The most commonly adopted are: - Papilla Index: PI or Papilla Index Score: PIS - Pink Esthetic Score: PES - Implant Crown Aesthetic Index: ICAI - Pink and White Esthetic Score: PES / WES - Complex Esthetic Index: CEI - Subjective Esthetic Score: SES - Implant Aesthetic Score: IAS - Rompen Index: RI

Srivastava and al, propose a systematic review in 2020, where the PES / WES indices are considered to be the most reliable. The authors stress the need for consensus to select the most reliable indices.<sup>6</sup> Azevedo and al consider the PES / WES index to be the most reliable. Although its maximum score was not found in natural dentition.<sup>7</sup>

Hof and al in their study assess the reliability of the 8 indices most used in the literature. The study included 189 patients with 2 assessments made by 5 examiners 4 weeks apart. They declare the absence of any intra or inter-examiner reproducibility. They also raise a specialization effect. The results are thus different according to the specialty of each observer. Orthodontists are recognized as the most demanding. Prosthodontists are more critical of the WES. Periodontists give lower results for PES.<sup>9</sup>

We have also included the shade statement as part of the aesthetic analysis. Several shade measurement tools have been discussed in the literature. Sampaio and al declare the shade guides, generally used as a reference tool, invalid. None of the 5 shade guides studied could offer a perfect match in terms of saturation, hue and brightness.<sup>10</sup>

Igiel and al find the spectrophotometer more reliable. It offers guaranteed reproducibility.<sup>11</sup> Hein and al describe a new protocol: the "eLABor\_aid". It is a digital process for objectively detecting hue, using a digital camera set to several parameters.<sup>12</sup> McLaren and al, also provide an accurate digital technique from calibrated clinical photos. These authors offer precise settings for the camera. They recommend the use of polarizing filters and a "WhiBal Card", a gray chart essential for calibrating the screen of the clinician and laboratory technician.<sup>13</sup>

### 4.3. Aesthetic planning tools

We proposed to divide the aesthetic planning tools into aesthetic design criteria, theoretical aesthetic indices and digital design tools.

#### 4.3.1. Aesthetic design criteria

Sharma and al, consider the aesthetic criteria essential and sufficient for planning.<sup>17</sup> The guidelines for a "Smile Makeover" are: the choice of tooth shape, size, proportions, axial inclinations, progression of shade in the anterior sector, visible contact surfaces, vertical position of the incisor (IEP) and the shape of the embrasures. Nold and al deal with complementary aesthetic parameters.<sup>18</sup> The coincidence of the midlines: facial and dental. - The parallelism without contact between the incisal line and the curvature of the lower lip. The "SI", according to Chou and al, is a good planning tool. It determines the width of the smile. The "SI" corresponds to the ratio between the inter-commissural width and the interlabial gap, with a smile. An SI of 7.2 offers harmonious dimensions to the smile.<sup>21</sup> All of the 3 aforementioned authors agree on the reliability of the aesthetic guidelines.<sup>17,18,21</sup>

#### 4.3.2. Theoretical aesthetic indices:

Raj and al, analyze the Golden Proportion (GP).<sup>16</sup>

It is a concept where the size of each tooth is 60% the size of the tooth that precedes it, from a frontal view. They deem the GP invalid for planning. Maharjan and al, confirm

the weakness of this index.<sup>19</sup>

Raj and al, examine the RED proportion. This is a concept where the mesiodistal widths of the anterior segment decrease by the same amount going distally from a front view. The authors consider this tool unreliable.<sup>16</sup> Maharjan and al, confirm this finding.<sup>19</sup>

The Golden Percentage (GPr) is an index little treated in the literature. Maharjan et al, consider this theory invalid for planning.<sup>19</sup>

The width / height ratio W: H is an index frequently cited in the literature. All the authors agree on the following proportions: The central incisor: average height: 9.5mm and 10.2mm; average width 8.1 to 8.6 mm. The lateral incisor: average height: 7.8 to 8.7 mm; average width 6.1 and 6.6 mm. The canine: average height: 8.9 and 10.1 mm; average width 7.1 and 7.6 mm. The central incisor should always be 1 to 1.5 mm wider than the canine.

The summary of the data found indicates that the reliable planning tools are: - Planning software, optional - Aesthetic guidelines, essential - The width / height ratio, as a reference.

#### 4.3.3. Digital design tools

Design software makes it possible to systematize a diagnostic approach. Coachman and Calamita provided, from their point of view, that the DSD<sup>®</sup> is the indispensable tool for planning. It offers predictable aesthetic results. It authorizes the creation of a frame of proportions created by literature to guide the outline of the new smile.<sup>1</sup>

Bini points out that it is not necessary to draw a new smile. According to him, it is preferable to import an existing smile from the database provided by the ADSD<sup>®</sup> software that he offers.<sup>22</sup> Bini states that ADSD<sup>®</sup> is a unique design tool. The technique consists in copying and superimposing on the initial smile, an image of a smile taken from the database of the software. The adaptation of the smile chosen in the database to the patient is done by distortion.<sup>22</sup>

McLaren and al, on the other hand, offer Photoshop Smile Design Technique<sup>®</sup>. They recommend not to draw a new smile but to adapt an existing smile to the patient.<sup>23</sup> A photography of an attractive smile that meets the aesthetic criteria of the patient have to be determined during the first interview in the practice. This photography will allow the designer to take a "dental template". The latter corresponds to the outline of the selected smile. The chosen "dental template" is adapted to the proportions of the patient thanks to the "free transformation" function of the Photoshop software.<sup>23</sup>

Crescenzo and al propose the Virtual Esthetic Project (VEP). The VEP<sup>®</sup> is inspired by the DSD<sup>®</sup>, it is distinguished by a demanding documentation for the professional device.<sup>20</sup> The VEP<sup>®</sup> is based on the layout of reference lines and curves. The designer then traces

the “aesthetic mask”, in other words the contours of the new smile. This line is made using the Keynote “Drawing” tool.<sup>20</sup>

#### 4.4. Preview tools

Cattoni and al, evaluate in their study the precision of the analog and digital mock-ups.<sup>24</sup> The analog mock-up is obtained from a silicone key molded on a wax-up made in the laboratory. The digital mock-up is obtained by CAD / CAM technique or 3D printing after validation of a digital wax-up obtained by design software. The authors conclude that the milled mock-up is more precise and reliable than the highly operator-dependent molded mock-up. They consider the analog mock-up invalid. The areas of accumulation of errors during the realization of this one are: the cervical and incisal region. They add that digital technology saves time and costs less.<sup>24</sup>

Abduo and al, assess the reliability of digital and analog wax-ups. They conclude that the 2 types of wax up ensure a successful aesthetic result.<sup>27</sup> However, the digital wax up is more faithful to the original design and therefore more reliable. The authors believe that the analog wax up, on the other hand, remains more artistic with a more delicate surface characterization.<sup>27</sup>

Sancho-puchades, states that the patient’s expectations can sometimes be difficult to interpret and an analog technique with wax-ups and mock-ups was sometimes insufficient to identify his needs.<sup>28</sup> The possible discrepancy between the proposed digital planning and the mock-up carried out can lead to the abandonment of the project. The author concludes that the milled or 3D printed digital mock-up is more reliable in design than the analog mock-up.<sup>28</sup>

Tim Joda and al state in their systematic review that creating a virtual patient facilitates the preview phase. This is done by combining 3D images of the facial skeleton, extraoral soft tissue, and an intraoral scan.<sup>25</sup> This image overlay technique allows the creation of a static virtual patient. The authors consider this process complex. It requires strong irradiation and a mastery of 3D software to use it at best. Which constitutes a weakness.<sup>25</sup> They aspire to the evolution of a dynamic 4D preview technique in virtual reality. This is what Ye and al, in 2020, propose in their study. The first 4D “Prediction” software.<sup>26</sup> This technique simulates different facial expressions and postures. It allows the clinician to assess the integration of the project with the patient’s facial aesthetics.<sup>26</sup> This new process requires more clinical hindsight to judge its reliability.

## 5. Conclusion

Aesthetic diagnosis is essential for the success of a prosthetic project in the anterior sector. Finding reliable tools suitable for the diagnostic phase is an essential step.

The results obtained during this systematic review of the literature underline the importance of the reliability of these aesthetic diagnostic tools. Indeed, not all diagnostic tools are valid. Their reliability depends on the critical analysis that has been carried out from the scientific articles selected. Some tools have been questioned, others have been approved. The proposed diagnostic phase includes 4 main steps: the documentation phase, the aesthetic analysis phase, the aesthetic planning phase and the preview phase. This is the ideal process to follow for a successful aesthetic project. It is essential to involve the patient and support him during aesthetic choices. The patient must be the co-author of the final project, he is therefore the first actor in his treatment.

## 6. Conflict of Interest

The authors declared no financial conflict of interest.

## 7. Source of Funding

None.

## References

1. Coachman C, Calamita MA, Sesma N. Dynamic documentation of the smile and the 2D/3D digital smile design process. *Int J Period Rest Dent.* 2017;37(2):183–93.
2. Sajjadi SH, Khosravanifard B, Moazzami F, Rakhshan V, Esmailpour M. Effects of three types of digital camera sensors on dental specialists’ perception of smile esthetics : A preliminary double-blind clinical trial. *J Prosthodont.* 2016;25(8):675–81.
3. McLaren EA, Garber DA, Figueira J. The photoshop smile design technique (part 1) : digital dental photography. *Compend Contin Educ Dent.* 2013;34(10):772–6.
4. Goodlin R. Photographic-assisted diagnosis and treatment planning. *Dent Clin North Am.* 2011;55(2):211–27.
5. Hardan LS, Moussa C. Mobile dental photography: a simple technique for documentation and communication. *Quintessence Int.* 2020;51(6):510–8. doi:10.3290/j.qi.a44365.
6. Srivastava G, Panda S, Padhiary SK, Das SS, Fabbro MD. Reproducibility and validity of anterior implant esthetic indices : A review. *J Indian Soc Periodontol.* 2020;24(4):301–8. doi:10.4103/jisp.jisp\_528\_19.
7. Azevedo VLB, de Andrade O, Silva FP. Digitalized assessment of PES/WES in young adults. *J Res Dev.* 2018;6(1):1–4. doi:10.4172/2311-3278.1000163.
8. Calamia JR, Wolff MS. The components of smile design: new york university smile evaluation form revisited, update 2015. *Dent Clin North Am.* 2015;59(3):529–46.
9. Hof M, Umar N, Budas N, Seemann R, Pommer B, Zechner W, et al. Evaluation of implant esthetics using eight objective indices-comparative analysis of reliability and validity. *Clin Oral Implants Res.* 2018;29(7):697–706.
10. Sampaio CS, Gurrea J, Gurrea M, Bruguera A, Atria PJ, Janal M, et al. Dental shade guide variability for hues B,C and D using cross polarized photography. *Int J Period Rest Dent.* 2018;38:113–8. doi:10.11607/prd.3270.
11. Igiel C, Lehmann KM, Ghinea R, Weyhrauch M, Hangx Y, Scheller H, et al. Reliability of visual and instrumental color matching. *J Esthet Rest Dent.* 2017;29(5):303–8.
12. Hein S, Tapia J, Bazoz P. eLABor\_aid: a new approach to digital shade management. *Int J Esthet Dent.* 2017;12(2):186–202.
13. McLaren EA, Figueira J, Goldstein RE. A technique using calibrated photography and photoshop for accurate shade analysis and



- communication. *Compend Contin Educ Dent*. 2017;38(2):106–13.
14. Raj V. Esthetic paradigms in the interdisciplinary management of maxillary anterior dentition-a review. *J Esthet Rest Dent*. 2013;25(5):295–304.
  15. Coachman C, Calamita MA, Sesma N. Dynamic documentation of the smile and the 2D/3D digital smile design process. *Int J Period Rest Dent*. 2017;37(2):183–93.
  16. Jafri Z, Ahmad N, Sawai M, Nishat S, Bhardwaj A. Digital Smile Design- An innovative tool in aesthetic dentistry. *J Oral Biol Craniofac Res*. 2020;10(2):194–8.
  17. Sharma PK, Sharma P. Dental smile esthetics : the assessment and creation of the ideal smile. *Semin Orthod*. 2012;18(3):193–201. doi:10.1053/j.sodo.2012.04.004.
  18. Nold SL, Horvath SD, Stampf S, Blatz MB. Analysis of select facial and dental esthetic parameters. *Int J Period Rest Dent*. 2014;34(5):623–9. doi:10.11607/prd.1969.
  19. Maharjan A, Joshi S. Clinical evaluation of maxillary anterior teeth in relation to golden proportion, red proportion and golden percentage. *J Nepal Health Res Counc*. 2018;16(1):11–5.
  20. Crescenzo H, Crescenzo D. Le projet esthétique virtuel Un nouvel outil pour les traitements esthétiques. *Strat Proth*. 2015;15:143–52.
  21. Chou JC, Nelson A, Diksha K, Elathamna EN, Durski MT. Effect of smile index and incisal edge position on perception of attractiveness in different age groups. *J Oral Rehab*. 2016;43(11):855–62.
  22. Bini V. Aesthetic Digital Smile Design ADSD: dentisterie esthétique assistée par ordinateur - Partiel. *Dent Tribune*. 2014;(3):12–20.
  23. McLaren EA, Garber DA, Figueira J. The photoshop smile design technique (part 1) : digital dental photography. *Compend Contin Educ Dent*. 2013;34(10):774–774.
  24. Cattoni F, Teté G, Calloni AM, Manazza F, Gastaldi G, Capparè P, et al. Milled versus moulded mock-ups based on the superimposition of 3D meshes from digital oral impressions: a comparative in vitro study in the aesthetic area. *BMC Oral Health*. 2019;29(1):230. doi:10.1186/s12903-019-0922-2.
  25. Joda T, Brägger U, Galluci G. Systematic literature review of digital three-dimensional superimposition techniques to create virtual dental patients. *Int J Oral Maxillofac Implants*. 2015;30(2):330–7. doi:10.11607/jomi.3852.
  26. Ye H, Wang KP, Liu Y, Liu Y, Yongsheng Z. Four-dimensional digital prediction of the esthetic outcome and digital implementation for rehabilitation in the esthetic zone. *J Prosthet Dent*. 2020;123(4):557–63.
  27. Abduo J, Bennamoun M, Tennant M, Mcgeachie J. Impact of digital prosthodontic planning on dental esthetics: biometric analysis of esthetic parameters. *J Prosthet Dent*. 2016;115(1):57–64.
  28. Sancho-Puchades M, Fehmer V, Hämmerle C, Sailer I. Advanced smile diagnostics using CAD/CAM mock-ups. *Int J Esthet Dent*. 2015;10(3):374–91.

### Author biography

**Khamlich Kenza**, Resident  <https://orcid.org/0000-0002-3332-1236>

**Chafii Amine**, Professor

**Andoh Abderahmane**, Professor

**Cite this article:** Kenza K, Amine C, Abderahmane A. Reliability of aesthetic diagnostic tools in prosthodontics: A systematic review. *IP Ann Prosthodont Restor Dent* 2022;8(2):80-88.