

Content available at: <https://www.ipinnovative.com/open-access-journals>

IP Annals of Prosthodontics and Restorative Dentistry

Journal homepage: <https://www.aprd.in/>

## Case Series

# Digitising prosthetics: Clinical series

Shikha Singh<sup>1,\*</sup>, Aakash Sethi<sup>1</sup>, Amit Khattak<sup>1</sup>, Dinesh Kumar<sup>1</sup>, V S Legha<sup>1</sup>,  
Deepak Kalia<sup>1</sup>, Kamal Verma<sup>1</sup>

<sup>1</sup>Dept. of Prosthodontics, Army Dental Centre Research & Referral, New Delhi, India



### ARTICLE INFO

#### Article history:

Received 21-01-2022

Accepted 28-01-2022

Available online 16-03-2022

#### Keywords:

Finger prosthesis

Acrylic prosthesis

Rapid prototyping

Computer Aided Design

### ABSTRACT

Loss of any part of the body is seen mostly due to trauma, diseases or congenital malformations which causes psychological trauma along with functional, and esthetic impairment. Amputated finger can be surgically reconstructed but when not feasible the patient reports to a prosthetist for replacement of the lost part. The patient's expectations must be met by the prosthetist by mimicking the opposite digit as closely as possible which helps regains the patient's lost confidence. This article proposes a technique for rehabilitation of an amputated finger using Rapid prototyping technique as compared to the conventional technique which is time consuming, requires manual skills, lacks precision and finesse making digitally fabricated prosthetic digit a reality.

This is an Open Access (OA) journal, and articles are distributed under the terms of the [Creative Commons Attribution-NonCommercial-ShareAlike 4.0 License](#), which allows others to remix, tweak, and build upon the work non-commercially, as long as appropriate credit is given and the new creations are licensed under the identical terms.

For reprints contact: [reprint@ipinnovative.com](mailto:reprint@ipinnovative.com)

## 1. Introduction

All organs of our body have an important role to play and finger too is an essential part playing a supreme role in performing routine functions and esthetics. Finger amputation not only causes devastating physical, psychosocial trauma but also can cause professional and economic damage to an individual.<sup>1,2</sup> Various advanced micro vascular replantation surgeries save severally injured and traumatically amputated finger but it is not a viable option in all the clinical scenarios and then may be contraindicated or unsuccessful. As characters of fingers are different for every individual so such patients can be rehabilitated by customized highly esthetic, functional passive finger prosthesis. Customized manually fabricated finger prosthesis is laborious, time consuming and requires skill, so computer aided techniques of rapid prototyping can be used to fabricate finger prosthesis with precision, saving both time and labor.<sup>3-6</sup>

This article presents prosthetic rehabilitation of distal phalange of amputated right index finger using computer aided 3-D printing technique Vs conventional rehabilitation technique rehabilitating left index and middle finger.

## 2. Case Report 1

A 21 yr old male patient was referred to department of Prosthodontics for the rehabilitation of partially amputated left index and middle fingers. He had history of trauma at his workplace about one year back. Physical examination of hand revealed that the left index and middle fingers are amputated at distal interphalangeal joint with no sign of any pathology (Figure 1). Due to financial limitations patient had to be treated using conventional method of finger prosthesis fabrication.

### 2.1. Treatment

The patient was asked to thoroughly wash his hands following which hands were lubricated with thin layer of

\* Corresponding author.

E-mail address: [shiksweet@gmail.com](mailto:shiksweet@gmail.com) (S. Singh).

petroleum jelly to facilitate easy removal of impression material. An impression of amputated left and donor right hand was made using irreversible hydrocolloid impression material (Figure 2). The impression was poured using type III dental stone (Kal Rock, Kala Bhai; Figure 3). Using the model of right hand the putty index of index and middle finger were made for fabrication of wax pattern (Figure 4). The retrieved wax pattern was then modified and characterized to mimic soft tissue contours following which try in was done (Figure 5). The wax pattern was then flaked using die stone in the conventional manner to obtain the two-piece mold. Dewaxing was carried out and then medical grade Factor II RTV silicone was manipulated and packed in layers into the mold and left for curing. After retrieval, the prosthesis was characterized using extrinsic stains to match the color of the skin followed by application of extrinsic sealant (Figure 6). An artificial nail was incorporated into nail bed using an adhesive. The final prosthesis was placed in situ using medical grade adhesive and was evaluated for overall fit and esthetics (Figure 7).

### 3. Case Report 2

A 26 yr old male patient was referred to department of Prosthodontics for the rehabilitation of partially amputated right index finger. He had history of trauma to his right hand at work about 2 years back. Physical examination of hand revealed that the right index finger was amputated at distal interphalangeal joint with no sign of any pathology (Figure 8). Since the patient was esthetically conscious and had high expectations from the end result so a decision of fabrication of customized silicone finger prosthesis using Computer Aided Design and 3D printing technique was made.

#### 3.1. Fabrication of 3D printed acrylic model of the stump & template

An extraoral MRI scan of the right & donor left hand was done to obtain image data of the deficient as well as contralateral fingers. The obtained STL images were used to 3D print the acrylic model of the stump using medical grade software. The computer aided designing of the prosthesis was done by using the STL image of the index finger of left hand which was then mirror imaged to mimic the anatomy of the right index finger, which was followed by digital try in (Figure 9). The designed template was then 3-D printed with polylactate using Fused deposition modeling (FDM) technique (Figure 10).

#### 3.2. Manufacturing the mold and fabrication of the prosthesis

The acrylic template was used to obtain the wax pattern for prosthesis fabrication. The wax pattern along with stump model was then flaked using die stone in the conventional


manner to obtain the two-piece mold (Figure 11). After setting of the die stone dewaxing was performed in conventional manner. Medical grade Factor II RTV silicone was then manipulated and after shade matching the silicone was packed in layers into the mold and left for curing at room temperature. Post curing the flash was removed from the retrieved prosthesis using acrylic trimming burs and try in was done to check for the fit and accuracy of the prosthesis. Then the prosthesis was characterized using extrinsic stains to match the color of the skin followed by application of extrinsic sealant. An artificial nail was fabricated using auto-polymerizing heat cure acrylic resin and was properly shaped and trimmed to appropriate size and incorporated into nail bed using an adhesive. The final prosthesis was placed in situ and was evaluated for the overall fit and esthetics (Figure 12). The patient was very satisfied with the outcome of the result and the minimal appointments involved. Instructions were given to the patient for the usage and maintenance of the prosthesis.

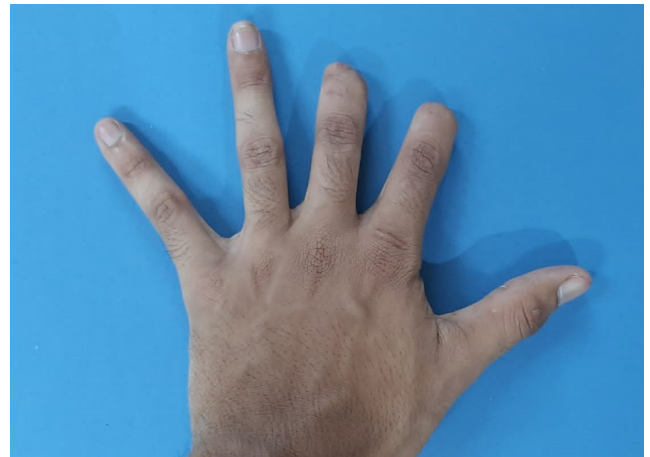

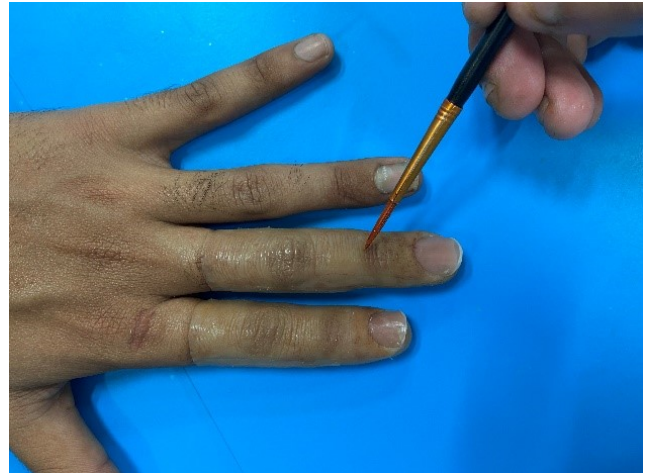Fig. 1: Pre-treatment photograph



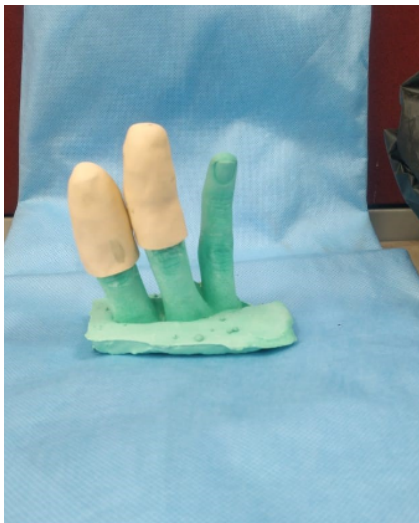Fig. 2: Impression of amputated left and donor right hand



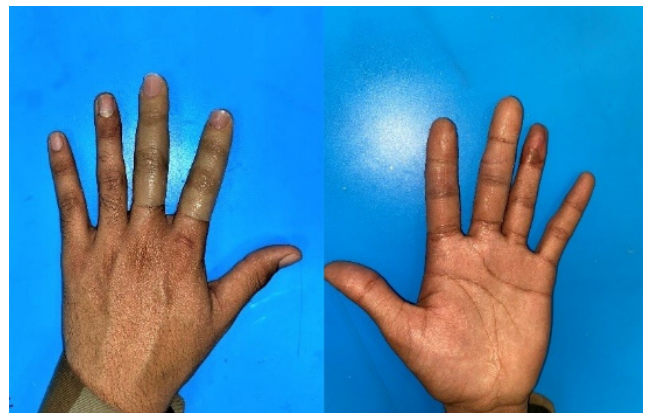**Fig. 3:** Stone models of amputated left and donor right hand



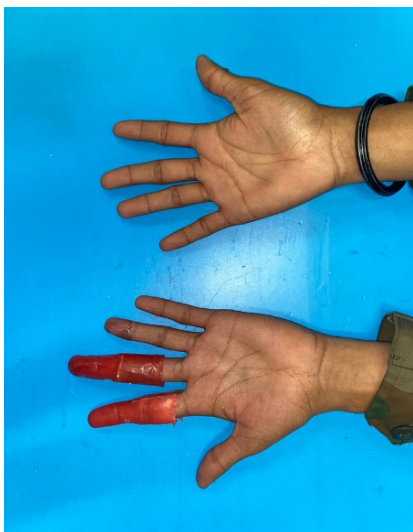**Fig. 6:** Characterization using extrinsic stains



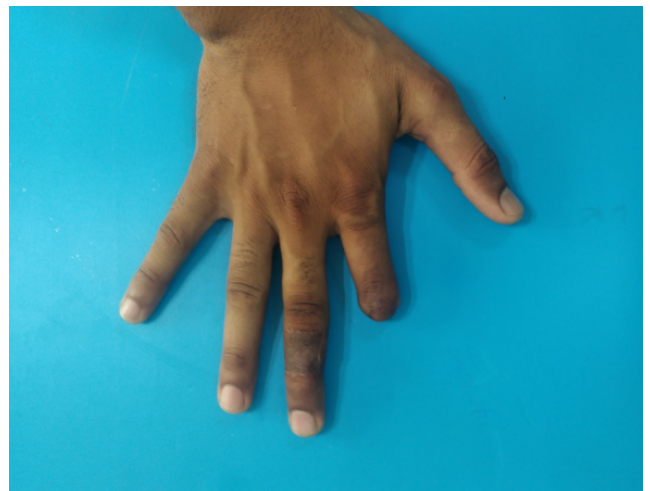**Fig. 4:** Putty index of right index and middle finger



**Fig. 7:** Prosthesis in situ

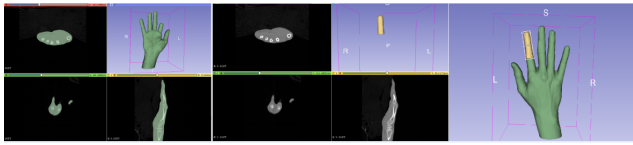


**Fig. 5:** Wax pattern trial

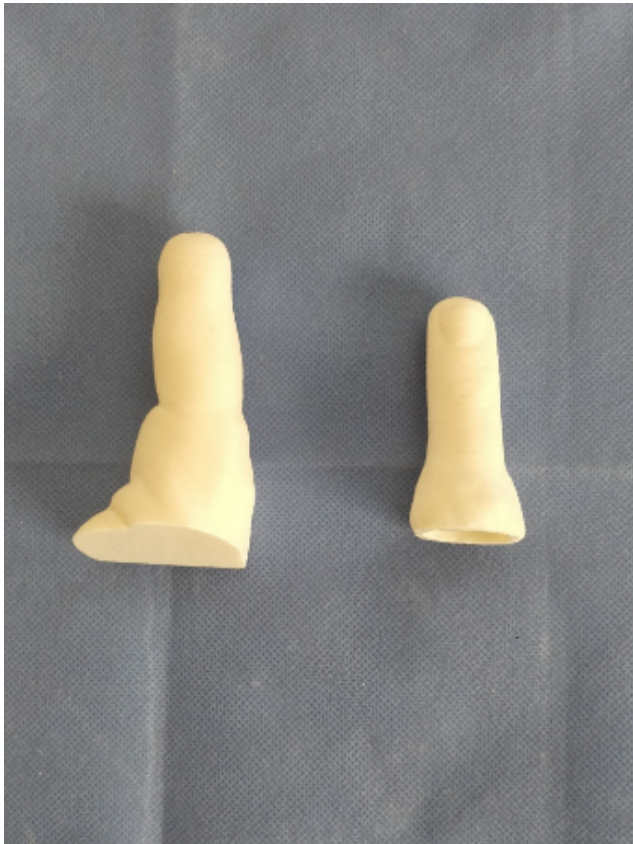

**Fig. 8:** Pre-treatment photograph





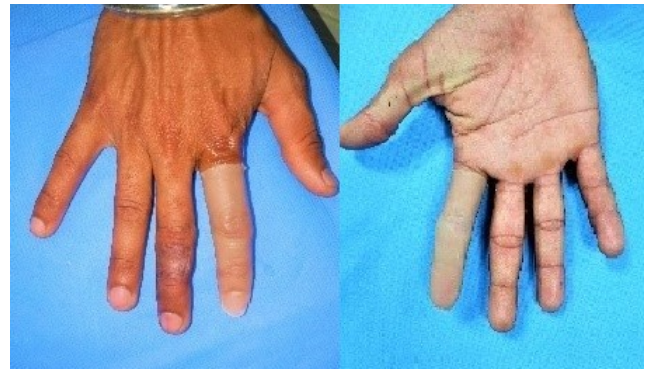**Fig. 9:** Designing of prosthesis and digital try in



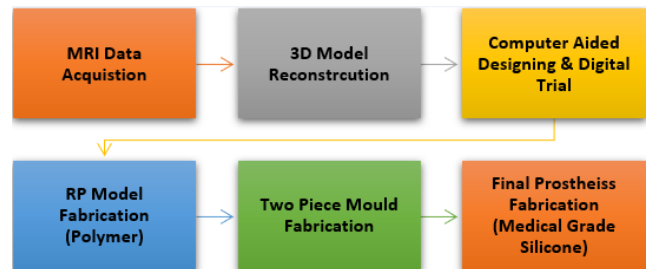
**Fig. 10:** 3-D printed template and stump



**Fig. 11:** Flasking of template and stump



**Fig. 12:** Prosthesis in situ



**Fig. 13:** Computer aided methodology for finger prosthesis fabrication

#### 4. Discussion

Rapid prototyping is a fast-growing manufacturing technology that is now being widely used for prosthetic rehabilitation of patients with various lost body parts. Reverse engineering or 3D digitizing<sup>7</sup> can be used to capture the morphology of deficient and normal part of the body. The latest CT/MRI systems combined with medical modelling software can yield precise anatomical details.<sup>8</sup> The design of a matching finger prosthesis by mirroring, positioning, and modifying to suit the remaining tissue on the deficient side requires experience, takes considerable time and can be error-prone. These problems can be overcome by using haptic CAD systems (such as Free Form) for design of prosthesis. Computer-aided manufacturing enables fast and accurate conversion from CAD model of the prosthesis to its physical realization.<sup>9</sup> Various rapid prototyping processes are available and the most commonly used in dentistry are stereolithography (SLA), selective laser sintering (SLS), fused deposition modeling (FDM), laminated object modeling (LOM), and 3D jet printing (3DP).<sup>10</sup>

The method used in this article for digitally fabricating finger prosthesis is highlighted (Figure 13). Both the cases had displayed utmost satisfaction along with marked improvement in disfigured esthetics. The conventional method of finger prosthesis fabrication as illustrated in case one involves extensive clinical and laboratory

procedures for which patient's cooperation is also required. But its application is limited in cases where the patient is uncooperative, has compromised neuromuscular coordination and is esthetically conscious. However, the field of RP gives promising solution to all these problems and restores defects with minimal errors. It gives results with superior esthetics, high accuracy, with minimal appointments, less operative time and is both patient & operator friendly manner.

## 5. Conclusion

Rehabilitating the amputated finger using 3D printing technique is a promising treatment option which provides the esthetics, function and psychological benefits to the patient with minimal appointments. Thus, digitalization of technology is helping yield prostheses with excellent form and function.

## 6. Declaration of patient consent

The authors certify that they have obtained all appropriate patient consent forms for the images and clinical data illustrated.

## 7. Conflict of Interest

The authors declare that there are no conflicts of interest in this paper.

## 8. Source of Funding

None.

## References

1. Parkes CM. Psycho-social transitions: Comparison between reactions to loss of a limb and loss of a spouse. *Br J Psychiatry*. 1975;127(3):204–10. doi:10.1192/bjp.127.3.204.
2. Desmond D, Maclachlan M. Psychosocial issues in the field of prosthetics and orthotics. *JPO J Prosthetics Orthotics*. 2002;14(1):19–22. doi:10.1097/00008526-200203000-00006.
3. Shanmuganathan N, Maheswari MU, Anandkumar V, Padmanabhan TV, Swarup S, Jibrán AH, et al. Aesthetic Finger Prosthesis. *J Indian Prosthodont Soc*. 2011;11(4):232–7. doi:10.1007/s13191-011-0074-9.
4. Sabolich J, Sabolich S. You're not alone, stories of 38 people who conquered the challenges of a lifetime. In: Oklahoma: Scott Sabolich Prosthetic and Research. vol. 354; 2005.
5. Botolin L, Gazroda S, Maver T, Ganter G. Use of Rapid Manufacturing Technology in Comprehensive Rehabilitation of a Patient with Physical Body Disorders; 2007.
6. Fujita S, Murayama T, Tamamoto M, Shimoe S, Makihira S, Sasahara K, et al. Design and Fabrication of the Mold of Finger Prostheses by Using CAD and 3d-Printer. In: CAD and 3d-Printer. 93rd Regular Meeting of Hiroshima University Dental Society. Hiroshima; 2009.
7. Reitemeier B, Notni G, Heinze M, Schone C, Schmidt A, Fichtner D, et al. Optical modelling of extraoral defects. *J Prosthet Dent*. 2004;91(1):81–4. doi:10.1016/j.prosdent.2003.10.010.
8. Sun W, Starly B, Nam J, Darling A. Bio-CAD modelling and its applications in computer-aided tissue engineering. *Comput Aided Des*. 2005;37(11):1097–14. doi:10.1016/j.cad.2005.02.002.
9. Petzold R, Zeilhofer HF, Kalender WA. Rapid prototyping technology in medicine: basics and applications. *Comput Med Imaging Graph*. 1999;23(5):277–84. doi:10.1016/s0895-6111(99)00025-7.
10. Peng Q, Tang Z, Liu O, Peng Z. Rapid prototyping-assisted maxillofacial reconstruction. *Ann Med*. 2015;47(3):186–208.

## Author biography

**Shikha Singh**, Resident

**Aakash Sethi**, Resident

**Amit Khattak**, Associate Professor

**Dinesh Kumar**, HOD

**V S Legha**, Associate Professor

**Deepak Kalia**, Assistant Professor

**Kamal Verma**, Assistant Professor

**Cite this article:** Singh S, Sethi A, Khattak A, Kumar D, Legha VS, Kalia D, Verma K. Digitising prosthetics: Clinical series. *IP Ann Prosthodont Restor Dent* 2022;8(1):64-68.