

Content available at: <https://www.ipinnovative.com/open-access-journals>

IP Annals of Prosthodontics and Restorative Dentistry

Journal homepage: <https://www.aprd.in/>

## Case Report

# Rehabilitation of post Covid mucormycosis maxillectomy defect with hollow obturator: A case series

Swapnil Chincholikar<sup>1,\*</sup>, Gaurav Lalwani<sup>2</sup>

<sup>1</sup>Consultant, Prosthodontics & Implantology, Bangalore, Karnataka, India

<sup>2</sup>Consultant, Oral and Maxillofacial Surgeon, Jabalpur, Madhya Pradesh, India



### ARTICLE INFO

#### Article history:

Received 25-01-2022

Accepted 28-01-2022

Available online 16-03-2022

#### Keywords:

PostCovid Mucormycosis

Hollow bulb Obturator

Maxillary defects

### ABSTRACT

India saw a devastating second wave of Coronavirus and along with the fatal nature of the disease the healthcare professionals saw a huge number of post Covid problems. One of these, is a fungal disease called mucormycosis which although an uncommon fungal infection can cause blackening of skin, redness, inflammation, sores and can encroach the eyes, lungs and even the brain. This warrants for extensive surgical resection and debridement of the necrosed areas resulting in maxillary and orbital defects. Intraoral defects in the maxilla cause communication with the nasopharyngeal complex. The surgically removed palate has a devastating effect on the appearance and speech of the patient. Obturator allows patients to eat and drink without letting the food to enter the oroantral cavities/ pharynx during mastication. This case series focusses on prosthetic rehabilitation of two patients with Hollow obturator post hemimaxillectomy in order to restore form and function.

This is an Open Access (OA) journal, and articles are distributed under the terms of the [Creative Commons Attribution-NonCommercial-ShareAlike 4.0 License](https://creativecommons.org/licenses/by-nc-sa/4.0/), which allows others to remix, tweak, and build upon the work non-commercially, as long as appropriate credit is given and the new creations are licensed under the identical terms.

For reprints contact: [reprint@ipinnovative.com](mailto:reprint@ipinnovative.com)

## 1. Introduction

Maxillary resection due to carcinoma and/or any infection leads to a multitude of problems which include anatomical disfigurement of the face, impaired and unintelligible speech due to hypernasality causing a significant impact on patient's quality of life. Maxillary necrosis occurs due to bacterial infections, such as osteomyelitis, viral infections, such as herpes zoster or fungal infections, such as mucormycosis, aspergillosis etc.<sup>1</sup>

Post COVID Mucormycosis has had a devastating effect on the patients. Mucormycosis is an opportunistic fungal infection, which mainly infects immunocompromised patients. Long term corticosteroid treatment in such susceptible patients and high fungal spore counts in the hospital setting create a conducive environment for fungal

infections. The infection begins in the nose and paranasal sinuses due to inhalation of fungal spores.<sup>1,2</sup> It can spread to orbital and intracranial structures either by direct invasion or through the blood vessels. The fungus invades arteries leading to thrombosis that subsequently causes necrosis of hard and soft tissue.<sup>1,3</sup>

Upon involvement of maxilla, surgical resection and debridement of the affected areas results in extensive maxillary defects. The defect may be in the form of a small opening resulting in communication from the oral cavity into the maxillary sinus, or it may include portion of the hard and soft palate, alveolar ridge and the floor of the nasal cavity.<sup>4</sup> In patients with extensive removal of the maxilla, in addition to facial disfigurement, hypernasal speech and masticatory difficulties, there may be fluid leakage through the nose, and maybe associated with acute and chronic episodes of sinusitis.<sup>4-6</sup>

This article presents 2 cases of prosthetic rehabilitation of hemimaxillectomy defects due to post COVID

\* Corresponding author.

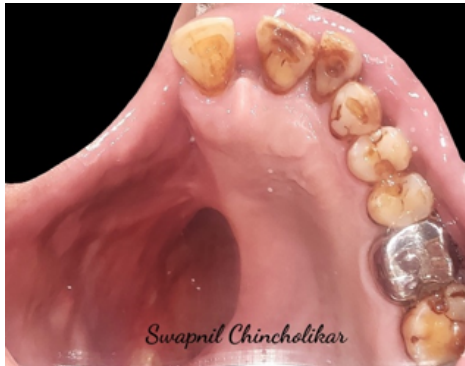E-mail address: [swapnil.chincholikar@gmail.com](mailto:swapnil.chincholikar@gmail.com) (S. Chincholikar).

mucormycosis with Hollow obturator.

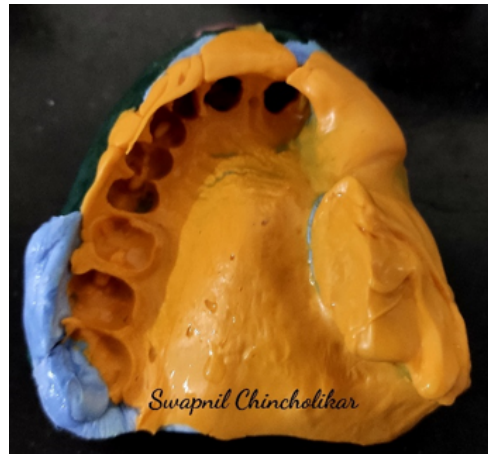
## 2. Case 1

A 65 year-old male patient reported to the clinic with a chief complaint of difficulty in consumption and mastication of food and unintelligible speech. Intraoral examination revealed large maxillary defect on the right side with oroantral communication and partially edentulous arch. (Figure 1)

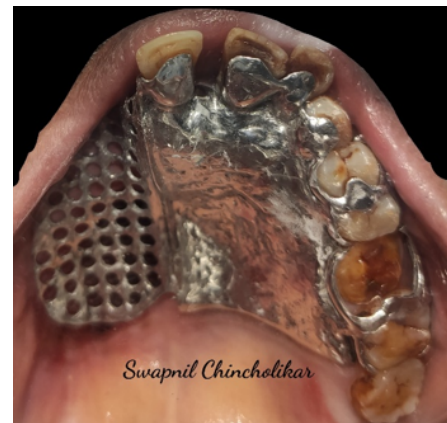The patient had undergone maxillectomy for post Covid-19 necrosis of maxilla due to mucormycosis six months back. The treatment plan was to fabricate a definitive hollow bulb obturator with a cast partial metal framework. Treatment Design for a Class-II defect was selected for this case according to design principles described by Aramany in 1978. The remaining teeth were 11,21,22,23,24,25,26,27 and 28.



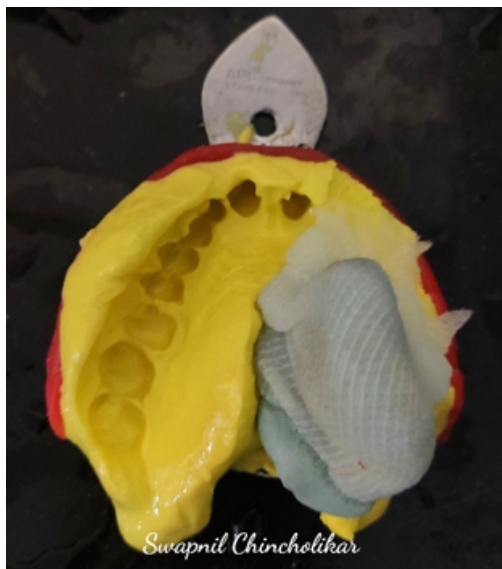**Fig. 1:** Intraoral defect



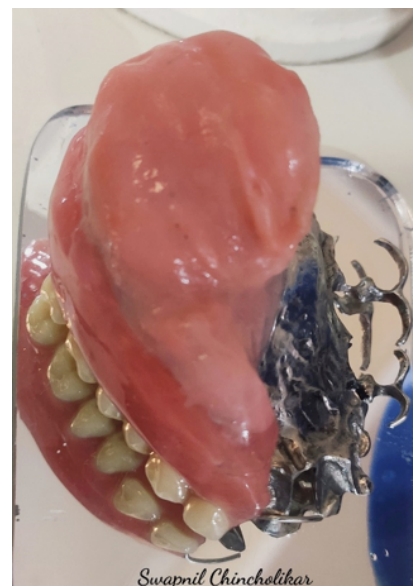**Fig. 3:** Final impression



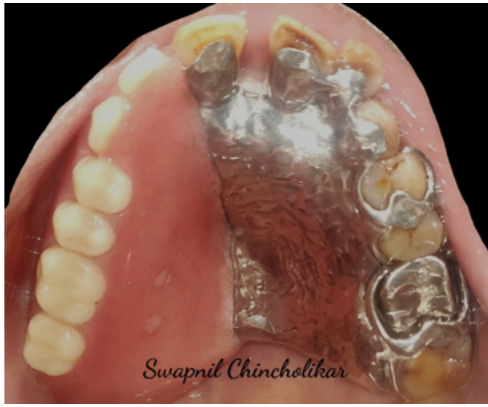**Fig. 4:** Framework trial



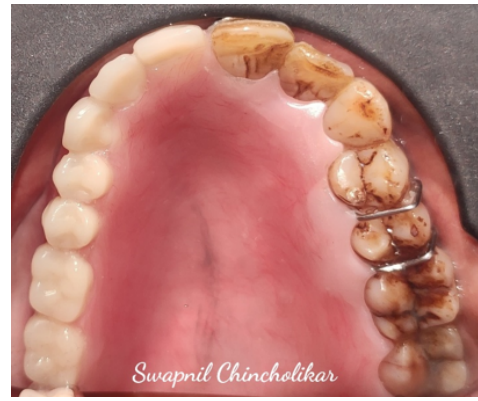**Fig. 2:** Primary Impression



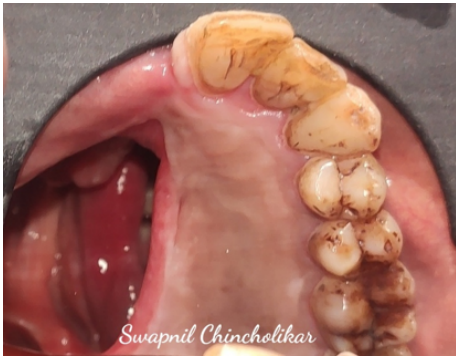**Fig. 5:** Final prosthesis



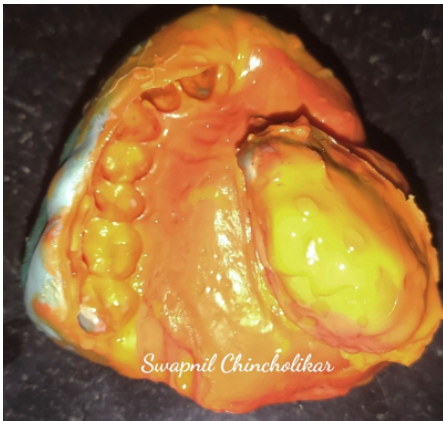
**Fig. 6:** Obturator insertion



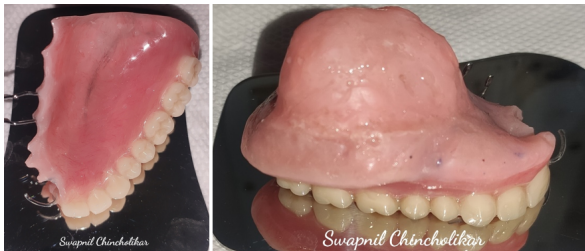**Fig. 10:** Obturator insertion



**Fig. 7:** Intraoral defect



**Fig. 8:** Final Impression



**Fig. 9:** Final prosthesis

A preliminary impression of the defect was made with putty impression material (GC Flexceed) wrapped in a gauze piece and picked up with irreversible hydrocolloid impression material (Tropicalgin, Zhermack) using a stock tray (Figure 2). After obtaining the primary cast, a special tray was fabricated with self-cure acrylic resin (DPI RR Cold Cure). Border moulding was done with greenstick material (DPI Pinnacle tracing sticks) and the full extent of the defect was recorded using putty impression (GC Flexceed) and a light body wash impression was made to record the undercuts which aid in anatomic retention (Figure 3). The master cast was obtained with Die stone (type IV dental stone),(Kalstone; Kalabhai).

The cast partial denture framework was fabricated and a heat cure temporary denture base was attached to it. A modelling wax occlusal rim was made to record bite registration and framework trial was done (Figure 4). Teeth arrangement and try-in were done. Occlusion, aesthetics, and phonetics were evaluated and found to be acceptable by the patient. The position of teeth was verified with phonetic tests that made the patient to pronounce /s/, /f/, /v/, and /th/ sounds.<sup>7-9</sup> The position of maxillary posterior teeth was guided by the position of mandibular posterior teeth. A full metal crown was planned on tooth no. 26 as it was previously Root canal treated. The cast partial framework had the following design: Cingulum rest seat on 11,21,22,23; Mesial rest seat on 25 and 27; Distal rest seat on 24 and 26 and a C-clasp on 11.

Final processed prosthesis was obtained with a hollow design to reduce the weight and was delivered to the patient (Figures 5 and 6). Occlusal adjustments were done to prevent dislodgement during excursions. The extensions of the prosthesis were checked and adjusted to eliminate any soft tissue impingement in the area of the defect. The patient was trained regarding the removal and insertion of prosthesis and post insertion and maintenance instructions were given. The patient was satisfied with the prosthesis upon follow-ups and was able to maintain speech and mastication.



### 3. Case 2

A 68 year-old male patient reported to the clinic with a chief complaint of difficulty in consumption and mastication of food and unintelligible speech. Intraoral examination revealed large maxillary defect on the right side with oroantral communication and partially edentulous arch. (Figure 7)

The patient had undergone maxillectomy for post Covid-19 necrosis of maxilla due to mucormycosis 5 months back. The treatment plan was to fabricate a hollow bulb acrylic obturator without cast partial framework as the patient did not have finances for the same. Treatment Design for a Class-I defect was selected for this case according to design principles described by Aramany in 1978. The remaining teeth were 21,22,23,24,25,26 and 27.

All the steps described in Case 1 for impression making, bite registration and trial were similarly performed (Figure 8). The obturator had the following design : A C-clasp on 21 and a ball ended embrasure clasp on the mesial and distal surfaces of 25(Figure 9). Final prosthesis was similarly obtained with a hollow design and delivered to the patient (Figure 10). He was happy and satisfied with the outcome and displayed good phonetics on subsequent follow-ups.

### 4. Discussion

In the above documented cases, the aim was to eliminate the communication of the oral and nasal cavity by giving an obturator prosthesis which not only provides adequate functions of chewing, swallowing, and speech but is also light in weight and gives an acceptable esthetic appearance. Extension of the hollow bulb into the maxillary defect helps in providing resonance during the speech. The fabrication of a hollow bulb obturator in patients with severe maxillary defects can provide retention and stability by decreasing the weight which otherwise is difficult to achieve.<sup>10,11</sup>

There are numerous other techniques available for taking support for prosthetic rehabilitation by placement of zygomatic and pterygoid implants. Owing to great psychological and financial impact maxillary resections and long Covid symptoms had on these patients, hollow obturators were agreed upon as they had shorter treatment duration, were relatively inexpensive and provided a sense of immediate relief to the patient in terms of phonetics and mastication.

### 5. Conclusion

Fabrication of a hollow obturator is an easy and inexpensive method of prosthetic rehabilitation following maxillary

resection due to post Covid Mucormycosis. Hollowing of the prosthesis not only reduces the weight but also adds to resonance of speech. The obturator provides satisfactory esthetics, phonation and function and improves the patient's quality of life and confidence.

### 6. Conflict of Interest

The authors declare that there is no conflict of interest.


### 7. Source of Funding

None.

### References

1. Soman R, Sunavala A. Post COVID-19 Mucormycosis - from the Frying Pan into the Fire. *J Assoc Physicians India*. 2021;69(1):13–4.
2. Hsu LY, Chia PY, Lim JF. The Novel Coronavirus (SARS-CoV-2) Epidemic. *Ann Acad Med Singap*;49(105):105–107.
3. Leitner C, Hoffmann J, Zerfowski M, Reinert S. Necrotizing soft tissue lesion of the face. *J Oral Maxillofac Surg*. 2003;61(11):1354–8. doi:10.1016/s0278-2391(03)00740-7.
4. Pogrel MA, Miller CE. A case of maxillary necrosis. *J Oral Maxillofac Surg*. 2003;61(4):489–93. doi:10.1053/joms.2003.50095.
5. Gennaro FD, Pizzol D, Marotta C, Antunes M, Racialbuto V, Veronese N, et al. Coronavirus diseases (COVID-19) current status and future perspectives: a narrative review. *Int J Environ Res Public Health*. 2020;17(8):2690. doi:10.3390/ijerph17082690.
6. Kumar D, Malviya R, Sharma PK. Corona virus: a review of COVID-19. *EJMO*. 2020;4(1):8–25. doi:10.14744/ejmo.2020.51418.
7. Murray CG. Re-establishing natural tooth position in the edentulous environment. *Aust Dent J*. 1978;23(5):415–21.
8. Pound E. Utilizing speech to simplify a personalized denture service. *J Prosthet Dent*. 1970;24(6):586–600.
9. Pound E, Hsu LY, Chia PY, Lim JF. Let /S/ be your guide. *J Prosthet Dent*. 1977;38(5):482–9.
10. Mani UM, Mohamed K, Kumar AK, Inbarajan A. A modified technique to fabricate a complete hollow obturator for bilateral maxillectomy in a patient with mucormycosis-A technical case report. *Special Care Dent*. 2019;39(6):610–16.
11. Gowda M, Shashidhar MP, Prakash P, Sahoo NK. Rehabilitation of a defect secondary to sino-orbital mucormycosis-A prosthodontic challenge. *IP Ann Prosthodont Restor Dent*. 2021;7(1):41–5.

### Author biography

**Swapnil Chincholikar**, Consultant  <https://orcid.org/0000-0003-4953-8533>

**Gaurav Lalwani**, Consultant

**Cite this article:** Chincholikar S, Lalwani G. Rehabilitation of post Covid mucormycosis maxillectomy defect with hollow obturator: A case series. *IP Ann Prosthodont Restor Dent* 2022;8(1):38-41.