

Content available at: <https://www.ipinnovative.com/open-access-journals>

IP Annals of Prosthodontics and Restorative Dentistry

Journal homepage: <https://www.aprd.in/>

## Original Research Article

# Incisive canal: Variations on cone beam computed tomography and its impact on dental implant planning

Heena Sonawane<sup>1,\*</sup>, Kaustubh Sansare<sup>2</sup>, Freny Karjodkar<sup>2</sup><sup>1</sup>Dept. of Dentistry, HBTMC and Dr. R. N. Cooper Hospital, Mumbai, Maharashtra, India<sup>2</sup>Dept. of OMDR, Nair Hospital Dental College, Mumbai, Maharashtra, India

## ARTICLE INFO

## Article history:

Received 13-01-2022

Accepted 27-01-2022

Available online 16-03-2022

## Keywords:

Incisive canal

Implant

Cone Beam Computed Tomography

Anterior Maxilla

## ABSTRACT

**Background:** To assess the morphologic patterns of Incisive canal (IC), distance between the IC and buccal cortical plate in partially edentulous patients, distance between the maxillary central incisor (MCI) and IC in dentulous patients and measure length and width of IC on cone beam computed tomography (CBCT) scan for implant placement.

**Materials and Methods:** A total of 104 CBCT scans consisting of 52 dentulous and 52 edentulous patients aged between 20 and 60 years were retrospectively reviewed from the archives of oral radiology unit. Kodak 9000C 3D unit was used for obtaining these scans. The morphology, location and dimensions of IC was analysed by two observers. The correlation of age and gender with all the variables was evaluated.

**Results:** The most common pattern found in this study was slanted straight SS (36.5%). A single canal was reported in 95.19% scans. The mean distance from buccal cortical plate to IC was 5.09 while that from MCI to IC was 2.33. The mean canal width of IC in partially edentulous scans was 2.96 while that in dentulous scans was 3.11. The mean canal length of IC was 10.1 in partially edentulous group while it was 10.68, in dentulous group.

**Conclusion:** The study population is safe for implant placement in regards to the pattern and number of canals of IC and compromised with respect to the bone available anterior to the IC. The implantologists' needs to be aware of these shortcomings while planning implant in the upper anterior region.

This is an Open Access (OA) journal, and articles are distributed under the terms of the [Creative Commons Attribution-NonCommercial-ShareAlike 4.0 License](https://creativecommons.org/licenses/by-nc-sa/4.0/), which allows others to remix, tweak, and build upon the work non-commercially, as long as appropriate credit is given and the new creations are licensed under the identical terms.

For reprints contact: [reprint@ipinnovative.com](mailto:reprint@ipinnovative.com)

## 1. Introduction

Incisive canal (IC) is a vital anatomical structure located posterior to the maxillary central incisors.<sup>1,2</sup> The canal is either a single canal or known to divide into two or more canals on its way to the nasal cavity, terminating at the nasal floor with two openings (nasopalatine foramina/foramina of Stenson) on either sides of the nasal septum. The oral opening is funnel shaped located in the midline of the anterior palate, immediately below the incisive papilla and is called the incisive foramen.<sup>3</sup> Important structures passing through the canal are nasopalatine (incisive) nerve and the

terminal branch of the descending nasopalatine artery.<sup>4</sup> The nasopalatine duct is a separate entity passing through the canal and is present only during the fetal life.<sup>5</sup>

It needs to be noted that 17% of the US population have missing maxillary teeth.<sup>6</sup> It could be postulated that this may well be the scenario the world over.<sup>7,8</sup> The anterior maxilla is the common site for implant placement.<sup>9</sup> It is also a known fact that placement of implant in the maxillary anterior region is a difficult task for the clinicians mainly because of the biomechanical, phonetic and esthetic demands of the patient.<sup>10</sup> A study involving 20 years of review of implants concluded that there is an increased early implant failure rates in maxillary anterior region.<sup>11</sup>

\* Corresponding author.

E-mail address: [drheenasonawane135@gmail.com](mailto:drheenasonawane135@gmail.com) (H. Sonawane).

Studies have stressed the importance of anatomical factors for survival of implants.<sup>12</sup> Implant placement in the vicinity of the IC may cause sensory dysfunction and/or non osseointegration of the implant.<sup>13</sup> This endangers the success of the implant placement. In order to avoid such complications the morphology, dimensions and the distance of IC from the labial cortical plate should be evaluated before implant placement. Studies had assessed IC prior to implant placement on CT scans.<sup>13–16</sup> Given the better spatial resolution of CBCT and the widespread use of CBCT for pre implant assessment it was important to look in to these parameters on a limited view CBCT scan.<sup>17</sup> Earlier studies have reported differences in the dimensions of the IC, its morphologic patterns and the distances from labial cortical plate to the IC in the Korean,<sup>14</sup> Swiss,<sup>15</sup> Belgian,<sup>13,15</sup> Israeli,<sup>16</sup> Iranian,<sup>18</sup> populations. Nevertheless there is a scarcity of documentation in anatomic variations of IC morphology and patterns.<sup>3</sup> The differences in pattern and dimensions of IC in these earlier study populations led us to hypothesize that there could be differences among world populations.

The aim of the study therefore was to study the morphologic patterns of IC in the Indian study cohort, assess the distance between the maxillary central incisor (MCI) and the IC in dentulous patients, assess the distance between the IC and buccal cortical plate in partially edentulous patients, measure the length and width of IC at the nasal floor and incisal (oral) opening in both dentulous and partially edentulous patients.

## 2. Materials and Methods

This study was approved by the institutional ethical committee and clearance was taken and was conducted in accordance with Declaration of Helsinki. A total of 630 CBCT scans from February 2018 to July 2019 were retrospectively reviewed from the archives of oral radiology unit for their compatibility with the inclusion and exclusion criteria. A routine consent was taken before taking the scans for all the patients. The scans were grouped in two age groups 20-40 years and 41-60 years. The remaining age groups were excluded from this study. All partially edentulous (only one missing MCI) scans for whom a CBCT had been requested for implant placement and all dentulous scans in which a CBCT has been taken for any other maxillofacial lesions not in the maxillary anterior region were included in the study. The scans with pathology involving the upper anterior region maxillary central incisors not in the arch were excluded from this study. Scans with streak artifacts or beam hardening effect were also excluded from the study. A total of 104 scans were finally selected for the study consisting of 52 dentulous scans and 52 edentulous scans.

CBCT examination was done using a Carestream 9000C 3D unit (Carestream Health Inc., 150 Veronal Street,

Rochester, NY 14608, USA). This machine was operated at 70 to 80 kVp, current 10 ma FOV 5 x 3.7 cm, voxel size 0.076mm, Gray scale of 14 bits, image acquisition time of 10.8 seconds, and equivalent dose 38  $\mu$  sv per quadrant for a single volume.

The acquired data was reconstructed with a 0.2 mm section thickness. All the images were acquired in the Digital Image Communication in Medicine (DICOM) format and evaluated using the Carestream Imaging Software (CSI). This allowed a detailed observations and dimensional measurements on a computer screen.

## 3. Observers

Two maxillofacial radiologists with more than 5 years of experience in reporting CBCT scans were selected as observers. The two observers performed the IC pattern identification as well as dimensional measurements. Observers were oriented by reviewing and discussing CBCT scans of partially edentulous and dentulous maxilla each till the point they were comfortable doing these assessments. One observer carried out the assessment twice. This allowed calculations of the coefficient of variation for intraobserver and interobserver variability. For the study, the scans were reviewed by both the observers independently on a Dell Inspiron N 5110 laptop LCD Screen 15.6" WXGA with a DICOM Workstation using CSI software. Each scan was reviewed in axial, coronal and sagittal sections. The observers were allowed to use magnification, modify screen contrast and the other tools like measurement tool, nerve canal tool and angle mode for evaluating the CBCT scans.

The Morphologic pattern of IC was analysed mainly on the sagittal sections. The CBCT reconstructions were reoriented with reference to that horizontal plane which was the nasal floor. Based on the vertical line of the horizontal plane, ICs whose course changed by  $>10^\circ$  from vertical were regarded to be "slanted", and those whose course changed by  $<10^\circ$  from the vertical were regarded as "vertical". This was done using the angle tool.(Figure 1). The number of canals were evaluated on the axial sections.(Figure 2)

### 3.1. Measurements

In order to have an idea on the available bone anterior to the IC for potential implant placement in the partially edentulous scans, sagittal section was selected on which the maximum canal length could be visualized. The axial section was used for the determination of the mid of the edentulous region which was marked as a point over the crestal bone. Using oblique slicing the sagittal plane was oriented such that it passes through the mid crestal point and section which shows the maximum length of the canal. From these slices, the buccopalatal bone width anterior to the canal was assessed at the crestal, middle and apical levels of the canal. Measurements of horizontal distances

were performed from the outer canal wall to the buccal bone (Figure 3).

Similarly in case of dentulous scans, the sagittal plane was oriented such that it passes through the pulp canal of the MCI and the section showing the maximum length of the canal. The measurements were taken from the alveolar bone between the tooth and the IC on the crestal, middle and apical points of the root of the central incisor. Measurements were again performed from the outer canal wall to the inner cortical plate of the alveolar bone (Figure 4).

The length of IC and its width were measured at the nasopalatine and incisal (oral) openings in the sagittal scan in dentulous and partially edentulous groups. All measurements were noted in millimetres (Figure 5).

### 3.2. Biostatistics

The data was transferred to Microsoft Excel 2010 software (Microsoft Corporation) for statistical analysis. Data analysis was done with the help of SPSS Software version 15. All quantitative data was presented with the help of Mean, Standard Deviation (SD), comparison between groups was done with the help of unpaired t test and correlation among study parameters was done with the help of Pearson correlation coefficient.

The level of significance was chosen at 5%. ANOVA (analysis of variance) design was used to describe the influence of gender, dental status and canal morphology on dimensional characteristics.

Qualitative data was presented with the help of frequency and percentage table, association among study group was evaluated with the help of Chi Square test.

Inter and intra observer variation was expressed using the pearsons co-relation.

## 4. Results

The dentate group consisted of 26 males and 26 females and the edentulous group consisted of scans from 31 males and 21 females.

### 4.1. Pattern

The most common pattern found in this study was slanted straight SS (36.5 %) followed by slanted curved superiorly SCS (35.5 %) and vertically curved VC (17.3%). Slanted straight SS and slanted curved superiorly SCS had an almost equal distribution in both the genders, while vertically curved VC was found most common in males (Figure 1).

### 4.2. Number of canals at nasal floor

The single canal was reported in 99 scans (95.19%). Two canals were reported in 3 scans (2.88%). Three and four canals were reported in one scan each (0.96%).

### 4.3. Distance between the IC and buccal cortical plate

#### 4.3.1. Partially edentulous

The mean distance from buccal cortical plate to IC was 5.09, with a range of 1.1- 10.2. The mean(range) distance from the IC to the buccal cortical plate at apex level was  $6.79 \pm 1.99(1.1-10.2)$ , at mid-level was  $4.4 \pm 1.60(1.9-7)$  and at the crestal level was  $3.88 \pm 1.26(1.5-7.6)$  (Table 1).

The distance between the IC and buccal cortical plate at the apex and mid level show significant difference in the two age groups, with a P value 0.04 at the apical and 0.05 at the mid level respectively.

#### 4.3.2. Dentulous group

The mean distance from MCI to IC was 2.33, with a range of 0.3- 8. The mean (range) distance from the IC to the buccal cortical plate apex level was  $3.95 \pm 1.78(0.5-8)$ , at mid-level was  $2.09 \pm 1.02(0.4-5)$  and at the crestal level was  $0.96 \pm 1.04(0.3-2.9)$  (Table 3). The mean values obtained were statistically significant at the cervical level for males (1.08) and females (0.84), with P value 0.04.

### 4.4. Width of the IC at the nasal floor and the incisal openings

#### 4.4.1. Partially edentulous group

The mean canal width of IC was 2.96, with a range of 0.2- 5.6. The mean (range) width of IC at the nasal floor level was  $2.38 \pm 0.94(0.2-5.4)$  while that at the incisal opening level was  $3.46 \pm 1.01(1.6-5.6)$  (Table 2)

There was a significant difference in the width of the IC at the incisal opening level in the two age groups, with P value 0.0006.

#### 4.4.2. Dentulous group

The mean canal width of IC was 3.11, with a range of 0.6- 5.9. The mean(range) width of IC at the nasal floor level was  $3.00 \pm 1.24(0.6-5.9)$  while that at the incisal opening level was  $3.22 \pm 0.91(1.7-5.3)$  (Table 4)

#### 4.4.3. The length of the canal

The mean canal length of IC was 11.30, with a range of 6.8 -17.3 in the dentulous group while it was 10.1(5.1-15.3) in the partially edentulous group. (Table 2 and 4)

The partially edentulous group showed a significant difference in the length of the canal between the two age groups with a P value 0.04.

### 4.5. Inter and intra observer variation

#### 4.5.1. Partially edentulous group

The inter observer pearson correlation values for the partially edentulous scans were 0.942, 0.979 and 0.778 for the width at the apex, mid and cervical level respectively suggesting that there was a high degree of agreement

between the two observers.

The intra observer pearson correlation values for the partially edentulous scans were 0.992, 0.993 and 0.669 for the width at the apex, mid and cervical level respectively suggesting that there was a high degree of agreement between the two sessions of the observer 1.

4.5.2. Dentulous group

Inter and intra observer variation: The inter observer pearson correlation values for the dentulous scans were 0.99, 0.89 and 0.96 for the width at the apex, mid and cervical level respectively suggesting that there was a high degree of agreement between the two observers.

The intra observer pearson correlation values for the dentulous scans were 0.99, 0.98 and 0.96 for the width at the apex, mid and cervical level respectively suggesting that there was a high degree of agreement within the observer.

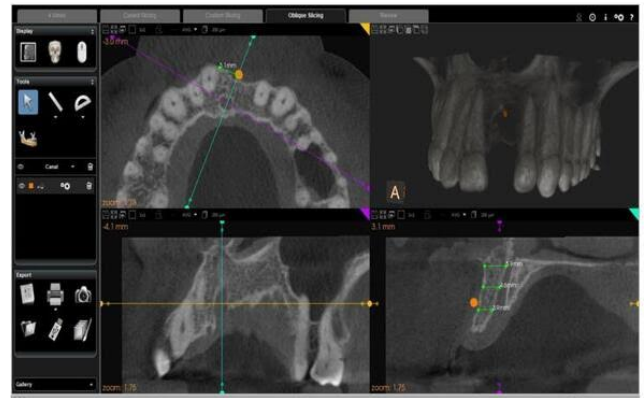

Fig. 3: Measurement of the distance between the buccal cortical bone and the IC done using oblique slicing tool in partially edentulous scans; the slice passing through the mid crestal point and the IC. The sagittal section was used to measure the distances at three levels crestal, mid and the apical levels of the IC.

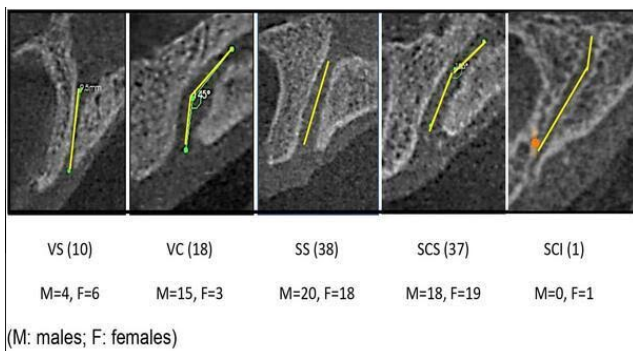


Fig. 1: Patterns of Incisive Canal (IC)

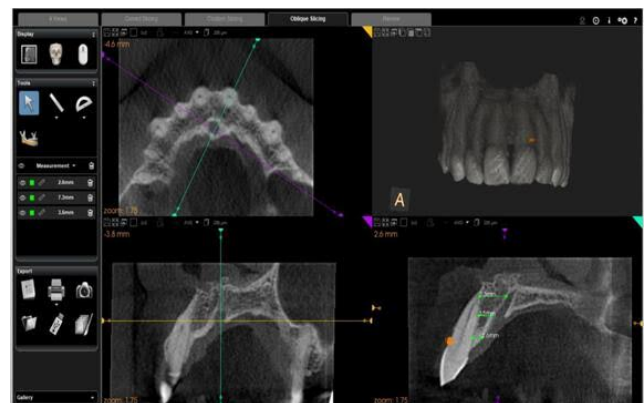

Fig. 4: Measurement of the available alveolar bone between the MCI and the IC done using oblique slicing tool in dentulous scans; the slice passing through the pulp canal of the MCI and the IC. The sagittal section was used to measure the distances at three levels crestal, mid and the apical levels of the root of the MCI.

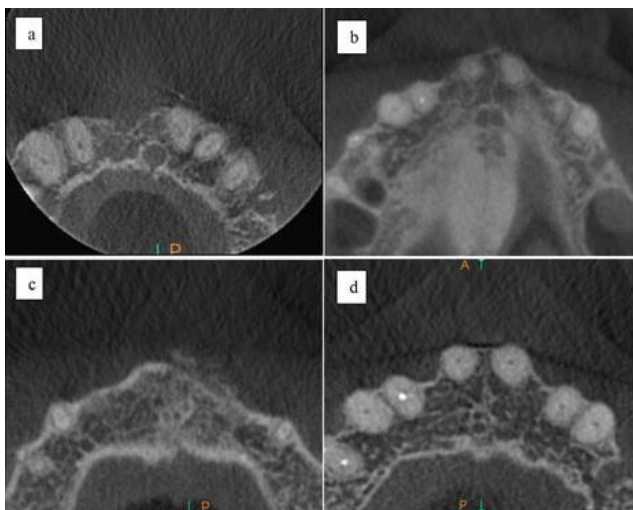


Fig. 2: a,b,c,d: Axial section showing number of canal openings; a: One b: two; c: Three and; d: Four respectively.

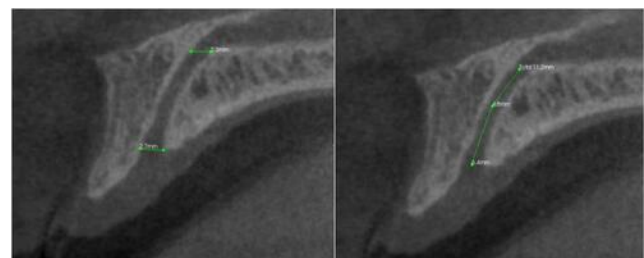


Fig. 5: Sagittal section of the CBCT scan showing the length of the canal using the polyline tool and the width of the canal using the single measure tool at the nasal and the oral openings.

**Table 1:** Distance between the IC and buccal cortical plate in partially edentulous scans of patients in age groups 20 -40 years and 41 - 60 years.

Age groups in years	Mean width of Bucco cortical in mm (apex)	Mean width of Bucco cortical width in mm (mid)	Mean width of Bucco cortical width in mm (crestal)
20 - 40	7.37	4.75	3.93
41 - 60	6.22	4.04	3.84

**Table 2:** Width of IC at nasal floor and incisal opening level and the length of the canal in partially edentulous scans of patients in age groups 20 - 40 years and 41 - 60 years.

Age groups in years	Mean width of the canal at the nasal floor opening(mm)	Mean width of the canal at the incisal opening(mm)	Mean length of the canal(mm)
20 - 40	2.35	3.02	12.03
41 - 60	2.42	3.91	10.58

**Table 3:** Distance between the IC and MCI in dentulous scans of patients in age groups 20 - 40 years and 41 - 60 years.

Age groups in years	Mean width between IC and MCI in mm(apex)	Mean width between IC and MCI in mm(mid)	Mean width between IC and MCI in mm(crestal)
20 - 40	4.32	2.23	0.99
41 - 60	3.58	1.95	0.94

**Table 4:** Width of IC at nasal floor and incisal opening level and the length of the canal in dentulous scans of patients in age groups 20 - 40 years and 41 - 60 years.

Age groups in years	Mean width of the canal at the nasal floor opening(mm)	Mean width of the canal at the incisal opening(mm)	Mean length of the canal(mm)
20 - 40	2.99	3.27	10.31
41 - 60	3.01	3.18	10.07

## 5. Discussion

The anterior maxillary area is considered a region with high esthetic challenges, compounded with the close proximity between the IC and the roots of the central maxillary incisors. This emphasizes the need for a careful radiographic analysis during implant planning in this region. Previous studies have also concluded that the location and variability in IC may hamper implant treatment. Mraiwa et al 2004<sup>13</sup> Krout and Boyden<sup>19</sup> based on CThad earlier stated that in approximately 4% of cases implant placement is affected because of the size of IC. Apart from this the amount of bone available from the IC to the buccal cortical plate is also vital. Considering the widespread use of CBCT in pre implant bone assessment, it was vital to revisit the IC and the bone width on the CBCT.

### 5.1. Pattern

The present study demonstrates that the most common patterns of the IC were slanted straight (SS) and slanted curved superiorly (SCS). An interesting finding was the detection of an additional pattern, though only one case, hitherto unreported was found in our population. This pattern was labelled as slanted curved inferiorly (SCI). This pattern, we believe is the mirror image of the slanted curved pattern found in the other population. The slanted curved

pattern of other population will hence forth be termed as slanted curved superiorly for convenience of comparison. It needs to be noted that dental implant placement in the SCI type of pattern is safer as the angle of the IC is away from the canal. Song WC et al<sup>14</sup> demonstrated the most common type as VS (46.4%), followed by SS (14.3%), VC (14.3%) while Thakur AR et al<sup>20</sup> found SS to be the most common pattern. If we consider the common patterns of IC and the bucco-palatal inclination of the implant to be placed, the SS appears to be safe for the implant placement. Literature does not mention the gender prevalence for the IC pattern significantly. This was in concurrence with the present study. However the VC pattern was seen predominantly in males.

### 5.2. Number of canals at the nasal floor

Studies had discussed vast variability in the number of canals. An important reason for this is because there has been inconsistency in the literature at what level these canals are assessed. Sicher has reported that one to six separate foramina might be present,<sup>21</sup> Mraiwa et al.<sup>13</sup> observed four canals at the nasal floor level using a spiral CT in the Belgian population. Another study on Belgian population<sup>15</sup> found both one (44%) and two (37%) canals using a spiral CT at the nasal floor level. Song et al.<sup>14</sup> observed two foramina at

the mid-level using micro CT.

Surprisingly one of the studies<sup>17</sup> on CBCT (0.125 voxel size), coronal view, demonstrated that single canal (45%) was common followed by Y shaped canal (40%) while in other studies the Y shaped was more common.<sup>18,22,23</sup> It is a known fact that some of these foramina consists of the neural bundle and some others the vascular bundle.<sup>16</sup>

Interestingly, a majority of the scans assessed in this study (95.19%) demonstrated one foramina at the level of the nasal floor. This probably suggests that for the study population both the neural and the vascular component are present in a single canal. The present findings are not supported by any earlier study. This variation could also be attributed to differences in imaging modality and sample size. Future studies could also incorporate this in prevalence studies. It could therefore be inferred that the study cohort is at much lesser risk for IC perforation during implant placement. Additionally this also suggests that a lower dose of local anaesthesia would be needed for the study population to anesthetize this region. Nevertheless it needs mention that the branches of nasopalatine nerve also exists in the median maxillary suture.<sup>16</sup>

### 5.3. Distance between IC and buccal cortical plate

#### 5.3.1. Partially edentulous group

Cheng et al<sup>24</sup> found an average width as 7.8mm, while Barkin<sup>25</sup> noted the average width as 5.9 mm. Mraiwa N et al<sup>13</sup> reported with an average width of 7.4mm (2.9 to 13.6mm) in 34 spiral CTs. The measurements were done at the three levels which approximately matched with the three levels of the present study. Bornstein et al<sup>17</sup> reported with increasing width from the crestal (6.5mm), mid (6.59mm) to the apical level (7.6mm) in 100 CBCTs'. Fukuda et al<sup>22</sup> found width at similar levels, crestal (4.06mm), mid (5.08mm) and apical (8.42mm). Though these studies measured the width at three different levels, these levels were at a more crestal level than that used in the present study. They had the mean values generally higher for male subjects at the mid and the crestal levels. In this study, the bucco cortical width at the apex, mid and crestal levels was similar for both males and females. This again was not in concurrence with the earlier study. It could therefore be inferred that skeletally males and females for the study population are similar. There was a significant difference in the bucco cortical width at the apex and mid levels between the two age groups which suggests that we should be more careful while placing implants in the elderly age group, or we can consider use of graft or more tapered implants. There are inconsistencies again on the level at which these widths were measured as well as the imaging modality. In the present study we had measured the average at three different levels which would give the clinician an idea on the precise amount of bone available at these levels. We believe that future studies could concentrate on the width at three

different levels. The average width in our study was 5.09 (0.9-10.9). As has been reported earlier<sup>13</sup> it is important to note that the range would be vital to consider than the mean. This is because the mean of some cases in this study were below the optimal width needed for successful implant placement.

### 5.4. Distance between the IC and MCI

#### 5.4.1. Dentulous group

The values obtained for the distance between the IC and MCI were statistically significant at the cervical level for males and females, with higher values for males. This was not in concurrence with the findings of Chatriyanuyoke P et al.<sup>26</sup> The mean value in this study was generally higher for male subjects at the mid root level compared to that in females. It could therefore be inferred that there could be skeletal differences for the two study population. Chatriyanuyoke P<sup>26</sup> demonstrated the mean values at two levels as 5.02mm (apical) and 3.05mm (mid) which was more than that found in this study.

Again, in the present study the distance from IC to the MCI was done at three levels which gives the clinician a precise idea of the available bone between the IC and MCI during immediate implant placement.

These values could be vital during immediate implant placement.

#### 5.4.2. Width of the IC at the nasal floor and incisal opening level

Liang X et al<sup>15</sup> found the average diameter to be 3.6mm using a spiral CT scan. Moreover this study does not identify at what level this dimension was measured, also this study was done in a mixed dentulous edentulous skulls.

#### 5.4.3. Partially edentulous

A study by Mariwa et al<sup>13</sup> done mainly in edentulous patients on spiral CT, found the mean width at the incisal opening level ranging from 4.3 to 6 mm while at the nasal level the mean ranged from 3.1 to 5.1mm. Another study<sup>17</sup> on spiral CT found the average width to be ranging from 3.96 to 4.96mm at the incisal level while at the nasal floor level it ranged from 2.95 to 4.10mm. Thakur AR et al<sup>20</sup> reported the mean width of the IC ranging from 1.4 to 5.9mm at the incisal levels, while at the nasal level it was 0.5 to 5.6mm. The findings of our study ranged from 2.98 to 4.13mm at the incisal level while at the nasal floor level ranged from 2.15mm to 2.77mm was in agreement with these studies.

In the present study the width of the IC at the incisal opening increases as the age increases. This could be attributed to the ridge resorption at the crestal level<sup>15,16</sup> Moreover, it was found in this study that the average IC width was more at the incisal opening as compared to the

nasal floor opening level. This could be challenging for implant placement.

#### 5.4.4. *Dentulous group*

This study also reveals no significant correlation between the width of the IC at the nasopalatine and incisal openings and different age groups. Barkin et al<sup>25</sup> found the mean width of the canal ranging from 3.76 to 5.12mm at the incisal and nasal levels respectively, while Khojastepour L et al<sup>23</sup> found its mean ranging between 2.92 to 3.8mm at both the nasal and 3.03 to 3.21mm at the incisal levels. In the present study, the mean of the widths was ranging from 2.99- 3.01mm at the nasal levels and 3.18-3.27mm at the incisal levels which is comparable with the study by Khojastepour L et al.<sup>23</sup>

It is a known fact that the shape of IC is commonly cylindrical or conical<sup>15</sup> Moreover, it was found in this study that the average IC width was more at the incisal opening as compared to the NP opening level. The implantologist should be aware of this difference.

#### 5.5. *Length of the canal*

##### 5.5.1. *Partially edentulous*

Earlier studies found a length of IC as 8.1,<sup>13</sup> 10.4,<sup>14</sup> 9.9,<sup>15</sup> 10.7,<sup>16</sup> 10.99<sup>17</sup> and 10.34<sup>23</sup> The finding of our study (10.21) was consistent with that of the earlier studies. There was a statistically significant difference between the length of the canal, the elder age group showing lesser length when compared to the younger age group which is because of the physiological ridge resorption. At the same time this interpretation should be viewed with caution, as one of the limitations of this study was that there was no data available for the time of extraction or time elapsed since extraction in this study. Previous study shows that there was statistically significant difference only when the time of extraction was available.<sup>17</sup>

##### 5.5.2. *Dentulous group*

There was no statistically significant difference for the length of the canal between different age groups. This was plausible as the length would not change significantly in dentulous groups with increase in age.

#### 5.6. *Comparative analysis between the dentulous and the edentulous group*

##### 5.6.1. *Length of IC*

There was a marginal decrease of the length in the edentulous group. This decrease in length is attributed to the edentulism and progressive ridge resorption after extraction. This was in agreement with the earlier study assessing the length.<sup>15</sup>

##### 5.6.2. *Width at nasal floor level and incisal level*

There was a significant difference between the two age groups for the width of the canal at the incisal level in the partially edentulous scans. In spite of this difference, the bone available anterior to the canal is adequate for implant placement, because at the crestal level there is no significant difference in the two age groups. The findings of this study needs to be compared with caution as the earlier study was done on a CT scan and also there is ambiguity on what level these measurements were made.

## 6. Conclusion

As placement of an implant in close proximity to IC could lead to permanent sensory damage, it is important that the clinician also assess the IC apart from bone quality and quantity on a CBCT scan. The two most common patterns found in this study, (SS and SCS) seem to be safer and best suited for the implant placement. The single canal IC also renders this population relatively safe for implant placement. The clinician however needs to be cautious in planning implant in this region for the elderly age group where grafts or placing more tapered implants should be considered.

## 7. Clinical Significance

Precise knowledge about the IC is utmost important while placing the implants in the maxillary anterior region or it may lead to permanent sensory loss in the region. An interesting finding was the detection of an additional pattern, though only one case, hitherto unreported was found in our population which was slanted curved inferiorly (SCI). This pattern we believe is the mirror image of the slanted curved found in the other studies. It needs to be noted that dental implants in the SCI type of pattern is safer as the angle of the IC is away from the canal.

## 8. Acknowledgement

I am greatly thankful to Mr. Shirish Sharma for reviewing the statistics of the study in details and giving his valuable inputs.

## 9. Conflict of Interest

The authors declare that there is no conflict of interest.

## 10. Source of Funding

None.

## References

- Jacobs R, Lambrichts I, Liang X, Martens W, Mraiwa N, Adriaenssens P, et al. Neurovascularization of the anterior jaw bones revisited using high resolution magnetic resonance imaging. *Oral Surg Oral Med Oral Pathol Oral Radiol Endod.* 2007;103(5):683–93. Available from: <https://doi.org/10.1016/j.tripleo.2006.11.014>. doi:10.1016/j.tripleo.2006.11.014.

2. White SC, Pharaoh MG. Oral Radiography. Normal Radiographic Anatomy. Principles and Interpretation, 5th Edn. St. Louis: C. V. Mosby Company; 2004. p. 174.
3. Jacob S, Zelano B, Gungor A, Abbott D, Naclerio R, McClintock MK, et al. Location and Gross Morphology of Nasopalatine Duct in Human Adults. *Arch Otolaryngol Head Neck Surg.* 2000;126(6):741–8. doi:10.1001/archotol.126.6.741.
4. Radlanski RJ, Emmerich S, Renz H. Prenatal morphogenesis of the human incisive canal. *Anat Embryol.* 2004;208(4):265–71. doi:10.1007/s00429-004-0389-y.
5. Noyes HJ. Naso-palatine duct and Jacobson's organ in newborns infants. *J Dent Res.* 1935;15:155–6.
6. Whitmore I. Terminologia Anatomica: New terminology for the new anatomist. *Anatomical Rec.* 1999;257(2):50–3.
7. Douglass CW, Shih A, Ostry L. Will there be a need for complete dentures in the United States in 2020? *J Prosthet Dent.* 2002;87(1):5–8. doi:10.1067/mpr.2002.121203.
8. Schwartz-Arad D, Levin L, Ashkenazi M. Treatment options of untreatable traumatized anterior maxillary teeth for future use of dental implantation. *Implant Dent.* 2004;13(1):11–9.
9. Brügger OE, Bornstein MM, Kuchler U, Janner SF, Chappuis V, Buser D, et al. Implant therapy in a surgical specialty clinic: an analysis of patients, indications, surgical procedures, risk factors, and early failures. *Int J Oral Maxillofac Implants.* 2014;30(1):151–60. doi:10.11607/jomi.3769.
10. CE M. Contemporary Implant Dentistry. 3rd Edn. Mosby, St. Louis; 2007. p. 769.
11. Goodacre CJ, Bernal G, Rungcharassaeng K, Kan JY. Clinical complications with implants and implant prostheses. *J Prosthet Dent.* 2003;90(2):121–32. doi:10.1016/S0022-3913(03)00212-9.
12. Naert I, Koutsikakis G, Duyck J, Quirynen M, Jacobs R, Steenberghe DV, et al. Biologic outcome of implant-supported restorations in the treatment of partial edentulism. Part 1: A longitudinal clinical evaluation. *Clin Oral Implants Res.* 2002;13(4):381–9. doi:10.1034/j.1600-0501.2002.130406.x.
13. Mraiwa N, Jacobs R, Cleynenbreugel JV, Sanderink G, Schutyser F, Suetens P, et al. The nasopalatine canal revisited using 2D and 3D CT imaging. *Dentomaxillofac Radiol.* 2004;33(6):396–402. doi:10.1259/dmfr/53801969.
14. Song WC, Jo DI, Lee JY, Kim JN, Hur MS, Hu KS, et al. Microanatomy of the incisive canal using three-dimensional reconstruction of microCT images: An ex vivo study. *Oral Surg Oral Med Oral Pathol Oral Radiol Endod.* 2009;108(4):583–90. doi:10.1016/j.tripleo.2009.06.036.
15. Liang X, Jacobs R, Martens W, Hu YQ, Adriaensens P, Quirynen M, et al. Macro- and micro-anatomical, histological and computed tomography scan characterization of the nasopalatine canal. *J Clin Periodontol.* 2009;36(7):598–603. doi:10.1111/j.1600-051X.2009.01429.x.
16. Mardinger O, Namani-Sadan N, Chaushu G, Schwartz-Arad D. Morphologic changes of the nasopalatine canal related to dental implantation: a radiologic study in different degrees of absorbed maxillae. *J Periodontol.* 2008;79:1659–62. doi:10.1902/jop.2008.080043.
17. Bornstein MM, Balsiger R, Sendi P, Arx T. Morphology of the nasopalatine canal and dental implant surgery: a radiographic analysis of 100 consecutive patients using limited cone-beam computed tomography. *Clin Oral Impl Res.* 2011;22(3):295–301. doi:10.1111/j.1600-0501.2010.02010.x.
18. Safi Y, Moshfeghi M, Rahimian S, Kheirkhahi M, and MEM. Assessment of Nasopalatine Canal Anatomic Variations Using Cone Beam Computed Tomography in a Group of Iranian Population. *Iran J Radiol.* 2017;14(1):e13480. doi:10.5812/iranjradiol.37028.
19. Kraut RA, Boyden DK. Location of incisive canal in relation to central incisor implants. *Implant Dent.* 1998;7(3):221–5. doi:10.1097/00008505-199807030-00010.
20. Thakur AR, Burde K, Guttal K, Naikmasur VG. Anatomy and morphology of the nasopalatine canal using cone-beam computed tomography. *Imaging Sci Dent.* 2013;43(4):273–81. doi:10.5624/isd.2013.43.4.273.
21. Sicher H. Anatomy and oral pathology. *Oral Surg Oral Med Oral Pathol Oral Radiol Endod.* 1962;15:1264–9. doi:10.1016/0030-4220(62)90163-9.
22. Fukuda M, Matsunaga S, Odaka K, Oomine Y, Kasahara M, Yamamoto M, et al. Three-dimensional analysis of incisive canals in human dentulous and edentulous maxillary bones. *Int J Implant Dent.* 2015;1(1):12. doi:10.1186/s40729-015-0012-4.
23. Khojastepour L, Haghnegahdar A, Keshtkar M. Morphology and Dimensions of Nasopalatine Canal: a Radiographic Analysis Using Cone Beam Computed Tomography. *J Dent.* 2017;18(4):244–50.
24. Cheng S, Cheng J, Huang W. Preliminary study of anatomic relation among nasopalatine duct, central incisor root and floor of nasal cavity with X-ray measurement. *Chin J Stomatol.* 1997;32(3):149–51.
25. Barkin S, Sandor GK, Keller A, Caminiti MF, Clokie C. The nasopalatine canal: An anatomic study and effects on dental implant placement. *J Dent Res.* 2002;81:437.
26. Chatriyanuyoke P, Lu CI, Suzuki Y, Lozada J, Rungcharassaeng K, Kan J, et al. Nasopalatine Canal Position Relative to the Maxillary Central Incisors : A Cone Beam Computed Tomography Assessment. *J Oral Implantol.* 2012;38(6):713–7. doi:10.1563/AAID-JOI-D-10-00106.

## Author biography

**Heena Sonawane**, Assistant Professor

**Kaustubh Sansare**, Associate Professor

**Freny Karjodkar**, Professor and Head

**Cite this article:** Sonawane H, Sansare K, Karjodkar F. Incisive canal: Variations on cone beam computed tomography and its impact on dental implant planning. *IP Ann Prosthodont Restor Dent* 2022;8(1):18-25.