

Content available at: <https://www.ipinnovative.com/open-access-journals>

IP Annals of Prosthodontics and Restorative Dentistry

Journal homepage: <https://www.aprd.in/>

Review Article

Digital dental implantology – The cutting edge implantology: A comprehensive review

Arpit Sikri^{1,*}, Jyotsana Sikri²

¹Dept. of Prosthodontics, Crown & Bridge and Oral Implantology, Bhojia Dental College and Hospital, Baddi, Himachal Pradesh, India

²Dept. of Conservative Dentistry & Endodontics, Bhojia Dental College and Hospital, Baddi, Himachal Pradesh, India



ARTICLE INFO

Article history:

Received 27-01-2022

Accepted 29-01-2022

Available online 16-03-2022

Keywords:

CAD

CAM

CBCT

Dental

Dental implants

Digital

Implantology

Scanners

Workflow

ABSTRACT

Dentistry, in particular, the implant dentistry has always been through various leaps and bounds during the last decade. With the advent of various technologies in dentistry, one such cutting edge technology is the digital dental implantology. The digitization in the practice of dentistry; particularly, the dental implantology, is running swiftly and has tremendously helped in shaping the future of dentistry. Digital dentistry involves various digital tools/modalities/sources namely the CBCT (Cone Beam Computed Tomography), intraoral & extraoral (laboratory) scanners, facial scanners with the photogrammetry, CAD (Computer-aided design), CAM (Computer-aided manufacturing) and RP (Rapid prototyping) or 3DP (3D Printing), have influenced the implant practice in a big way. A very important component or heart of the digital implantology is termed as the digital workflow and is readily accessible in the implant practice. Such workflow has tremendously helped the dental practitioner to treat the patients using a stepwise approach at various stages i.e. diagnosis, scanning, designing, and final fabrication of the prosthesis. It has a plethora of advantages i.e. precise planning of the implant restorations associated with reduced complications and thereby ensuring long-term success of the dental implants. A number of issues to be importantly taken into account involve minor inaccuracies associated with the various digital tools, deviations i.e. linear and angular deviations between the planned and the placed implant position, and a steep learning curve, may lead to unsatisfactory results, if neglected. Digital workflows can be successfully integrated into the routine dental practices. This comprehensive review article portrays about the digital modalities & their meticulous usage in the practice of implantology for better accuracy, patient safety, and predictability associated with reduction in the errors and complications in implant practice.

This is an Open Access (OA) journal, and articles are distributed under the terms of the [Creative Commons Attribution-NonCommercial-ShareAlike 4.0 License](https://creativecommons.org/licenses/by-nc-sa/4.0/), which allows others to remix, tweak, and build upon the work non-commercially, as long as appropriate credit is given and the new creations are licensed under the identical terms.

For reprints contact: reprint@ipinnovative.com

1. Introduction

The incorporation of digital techniques and innovations is relatively a new dimension in the practice of dentistry. There has been a significant upgradation of the practice of digital dentistry over the years.¹ This has fascinated the dental professionals to actively plunge into the digital dental implant practice. Dr Patrick J. Hanratty commonly known as the "Father of CAD/CAM" did extensive research

in the field of design. In 1980s, Dr. Francois Duret did a lot of research in the field of optical impressions, which subsequently gave birth to the CAD CAM in the practice of dentistry. Mörmann et al. in 1989, Preston in 1990s, and Andersson et al. in 1996, were quite instrumental and well known for their research in the field of digital dentistry.²

Since its inception, the practice of digital dentistry was limited to inlays and onlays, but with the successful incorporation of the novel and recent innovations, the whole landscape of dentistry was changed. This resulted in

* Corresponding author.

E-mail address: arpitsikri@gmail.com (A. Sikri).

implementation of the novel approach of digitization in the field of dentistry. Out of this, digital dental implantology fascinated the dental clinicians in a big way.³

Over the years, there has been a paradigm shift from the conventional 2D to the 3D approaches. Such approaches have set a benchmark as a diagnostic modality. The use of CBCT has totally proven it as a cutting edge in diagnosis and treatment planning in dentistry. Meticulous planning and placement of the dental implant is essential for the overall health of the oral tissues.⁴ The use of navigation in implantology using surgical guides has helped the clinicians to precisely plan and place the dental implant. The combination of all the digital modalities or the digital workflow in implantology i.e. CBCT, scanners and CAD-CAM, have helped both the dental professionals as well as the laboratory personnel, working as a team, to successfully rehabilitate the patient with predictable outcomes.⁵

Such a remarkable change in the field of implantology is associated with a number of benefits. This includes an effective communication between the dental professional, the patient and the laboratory technician. Such communication also ensures better patient motivation and acceptance. The elimination of a couple of steps helps to save a lot of time.⁶ The inclusion of CAD-CAM system associated with several digital tools has broadened the horizon both in dental clinics as well as in dental laboratories. Meticulous planning using surgical guides have always ensured faster and a more predictable treatment outcome.⁷ Digital technologies in contrast to the conventional ones provide proper and precise recording of the details. This has resulted in better fit of the restorations, thereby improving the Oral Health-Related Quality of Life (OHRQoL) along with a positive impact on the patient. Reduction in the manual errors; in particular, the distortion issues associated with the conventional impressions and storage of data by avoiding the need of casts are the other benefits of digital techniques.⁸

Apart from the plethora of benefits associated with the digital implantology, a few issues or barriers can also be recognized. This includes positively accepting the change from the analog process or the conventional techniques to the digital techniques or modalities. The professionals are expected to gain good knowledge, proper awareness and upgrade themselves with the recent trends in digital practices, since, the learning curve is steep.⁹ There can be issues associated with the inaccuracies of the intraoral scanners, when dealing with the long span or full mouth dental implant rehabilitation cases. The same issue arises in the completely edentulous situation, as it is nearly impossible to record the resiliency of the underlying soft tissues.¹⁰ Apart from this, there needs to be a well-equipped and a proper lab support in the practice of digital implantology. Ignorance to any deviations between the proposed and the placed implant position may lead

to misfit of the implant components resulting in further complications i.e. both mechanical and biological. A proper dry field is needed to accurately capture the details through the intraoral scanner. Incorporation of saliva, blood and gingival fluids may obscure the area to be captured resulting in incorrect impressions.¹¹ Thus, a dental professional needs to have a conceptual understanding of the procedures to be undertaken along with the ability to use various digital tools for achieving the ultimate success, both in surgical as well as in prosthetic phase of dental implantology.

2. Discussion

Tooth loss may occur due to a couple of reasons mainly the caries and the periodontal disease, leaving a patient handicapped. Prosthetic rehabilitation of the missing tooth/teeth in such patients is important to revive them from this handicap.¹² Out of all the treatment options, dental implants, also known as the 3rd dentition has always been the modality of choice for prosthetic rehabilitation amongst the dental clinicians. In addition to this, it has been the prosthetic treatment modality of choice amongst the patients due to increased awareness, life expectancy, better treatment protocols, and improvement in the OHRQoL.¹³ Over the years, dental implants have overruled the other prosthetic treatment options i.e. removable and fixed prosthodontics, making it an emerging trend in the dental practice.¹⁴

The incorporation of digitization in the practice of dentistry has proved to be a hallmark in the field of dental implantology. The annexation of digital dentistry along with the practice of dental implantology gave birth to the concept of digital implantology or digital implant dentistry.¹⁵ Digital dental implantology is mainly based on 3 major components namely scanning, designing and milling. A stepwise approach commonly used in the practice of dental implantology is termed as implant prosthetic digital workflow. This workflow forms the heart of the digital implantology and is commonly conducted by a digital resource in every phase of the diagnosis, planning, & treatment. The stepwise approach of digital workflows is a tabulated format that should be followed during prosthetic rehabilitation of the patient. (Figure 1)

The workflows in dental implantology can be categorized as analog, partial digital and complete digital workflow. Over the years, there has been a paradigm shift from the conventional analog to the digital workflows in implantology. (Figure 2)

Digital workflow in implant dentistry is constantly and swiftly evolving, resulting in an increased accuracy of work, better predictability, treatment outcomes, and elimination of a number of conventional steps in the routine dental practices.¹⁶ Digital workflows require a steep and a gradual learning curve along with an understanding of the associated complications i.e. deviations in the planned and the final implant position and inaccuracies related to the intraoral

scanning procedure.¹⁷

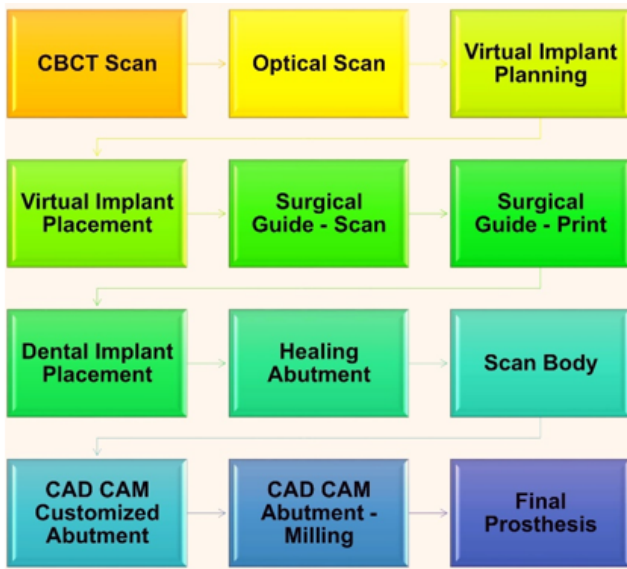


Fig. 1: Digital Workflow in Dental Implantology

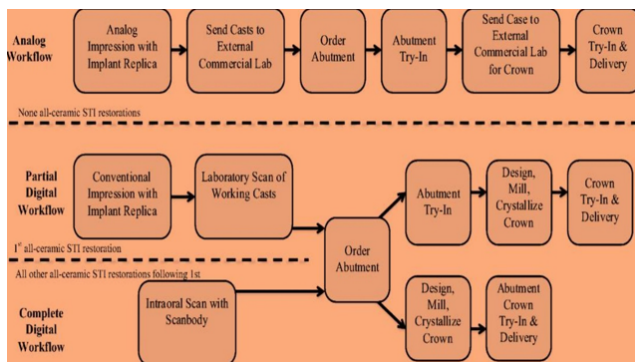


Fig. 2: Types of Digital Workflow

In the earlier years, the radiographs gave a 2 dimensional picture of a 3 dimensional object. Over the period of time, the incorporation of digital modalities in diagnosis i.e. 3D CBCT proved to be a benchmark in the practice of dental implantology. Previously, CT (Computed Tomography) had been the modality of choice for diagnostic imaging in medical practice. Since, it was associated with a higher radiation exposure; its use in the practice of dentistry was discouraged.¹⁸ Conversely, CBCT became popular as a diagnostic modality due to its ability to capture the 3D structures with a smaller scan time and reduced radiation dosage. As per the literature, CBCT had the ability to assess the parameters of bone with better accuracy along with the associated vital structures.¹⁹ Nowadays, CBCT is commonly used as an invaluable tool while evaluating & rehabilitating the patients with dental implants (Figure 3). CBCT as contrasted to the MRI (Magnetic Resonance

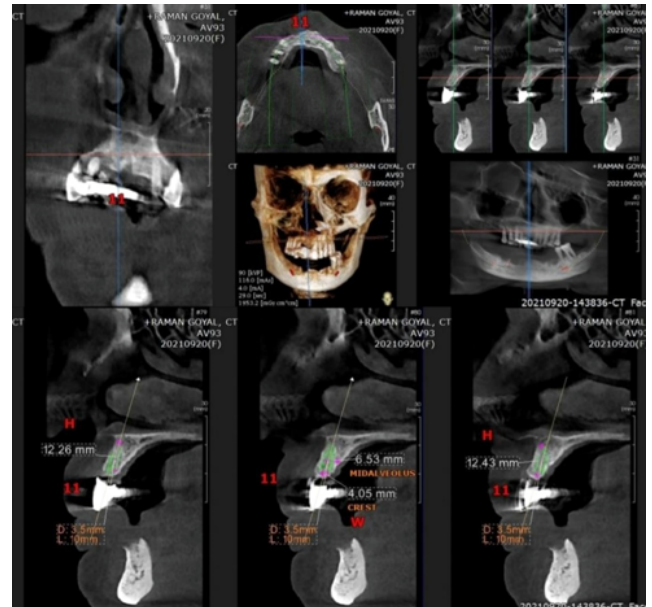


Fig. 3: Cone Beam Computed Tomography (CBCT)

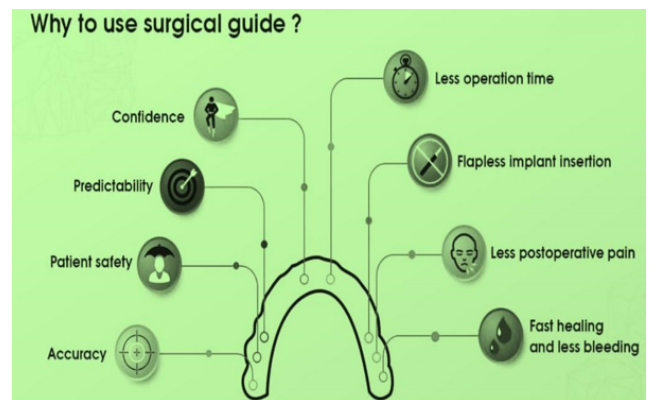


Fig. 4: Surgical Guides (Templates) – Applications

Imaging) is commonly discussed in the literature reviews. MRI in terms of soft tissue imaging has proved to be a road beyond the CBCT. A broad horizon of CBCT includes scanning the dental impressions as well as the models apart from being the diagnostic modality of choice. One of the common as well as a major limitation of CBCT is the production of the metal artefacts. Moreover, the surface texture details associated with the CBCT is still questionable.²⁰

Pre-operative intraoral scanning is the 1st step using the principles of digital technology in implant practice. This can be possible with the successful inclusion of the intraoral scanner (optical scanner) along with the extraoral scanner (lab scanner). Facial scanners are a new addition to both the above scanner types. These scanners; particularly, the intraoral scanners help to capture the oral cavity, with the best accuracy and meticulous planning for the implant

surgery, and a predictable implant prosthetic restorative outcome, avoiding long-term complications i.e. mechanical & biological.²⁷

A plethora of methods can be used to evaluate the dental implant osseointegration. These may include the invasive and the non-invasive approaches. The inclusion of digital approaches or the osseointegration monitors have proved their efficacy as a non-invasive measure to test the stability of the dental implant for monitoring the osseointegration. This further helps to diagnose the suitability of the dental implant for the prosthetic restoration and thereby aiding in the post restorative monitoring.²⁸

Healing abutments are generally placed to ensure a better emergence/esthetic profile. This is followed by impression using scanners in implantology commonly known as an optical/virtual (digital) impression. A very important component of impression i.e. implant scan body commonly known as CAD CAM implant impression coping i.e. a true representation of the position and orientation of the respective dental implant, analog or abutment in CAD CAM scanning procedures, is generally used during the impression procedures. Generally, the scan bodies are available with the major brands/manufacturers in implantology.²⁸ These scan abutments provide a proper workflow in capturing information related to the provisionalization, bite registration etc. both in dentulous as well as edentulous cases. The less time consuming approach along with better patient experience and comfortability makes it the impression of choice for the patients. (Figure 5)

The impressions in full mouth implant rehabilitation is an issue. In multiple implants, the digital impressions may be associated with linear or angular deviations unlike the single implants, where the impressions can be easily captured. In full mouth or multiple implant impressions, an amalgamation of open mouth impression technique (gold standard in conventional implant impressions) using scannable elastomers along with lab/extraoral scanners, will help to achieve the best possible results.²⁹

The digital impressions in implant dentistry have successfully superseded the conventional impressions in a number of ways. (Figure 6)

After successfully capturing the details through digital impressions, they can be then transferred to the dental laboratory through secured web portals. This is followed by the designing of the abutment commonly known as the customized abutment for optimal form and tissue support & final prosthesis with the help of CAD approach.³⁰ The abutment & the final prosthesis can be finally machined with the help of subtractive milling i.e. CAM or additive manufacturing i.e. RP or Rapid Additive Manufacturing (RAM) approach.³¹ This digital laboratory workflow in contrast to the conventional laboratory workflow ensures reduction in the number of steps leading to more efficient and less time-consuming approach in fabrication of implant

prosthesis.

The implant restorations are transferred from the laboratory to the clinician followed by the final placement of the prosthesis. The successful incorporation of the digital workflows have totally changed the landscape of the dental implantology.³²

Occlusion in implantology is of paramount importance. The concept of implant protective occlusion is a common practice in the conventional implantology. Subsequently, with the advent of technologies such as Tek Scan (T Scan) i.e. computer aided occlusion or digital occlusion, the concept has totally changed in implantology. Occlusal analysis sensors or the T scans have the ability to successfully differentiate between the high-pressure areas and low-pressure areas, thereby improving the overall success rate of the implant prosthesis.³³

Keeping in view the plethora of applications and a broad horizon of the various digital modalities i.e. the digital workflows in the field of implantology,³⁴ it can be rightly said that the digital dental implantology has totally changed the whole landscape of dental implantology.³⁵ (Figure 7)

3. Conclusion

Dental implants have always proved to be the prosthetic treatment modality of choice for the clinicians as well as the patients, a subject of research for the avid researchers, a learning tool for the budding dental surgeons, and the dental students. Over the years, there has been a paradigm shift from the conventional dental implantology to the digital dental implantology. The successful inclusion of the digitization into the practice of dental implantology has proved to a promising innovation and can be well related to the digital workflows. Such workflows can be routinely integrated and have proved to be a reality in the dental practice; particularly, the implantology. Digital implantology ensures accuracy, safety & comfort of the patient, treatment predictability, elimination of steps thereby saving a lot of time, and ultimately a more predictable outcome for the final success of the implant treatment. The advantages of the digital modalities definitely supersede the issues/barriers associated with the adoption of these modalities. Minor inaccuracies are inevitable and should always be taken into consideration. Although, the learning curve is steep and gradual, but still the dental professionals are expected to be skilful, proficient, and properly updated with good knowledge to treat the patients meticulously. The cutting edge implantology or the digital dental implantology proves to be a ubiquitous tool rather a dream come true for rehabilitating the patients in the best and the most natural way in the routine clinical practices.

4. Conflict of Interest

The authors declare that there is no conflict of interest.


5. Source of Funding


None.

References

- Al-Abdullah K, Zandparsa R, Finkelman M. An in vitro comparison of the accuracy of implant impressions with coded healing abutments and different implant angulations. *J Prosthetic Dent.* 2013;110(2):90–100. doi:10.1016/S0022-3913(13)60346-7.
- Bacchi A, Consani RL, Mesquita MF, Santos MBD. Effect of framework material and vertical misfit on stress distribution in implant-supported partial prosthesis under load application: 3-D finite element analysis. *Acta Odontol Scand.* 2013;71(5):1243–9. doi:10.3109/00016357.2012.757644.
- Burgner J, Simpson A, Fitzpatrick JM. A study on the theoretical and practical accuracy of conoscopic holography-based surface measurements: toward image registration in minimally invasive surgery. *Int J Med Robotics Computer Assist Surg.* 2013;9(2):190–203.
- Cappare P, Sannino G, Minoli M, Montemezzi P, Ferrini F. Conventional versus digital impressions for full arch screw-retained maxillary rehabilitations: A randomized clinical trial. *Int J Environ Res Public Health.* 2019;16(5):829. doi:10.3390/ijerph16050829.
- Colombo M, Mangano C, Mijiritsky E, Krebs M, Hauschild U, Fortin T, et al. Clinical applications and effectiveness of guided implant surgery: A critical review based on randomized controlled trials. *BMC Oral Health.* 2017;17(1):150. doi:10.1186/s12903-017-0441-y.
- Dounis GS, Ziebert GJ, Dounis KS. A comparison of impression materials for complete-arch fixed partial dentures. *J Prosthet Dent.* 1991;65(2):165–9. doi:10.1016/0022-3913(91)90157-r.
- Eliasson A, Ortorp A. The accuracy of an implant impression technique using digitally coded healing abutments. *Clin Implant Dent Related Res.* 2012;14(1):30–8.
- Ferrini F, Cappare P, Vinci R, Gherlone EF, Sannino G. Digital versus traditional workflow for posterior maxillary rehabilitations supported by one straight and one tilted implant: A 3-year prospective comparative study. *Bio Med Res Int.* 2018;p. 4149107. doi:10.1155/2018/4149107.
- Garg AK. The Atlantis Components Abutment: simplifying the tooth implant procedure. *Dent Implantol Update.* 2002;13(9):65–70.
- Gigandet M, Bigolin G, Faoro F. Implants with Original and Non-Original Abutment Connections. *Clin Implant Dent Related Res.* 2014;16(2):303–11.
- Hamilton A, Judge RB, Palamara JE. Evaluation of the fit of CAD/CAM abutments. *Int J Prosthodont.* 2013;26(4):370–80. doi:10.11607/ijp.3501.
- Holst S, Persson A, & wickmann M. Digitizing implant position locators on master casts: comparison of a noncontact scanner and a contact-probe scanner. *Int J Oral Maxillofac Implants.* 2012;27(1):29–35.
- Howell KJ, Mcglumphy EA, Drago C. Comparison of the accuracy of Biomet 3i Encode Robocast Technology and conventional implant impression techniques. *Int J Oral Maxillofac Implants.* 2013;28:228–40.
- Jemt T, Hjalmarsson L. In vitro measurements of precision of fit of implant-supported frameworks. A comparison between "virtual" and "physical" assessments of fit using two different techniques of measurements. *Clin Implant Dent Relat Res.* 2012;14(1):175–82. doi:10.1111/j.1708-8208.2011.00416.x.
- Joda T, Ferrari M, Gallucci GO, Wittneben JG, Bragger U. Digital technology in fixed implant prosthodontics. *Periodontology.* 2000;73(1):178–92. doi:10.1111/prd.12164.
- Kapos T, Evans C. CAD/CAM technology for implant abutments, crowns, and superstructures. *Int J Oral Maxillofac Implants.* 2014;29:117–36. doi:10.11607/jomi.2014suppl.g2.3.
- Kerstein RB, Radke J. A comparison of fabrication precision and mechanical reliability of 2 zirconia implant abutments. *Int J Oral Maxillofac Implants.* 2008;23(6):1029–36.
- Kim S, Nicholls JI, Han CH, Lee KW. Displacement of implant components from impressions to definitive casts. *Int J Oral Maxillofac Implants.* 2006;21(5):747–55.
- Lewis S, Beumer J, Hornburg W. The "UCLA" abutment. *Int J Oral Maxillofac Implants.* 1988;3(3):183–9.
- Lewis S, Avera S, Engleman M. The restoration of improperly inclined osseointegrated implants. *Int J Oral Maxillofac Implants.* 1989;4:147–52.
- Ma T, Nicholls JI, Rubenstein JE. Tolerance measurements of various implant components. *Int J Oral Maxillofac Implants.* 1997;12(3):371–5.
- Mahn DH, Prestipino T. CAD/CAM implant abutments using coded healing abutments: a detailed description of the restorative process. *Compend Contin Educ Dent.* 2013;34(8):612–5.
- Malaguti G, Denti L, Bassoli E. Dimensional tolerances and assembly accuracy of dental implants and machined versus cast-on abutments. *Clin Implant Dent Related Res.* 2011;13(2):134–40. doi:10.1111/j.1708-8208.2009.00189.x.
- Michalakis KX, Asar NV, Kapsampeli V, Magkavali-Trikka P, Pissiotis AL, Hirayama H, et al. Delayed linear dimensional changes of five high strength gypsum products used for the fabrication of definitive casts. *J Prosthet Dent.* 2012;108(3):189–95. doi:10.1016/S0022-3913(12)60146-2.
- Nkenke E, Eitner S, Radespiel-Tröger M, Vairaktaris E, Neukam FW, Fenner M, et al. Patient-centred outcomes comparing transmucosal implant placement with an open approach in the maxilla: a prospective, non-randomized pilot study. *Clin Oral Implants Res.* 2007;18(2):197–203. doi:10.1111/j.1600-0501.2006.01335.x.
- Persson AS, Andersson M, Oden A. Computer aided analysis of digitized dental stone replicas by dental CAD/CAM technology. *Dent Mater.* 2008;24(8):1123–30. doi:10.1016/j.dental.2008.01.008.
- Persson AS, Oden A, Andersson M. Digitization of simulated clinical dental impressions: virtual three-dimensional analysis of exactness. *Dent Mater.* 2009;25(7):929–36. doi:10.1016/j.dental.2009.01.100.
- Priest G. Virtual-designed and computer-milled implant abutments. *J Oral Maxillofac Surg.* 2005;63(9 Suppl 2):22–32. doi:10.1016/j.joms.2005.05.158.
- Róth I, Czigola A, Joós-Kovács GL, Dalos M, Hermann P, Borbély J, et al. Learning curve of digital intraoral scanning - an in vivo study. *BMC Oral Health.* 2020;20(1):287. doi:10.1186/s12903-020-01278-1.
- Schabel BJ, Jr JAM, Franchi L, Baccetti T. Q-sort assessment vs visual analog scale in the evaluation of smile esthetics. *Am J Orthod Dentofacial Orthop.* 2009;135(4):S61–71. doi:10.1016/j.ajodo.2007.08.019.
- Schepke U, Meijer HJ, Kerdijk W, Cune MS. Digital versus analog complete-arch impressions for single-unit premolar implant crowns: Operating time and patient preference. *J Prosth Dent.* 2015;114(3):403–6. doi:10.1016/j.prosdent.2015.04.003.
- Torrance GW, Feeny D, Furlong W. Visual analog scales: do they have a role in the measurement of preferences for health states? *Med Decis Making.* 2001;21(4):329–34. doi:10.1177/0272989X0102100408.
- Van Assche N, Vercruyssen M, Coucke W, Teughels W, Jacobs R, Quirynen M, et al. Accuracy of computer-aided implant placement. *Clin Oral Implants Res.* 2012;23(6):112–23. doi:10.1111/j.1600-0501.2012.02552.x.
- Wismeijer D, Mans R, Van Genuchten M, Reijers HA. Patients' preferences when comparing analogue implant impressions using a polyether impression material versus digital impressions (Intraoral Scan) of dental implants. *Clin Oral Implants Res.* 2014;25(10):1113–8. doi:10.1111/clr.12234.
- Youk SY, Lee JH, Park JM, Heo SJ, Roh HK, Park EJ, et al. A survey of the satisfaction of patients who have undergone implant surgery with and without employing a computer-guided implant surgical template. *J Adv Prosthodont.* 2014;6(5):395–405. doi:10.4047/jap.2014.6.5.395.

Author biography

Arpit Sikri, Associate Professor and Post Graduate Teacher
 <https://orcid.org/search?searchQuery=0000-0002-6273-8882>

Jyotsana Sikri, Associate Professor and Post Graduate Teacher
 <https://orcid.org/0000-0002-0911-1829>

Cite this article: Sikri A, Sikri J. Digital dental implantology – The cutting edge implantology: A comprehensive review. *IP Ann Prosthodont Restor Dent* 2022;8(1):3-9.