

Content available at: <https://www.ipinnovative.com/open-access-journals>

IP Annals of Prosthodontics and Restorative Dentistry

Journal homepage: <https://www.aprd.in/>

Case Report

Pragmatic approach to rehabilitate maxillary teeth in aesthetic zone using resin bonded FDP- A case report

Harsh Rathee¹, Saurav Kumar^{1,*}, Parag Dua¹

¹Dept. of Dental Surgery and Oral Health Science, Armed Forces Medical College, Pune, Maharashtra, India



ARTICLE INFO

Article history:

Received 26-10-2021

Accepted 17-11-2021

Available online 10-12-2021

Keywords:

Aesthetic zone

RBFDP

Zirconia dioxide

ABSTRACT

Resin bonded fixed dental prosthesis offers most conservative and cost-effective option with missing teeth in aesthetic zone specially when an implant prosthesis is not indicated. This case report describes a treatment option for the replacement of a missing maxillary central incisor using a double-retainer resin-bonded fixed partial denture (RBFDP), fabricated from zirconium dioxide (ZrO₂) ceramic. No clinical complications were observed at follow-up examination after placement of the prosthesis. Satisfactory functional and aesthetic results were achieved. A treatment modality using a ZrO₂ ceramic RBFDP is an alternative for single anterior tooth replacement.

This is an Open Access (OA) journal, and articles are distributed under the terms of the [Creative Commons Attribution-NonCommercial-ShareAlike 4.0 License](https://creativecommons.org/licenses/by-nc-sa/4.0/), which allows others to remix, tweak, and build upon the work non-commercially, as long as appropriate credit is given and the new creations are licensed under the identical terms.

For reprints contact: reprint@ipinnovative.com

1. Introduction

Resin bonded fixed dental prosthesis offers most conservative and cost-effective option to a patient, with missing teeth in aesthetic zone specially when an implant prosthesis is not indicated. Recent advances in material and bonding technologies have increased the clinical longevity and success of these restorations.¹ This article describes an approach to rehabilitate a case of missing maxillary central incisor using Zirconia resin bonded fixed dental prosthesis (RBFDP). Replacing missing single teeth in the anterior region is a challenge which requires a comprehensive treatment plan. Zirconia based all ceramic resin bonded fixed partial denture is a suitable treatment modality for such rehabilitation. Along with minimal tooth structure removal, it offers a viable option with an acceptable result in terms of aesthetic and strength.

2. Case Report

A 27-year-old female patient reported with a chief complaint of missing maxillary right central incisor, which was extracted following trauma approximately one year back (Figures 1 and 2). Various treatment options were given to the patient from full coverage 3 unit all ceramic FDP to implant retained prosthesis. As there was deficient bone and patient was unwilling for any augmentation surgery. The rehabilitation using dental implant was ruled out and was planned for minimal invasive rehabilitation treatment option of using a resin bonded FDP (fixed dental prosthesis).

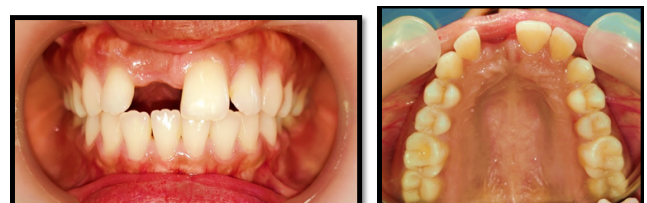

Fig. 1: Pre-operative- Intraoral view

* Corresponding author.

E-mail address: doc.saurav.k@gmail.com (S. Kumar).

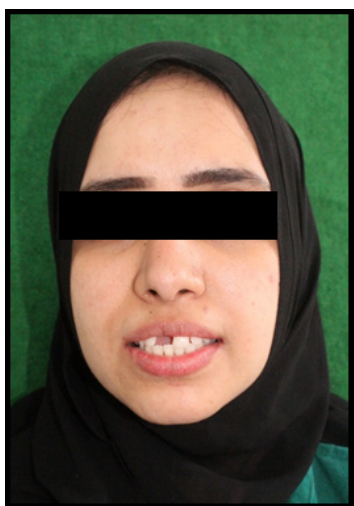

Fig. 2: Pre-operative- Extraoral view

Diagnostic impressions and diagnostic mounting was done using facebow record. The tooth preparation comprised of a minimal lingual veneer preparation, a fine cervical supra-gingival chamfer, an incisal finishing shoulder and a proximal box (Figure 3). The preparation was done using a round end taper diamond bur on both abutment teeth i.e., maxillary left central incisor and maxillary right lateral incisors. The other areas of the teeth were superficially prepared using a small flame shaped bur to restrict the preparation entirely on enamel, to achieve optimal bonding.² The impressions were made using a two stage putty wash impression in polyvinylsiloxane impression material (GC Flexceed, India). The cast was poured using Dental Stone Type IV (Ultrarock, Kalabhai) and this cast was subsequently optically scanned using extra oral scanner (Ceramill Map, Amann Girbachh). Designing of the prosthesis was done in an Exocad software and monolithic zirconia (Ceramill Zolid FX) prosthesis was milled with the CAD-CAM system (Figures 4, 5, 6 and 7).

The bonding surface of abutments were etched using 37.5% orthophosphoric acid for 30 seconds, rinsed and air dried. The bonding surface of the zirconia cantilever prosthesis was air-abraded with 110 micron alumina particles at one bar pressure; followed by application of a phosphate monomer based primer (Monobond Plus, Ivoclar Vivadent). The resin luting agent (Multilink N, Ivoclar Vivadent) was mixed as per manufacturer's instructions and applied onto the bonding surfaces of the prosthesis. The prosthesis was then seated on to the abutments, positioning it accurately flushing with the margins. It was held in the position and light cured for 5 seconds and excess was removed. Subsequent to which final light curing was done till the material achieved a complete set. The occlusion was verified in centric and eccentric mandibular positions and it was made sure that there were no interferences. Post-insertion instructions were given to patient (Figures 7, 8

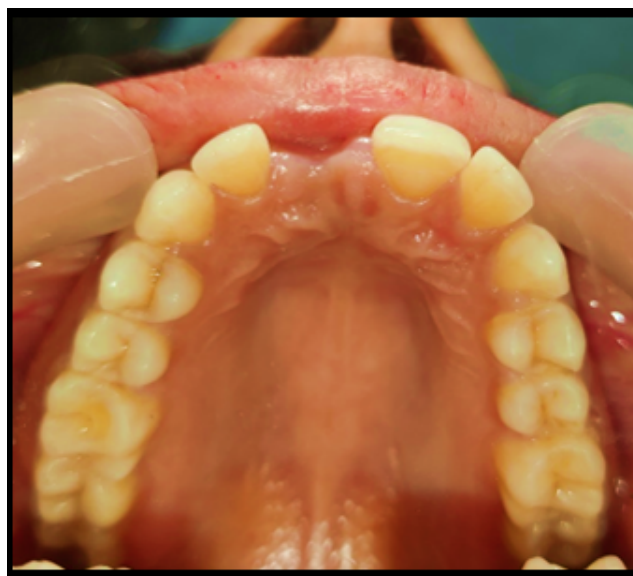

Fig. 3: Tooth preparation

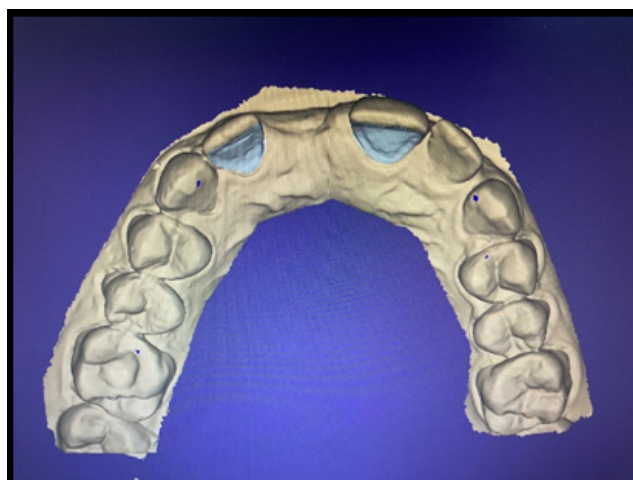


Fig. 4: Assessing margins of restorations

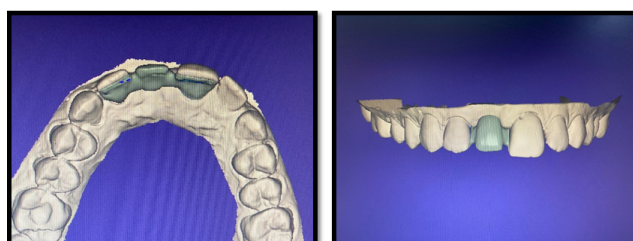


Fig. 5: Designing the restoration

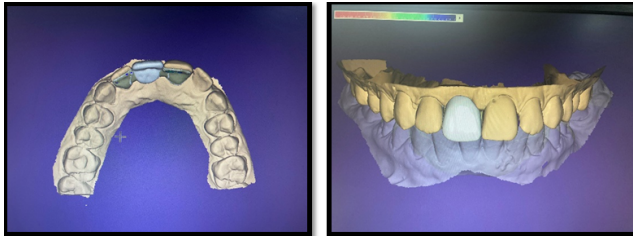


Fig. 6: Final designed prosthesis



Fig. 7: Final prosthesis

and 9). The patient was recalled at 1st, 3rd and 6th month post cementation to evaluate the marginal fit, aesthetic changes and stability of the prosthesis. No functional or aesthetic problems have been reported by the patient till date.

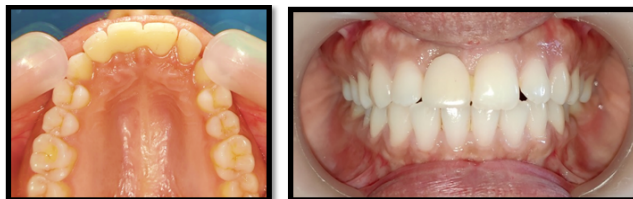

Fig. 8: Final Prosthesis In-Situ- Intra-oral view.

3. Discussion

Replacement of missing teeth in aesthetic zone with conventional fixed partial denture usually involves the tooth preparation of all surfaces of abutments. However, as the existing surfaces of the abutment teeth were free of any caries, aesthetic anomaly. The preservation of existing enamel facial surface was considered. Also, as the



Fig. 9: Post-operative- Extra-oral view.

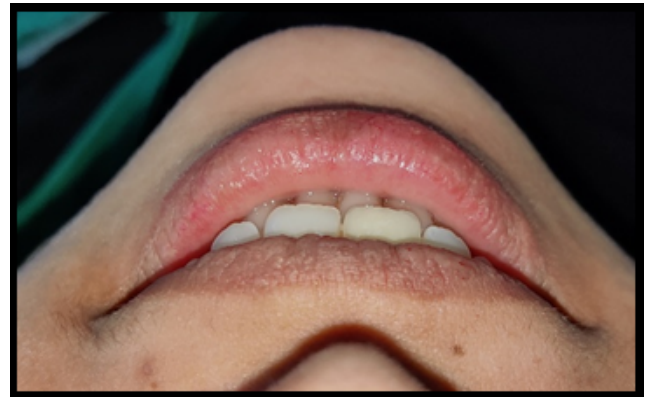

Fig. 10: Bird's eye view Post treatment

abutments were vital and non-mobile and free from caries and restorations with sufficient enamel surface for bonding, they were considered as an ideal abutments. Deficient amount of bone and unwillingness for augmentative surgical procedures were factors that precluded the use of implant prostheses in this case.

With the advancement in all ceramic materials, high strength ceramic materials like zirconia and with the use of dental CAD/CAM technology, zirconia all ceramic frameworks for fixed prostheses can be machined with improved accuracy. The combination of newer bonding agents specially phosphate monomers like 10-MDP, with Zirconia resin bonded FDP provide a very aesthetic, viable and cost-effective treatment option for replacing missing anterior teeth.³ Newer self-etch adhesive systems help to

ensure that such restorations are retained for reasonably long periods of time.⁴ Systematic review by Yoshida T et al has also demonstrated that resin retained fixed partial dentures have a 15-year cumulative survival rate and authors have also concluded that resin bonded fixed partial denture can be the prosthetic treatment option in patients with slight or no tooth decay.⁵ Thoma et al conducted a systematic review on the survival and complication rates of resin-bonded fixed dental prostheses after mean observation period of at least 5 years. Proper diagnosis and treatment planning is a must to allow the prosthodontist to proceed with CAD-CAM restorations. These tools can be used to predict and visualize the treatment outcome beforehand.^{6,7}

The advantages of resin bonded fixed partial denture include minimal teeth preparation since the preparation is only limited to enamel. It also aids in shade matching to the abutment teeth. The use of these technologies and software requires additional armamentarium, have a steep learning curve. Adequate training of the technicians and clinicians becomes important before the technology can be put to apt use.

4. Conclusion

Resin bonded bridges can be highly effective in replacing missing teeth, restoring oral function and aesthetics and result in high levels of patient satisfaction with minimal intervention or tooth structure reduction. The digital workflow described in this case report using a scanned cast to rehabilitate missing maxillary central incisor presents a time efficient, cost effective and a viable treatment option available for the patient which adequately helps in restoring form, function and esthetics.

5. Conflicts of Interest

The authors declare that there are no conflicts of interest regarding the publication of this paper.

6. Source of Funding

None.

References

1. Kern M, Knode H, Strubb JR. The all-porcelain, resin-bonded bridge. *Quintessence Int.* 1991;22(4):257–62.
2. Sasse M, Kern M. All-ceramic resin-bonded fixed dental prostheses: treatment planning, clinical procedures, and outcome. *Quintessence Int.* 2014;45(4):291–7.
3. Denry JR, Kelly. State of the art of zirconia for dental applications. *Dent Mater.* 2008;24(3):299–7. doi:10.1016/j.dental.2007.05.007.
4. Aboush YE, Jenkins CB. The bonding of an adhesive resin cement to single and combined adherends encountered in resin-bonded bridge work: an in vitro study. *Br Dent J.* 1991;171(6):166–9.
5. Yoshida T, Kurosaki Y, Mine A, Kimura-Ono A, Mino T, Osaka S, et al. Fifteen-year survival of resin-bonded vs full-coverage fixed dental prostheses. *J Prosthodont Res.* 2019;63(3):374–82.
6. Pimentel W, Teixeira ML, Costa PP, Jorge MZ, Tiossi R. Predictable outcomes with porcelain laminate veneers: a clinical report. *J Prosthodont.* 2016;25(4):335–40. doi:10.1111/jopr.12413.
7. Blatz MB, Vonderheide M, Conejo J. The Effect of Resin Bonding on Long-Term Success of High-Strength Ceramics. *J Dent Res.* 2018;97(2):132–9.

Author biography

Harsh Rathee, Resident

Saurav Kumar, Assistant Professor and Instructor

Parag Dua, Associate Professor and Instructor

Cite this article: Rathee H, Kumar S, Dua P. Pragmatic approach to rehabilitate maxillary teeth in aesthetic zone using resin bonded FDP- A case report. *IP Ann Prosthodont Restor Dent* 2021;7(4):226-229.