

Prosthetic Rehabilitation of Amputated Finger with Implant supported Finger Prosthesis

Aratee Gupta¹, Ashish Yadav², Atul Bhatnagar³

¹Consultant Dentist, Enamel Advance Dental Clinic & Implant Centre, Varanasi, ²Assistant Professor, Govt. Medical College, Azamgarh, ³Associate Professor, Unit of Prosthodontics & Crown & Bridge including Implantology, Faculty of Dental Sciences, Banaras Hindu University, Varanasi

**Corresponding Author:
Atul Bhatnagar**

Associate Professor, Unit of Prosthodontics & Crown & Bridge including Implantology, Faculty of Dental Sciences, Banaras Hindu University, Varanasi
E-mail: atulent@bhu.ac.in

Abstract

Loss of any part of the body leads to psychological trauma along with functional, and esthetic impairment. If this loss is visible outside, then it became more ignominious for the patient. This article represents the rehabilitation of amputated middle finger of a patient with implant supported acrylic finger prosthesis which offers a great psychological help along with function and esthetics. Osseo integrated implant offers a great retention alternative where other techniques are not so effective.

Key words: Finger prosthesis, Acrylic prosthesis, Implant supported prosthesis

Introduction

As an organ of manipulation, fingers have a supreme role in function and esthetics. Finger amputation causes devastating physical, psychosocial and economic damage to an individual. It is an experience linked with grief, depression, anxiety, loss of self-esteem and social isolation.^{1,2,3} Whatever is the reason for finger amputation either congenital abnormalities or trauma, it leave an individual with a long lasting emotional scar from disfigurement. Although various advanced micro vascular replantation surgeries help to save many severally injured and traumatically amputated finger, it may be contraindicated, unavailable, or unsuccessful in some cases. These patients can be benefited by a highly esthetic, functional passive finger prosthesis which also improve psychological status of patient.^{4,5}

With the invention of various advanced osseo integrated implants in dental and maxillofacial prosthesis, retention has been improved as compared to conventional glue, or undercut.^{6,7,8} Prosthesis shape, texture, and color should be as indiscernible as possible from the surrounding natural tissues. This case report represent the prosthetic rehabilitation of distal phalange of

amputated middle finger by simple implant retained acrylic finger prosthesis.

Case report

A 26 yr old female patient came to Unit of Prosthodontics and Crown & Bridge including Implantology, Faculty of Dental sciences IMS BHU, Varanasi for the rehabilitation of partially amputated left middle finger. She had history of trauma to her left hand while using grinder in kitchen 2 yrs back. Physical examination of hand shows that middle finger is amputated at distal interphalangeal joint (Fig. 1). The amputated finger appears normal with no sign of infection or swelling. After taking inform consent of patient it was decide to fabricate simple implant retained acrylic finger prosthesis. On the basis of CT scan and radiographic examination 3.3 X 13 mm of single body implant with ball head was selected for placement (Fig. 2).

Initially an ellipsoid flap was elevated on the stump after giving local anaesthesia (Digital block). Then articular cartilage of joint was removed. After that osteotomy was done using sequential drills in middle phalange for selected dimension of implant. After completion of osteotomy, single body implant of 3.3 x 13 mm (TRX-BA EZ Hi-Tec Implant) dimension was

inserted into prepared site and the flap was sutured(Fig. 3). The patient was recalled after three month. Till then she was instructed not do any heavy work with that finger.

After three months clinical and radiographic examination were done which shows good osseointegration with no sign of infection (Fig. 4). Then an impression of middle finger was made using Polyvinyl siloxane (Aqasil, Dentsply) impression material in which impression analogue was placed into that impression and model was poured using type III dental stone (KALSTONE, KALABHAI KARSON Pvt Ltd, MUMBAI). The model was trimmed slightly with bur to have slightly smaller sleeve to achieve vacuum effect. Impression of the middle finger of contra lateral side was made using Irreversible hydrocolloid impression material and modeling wax was poured into mould to duplicate middle finger. Then it was hollowed from inside and placed on amputated finger model with implant analogue having ball end. The female part of ball attachment was embedded into wax pattern. After that try-in was done for necessary modification in was pattern for length and fitting. An artificial nail was fabricated using cold cure acrylic resin which was characterized using acrylic stain. Nail was properly shaped and trimmed to required size and incorporated into nail bed created on wax pattern.

Now the wax pattern along with model was invested into a flask with dental plaster and dew axing was done. The acrylic stains were mixed with heat cure acrylic resin to match color of the patient's finger on dorsal and ventral side and processing was done. After processing prosthesis was retrieved from mould. Excess flash was removed using acrylic trimming burs and finishing, polishing was done using fine sand paper. Some extra staining was done from outside to match the color of skin. The final prosthesis was placed onto the amputated stump and color and fit was evaluated (Fig. 5). Instructions were given about the use and maintenance of the prosthesis.

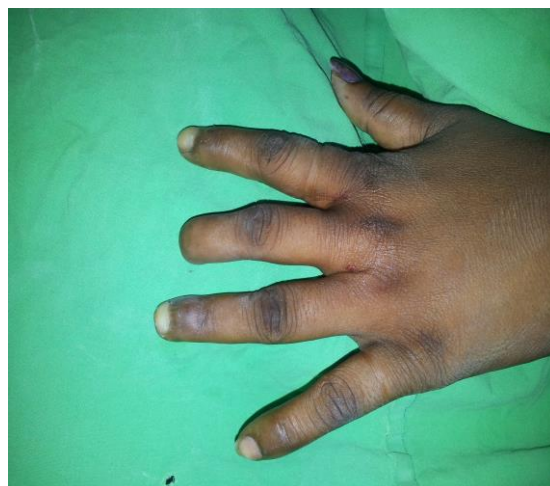

Fig. 1: Amputated middle Finger

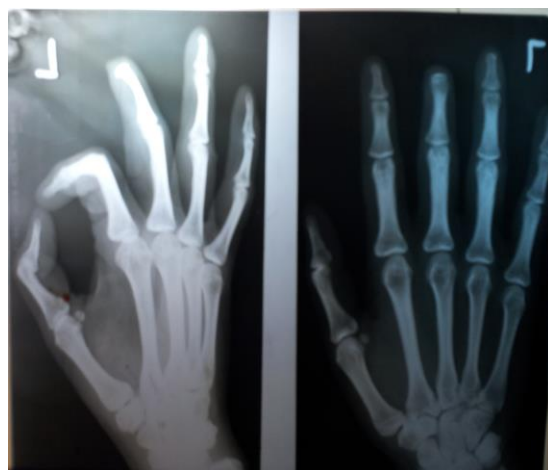

Fig. 2: Pre-operative radiograph of hand

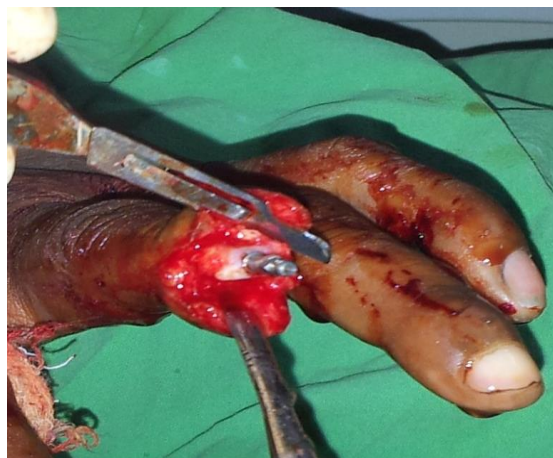


Fig. 3: Intra-operative view after implant placement

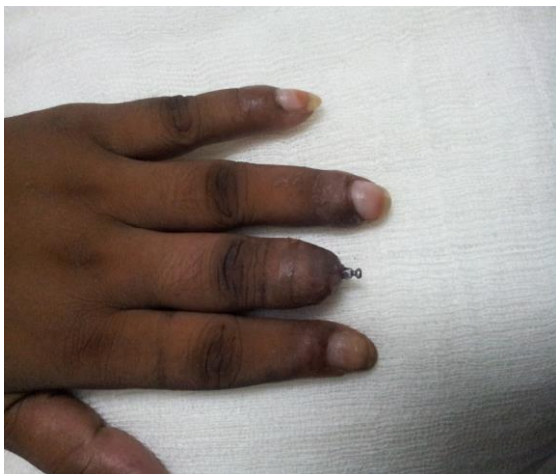

Fig. 4: Amputated finger after three months of implant placement

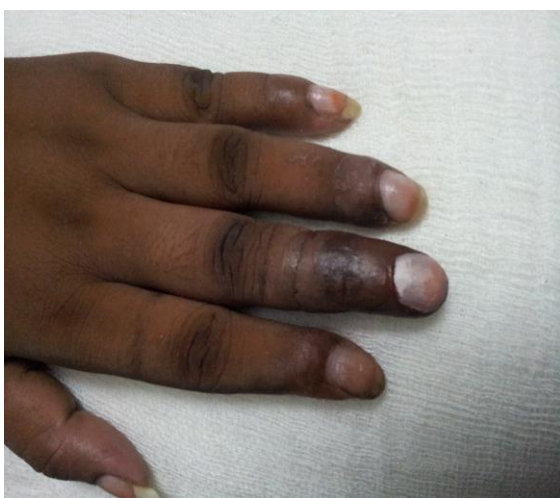

Fig. 5: Final prosthesis

Discussion

Finger injuries are one of the most common injuries of the hand. Numerous techniques are available for the repair of finger amputation with common goal to reduce pain and preserve sensation at the tip. The appropriate approach is dependent on the amount of tissue involved, the involvement of bone, the angle and level of amputation and involvement of other finger or rest of the hand.⁹ According to Pilley MJ¹⁰, Prosthesis can provide and offer great psychological help when surgical reconstruction of lost finger is contraindicated, unsuccessful or unavailable.

Jean Pillet¹¹ enumerated the essential characteristics of a prosthesis as the prosthesis should be of high quality both technically and aesthetically, resemble the digit of contra lateral hand, skin must correspond to the natural skin in all details and match the color as appropriately as

possible, should not be effected by climatic variations, heat resistant and must not be stained by ordinary materials. Prosthesis must be cleaned easily and should not irritate the skin.

The most common materials used for rehabilitation are acrylic resin and silicones. In spite of easy characterization and great durability, resins has some disadvantages like it is very hard material and uncomfortable for the patient. On the other hand, texture and flexibility of silicones are similar to the skin, provides a more comfortable prosthesis and presents better capacity for skin-prosthesis linkage. However, this material has some shortcomings also like microbial growth, instability; lack of sensibility and short durability, with proper care may last only 3-5 years, more difficult to pigment and degrades due to color instability when exposed to ultraviolet rays.¹²

Retention is the most important factor for the success of finger prosthesis. Various methods have been introduced to improve it including the use of rings at the restoration-skin junction, vacuum effect of the stump and medical adhesive. Recently osseointegrated implant-supported restorations provide several advantages, such as better esthetics, stable fixation of the prosthesis to the skeleton and restoration of some sensory feedback. The term “osseoperception” was suggested by Lundborg *et al.*¹³ to describe the vibration and position sensations acquired with osseointegration of the implant, which in turn provide psychological satisfaction to the patients to certain limit, by rehabilitating a amputated thumb with implant supported silicon prosthesis. In a group of studies it has been seen that patients, having implant supported prosthesis scored highly in the Jebsen Hand Function Test with results close to the contra-lateral hand.^{7,14} Aydin et al uses dental implant to retain a thumb prosthesis.¹⁵ Various case reports has been published which support placement of two-stage implant for prosthetic rehabilitation. This case report represents the placement of single body implant with ball end in amputated finger and its female part i.e., metal housing with nylon cap inside the prosthesis.

Conclusion

Traumatic loss of finger results in various deterioration of hand function and alters patient’s psychology. Rehabilitating the amputated finger with implant retained finger prosthesis is a substantial treatment option which provides the esthetics, functional and psychological benefits to

the patient which may be associated with some complications.

References

1. Parkes CM (1975) Psycho-social transitions: Comparison between reactions to loss of a limb and loss of a spouse. *British Journal of Psychiatry* 127:204-210.
2. Desmond D, Mac Lachlan M (2002) Psychosocial issues in the field of prosthetics and orthotics. *Prosthetics and Orthotics* 14:19-22.
3. Sabolich J, Sabolich S (2005) You're not alone, stories of 38 people who conquered the challenges of a lifetime. Oklahoma: Scott Sabolich Prosthetic and Research. 354 p.
4. Aydin C, Karakova S, Yilmaz H. Implant- retained digital prosthesis with custom- designed attachments: A clinical report. *J Prosthet Dent* 2007;97:191-5.
5. Taylor TD, Facial prosthesis fabrication: Technical aspects. *Clinical Maxillofacial prosthesis Quintessence Publishing Company; 2000;2000:255.*
6. Cervelli V, Bottini DJ, Arpino A, Grimaldi M, Rogliani M, Gentile P. Bone-anchored implant in cosmetic finger reconstruction. *Annales de Chirurgie Plastique et Esthétique.* 2008;53:365-367.
7. Manurangsee P, Isariyawut C, Chatuthong V, Mekraksawanit S. Osseo integrated finger prosthesis: An alternative method for finger reconstruction. *Journal of Hand Surgery.* 2000;25:86- 92.
8. Infanger M. [Improved fixation of finger prostheses by means of intramedullary titanium anchors and magnets]. *Handchirurgie, Mikrochirurgie, Plastische Chirurgie.* 2005;37:202-206.[Article in German]
9. Shanmuganathan N, Maheswari M Uma, Anand Kumar V, Padmanabhan TV, Swarup S, Jibrán AH. Aesthetic finger prosthesis. *Journal of Indian Prosthodontic Society.* 2011;11:232-237.
10. Pilley MJ, Quinton DN. Digital prostheses for single finger amputations. *J Hand Surg[Br]* 1999;24(5):539-41.
11. Pillet J. Esthetic hand prostheses. *J Hand Surg [Am]* 1983;8:778-81.
12. Gary JJ, Huget EF, Powell LD. Accelerated colour change in a maxillofacial elastomer with and without pigmentation. *J Prosthet Dent* 2001;85:614-20.
13. Lundborg G, Brnemark PI, Rosén B. Osseointegrated thumb prostheses: A concept for fixation of digit prosthetic devices. *Journal of Hand Surgery.* 1996;21:216-221.
14. Sierakowski A, Watts C, Thomas K, Elliot D. Longterm outcomes of osseointegrated digital prostheses for proximal amputations. *Journal of Hand Surgery, European volume.* 2011;36:116-125.
15. Aydin C, Karakoka S, Yilmaz H, Yamalik K. The use of dental implant to retain thumb prosthesis- A short term evaluation of 2 cases. *The International Journal of Prosthodontics.* 2008;21:138-140.