



Case Report

A novel technique to maximise retention in the rehabilitation of maxillectomy patients with three piece hollow bulb obturator – A case report

Poonam Prakash^{1,*}, S K Bhandari¹, D S J D'Souza²

¹Dept of Dental Surgery & Oral Health Sciences, Armed Forces Medical College, Pune, Maharashtra, India

²Maharashtra Institute of Medical Education and Research, Pune, Maharashtra, India



ARTICLE INFO

Article history:

Received 15-04-2020

Accepted 30-11-2020

Available online 02-12-2020

Keywords:

Maxillectomy

Retention

Three piece hollow bulb obturator.

ABSTRACT

Maxillary defects may be due to trauma, congenital defects or secondary to surgical correction of benign and malignant tumours. Surgical management leads to loss of maxilla, soft palate and contiguous structures leading to a communication between the oral and nasal regions that causes difficulty in speech, deglutition, mastication, respiration and loss of facial support. The goal of rehabilitation is to bring about improvement in basic functions of mastication, deglutition, speech, esthetics thereby boosting the psychological status of the patient. An obturator acts as a framework over which tissues may be shaped by the surgeon, holds the surgical dressing, serves as a temporary prosthesis during the period of surgical correction and helps to restore a patient's cosmetic appearance soon after surgery.

The basic principles of retention and stability are difficult to achieve due to increased weight of the prosthesis. Obturator is generally made in two parts i.e. the palatal portion and the hollow bulb. However in this case, a novel technique was utilized to fabricate the prosthesis in three parts i.e. the palatal portion, the hollow bulb and the hollow occlusal rim. Since there was sufficient volume in the area of occlusal rim, it was made hollow as well to further reduce the weight of the prosthesis. Using the method described, the stability and retention of the obturator were improved, speech intelligibility increased, and food and liquid leakage to the nasal cavity were reduced.

© This is an open access article distributed under the terms of the Creative Commons Attribution License (<https://creativecommons.org/licenses/by/4.0/>) which permits unrestricted use, distribution, and reproduction in any medium, provided the original author and source are credited.

1. Introduction

The etiology of maxillary defects may be trauma, congenital defects or the surgical treatment sequelae of benign or malignant neoplasms. Surgical resection of the maxilla or the soft palate results in the loss of the palate, maxilla, and contiguous structures leading to a communication between the oral and nasal regions that causes difficulty in speech, deglutition, mastication, respiration and loss of facial support.¹

Obturator prosthesis is most frequently the choice of treatment due to the complexity of maxillary surgical reconstruction and the uncertainty of the functional outcome. The prosthesis recreates a partition between the oral and nasal cavities, restores facial contour, improves

mastication, articulation, speech intelligibility, provides lip support and reduces drooling. These improvements are not just physiological but also significantly improve the morale of the patient.²

Patients with maxillary resection present a challenging situation for the maxillofacial Prosthodontist. Support and retention of the prosthesis is often difficult to achieve due to limited number of teeth, lack of favorable tissue undercuts, and presence of non-keratinized nasal mucosa. Retention of such large obturator prostheses is generally a problem and patients often support the obturator using the dorsum of the tongue.³

The most important objective of prosthodontic care is preservation of the remaining teeth and tissue. Improvement in mastication, speech, deglutition and esthetics are also important associated aspects of the multidisciplinary

* Corresponding author.

E-mail address: pnmprakash@yahoo.co.in (P. Prakash).

management. This paper describes a technique to reduce the weight of the prosthesis thereby improving retention and stability.

2. Case Report

A 50 year old female patient was referred to Division of Prosthodontics, Department of Dental Surgery, AFMC, from Department of Otorhinolaryngology for pre-surgical prosthetic evaluation. Patient was a diagnosed case of carcinoma left maxillary sinus and was scheduled to be operated two days later. Medical history revealed that she had difficulty in breathing since last few months for which she reported to Department of Otorhinolaryngology at Command Hospital (Southern Command). On extra-oral examination, no facial asymmetry or swelling was detected. Regional lymph nodes were soft and not fixed to the underlying structure. The treatment plan formulated was surgical resection of left maxilla followed by rehabilitation with obturator prosthesis.

Thorough oral prophylaxis was carried out; impressions were made and poured in dental stone to fabricate working casts. The anticipated line of resection was marked on the maxillary definitive cast in consultation with the surgical team [Figure 1a]. Teeth present on the resection area were trimmed off from the maxillary cast and the area was smoothed to simulate the form of an edentulous ridge. A surgical obturator was then fabricated using heat cure acrylic resin and sterilized by immersing in 2% glutaraldehyde solution overnight. Patient was taken up for resection of left maxilla under GA. Following resection, split thickness skin graft was harvested from the medial aspect of right thigh and placed on the recipient site i.e. left buccal mucosa. Surgical obturator was placed immediately and was sutured to the buccal mucosa utilizing the holes made on the resection side [Figure 1b]. Surgical defect was packed with gauze soaked in whitehead varnish which consists of tincture benzoin, balsam of tolu, liquid paraffin, solvent ether and storax. Patient was reviewed at 24 hrs, 48 hrs and 72 hrs post-operatively. Post op period was uneventful and nasogastric tube was removed and patient was able to feed normally after 48 hrs.

On 10th post-operative day, the patient was taken up for fabrication of interim obturator [Figure 2a]. The deeper undercut areas were packed with moist cotton gauze to restrict the flow of impression material. The surgical obturator was cleaned, perforations made and it was used as a special tray. The impression of the defect areas was made using irreversible hydrocolloid impression material. A cast was fabricated by pouring the impression with dental stone.

The interim obturator prosthesis was designed to be in two portions. The first portion extended into the defect area while the second portion acted as palatal plate. The area between the two portions was to be kept hollow so that the prosthesis was light in weight. Undercuts on the defect

area were blocked with modeling clay and a wax sheet was adapted to the rest of the defect area. This bulb portion was then flaked and converted to polymethylmethacrylate resin. After suitable blockout, the palatal plate portion was separately fabricated in wax, flaked and acrylised. The two portions of the interim obturator were joined together using autopolymerising acrylic resin. The obturator was checked for any leakage by immersing in water. The prosthesis should float if the hermetic seal is maintained. The prosthesis was tried in and minor adjustments were carried out. Patient was taught insertion and removal of the prosthesis and explained about care during mastication. Detailed instructions about care and maintenance of the prosthesis were given to the patient. Patient was asked to report every two weeks for follow-up.

On recall after 4 weeks, a second interim obturator was fabricated as there were significant changes in the defect area [Figure 2b].

After 04 months, the patient was taken up for fabrication of definitive prosthesis. The obturator was planned to be fabricated in three portions separately i.e. the base with the hollow bulb, the lid and the occlusal rim with the teeth. After the base with the bulb was tried-in satisfactorily, the hollow occlusal rim was fabricated. A mixture of pumice with autopolymerising acrylic resin was made in shape of occlusal rim and wax up with the teeth was done over that [Figure 3a]. The try-in was done and minor adjustments carried out [Figure 3b]. Orientation notches were made in the base and occlusal rim was separated from the base. It was then flaked and dewaxing done. The block of pumice-self cure resin was removed and wax up was finished with parallel walls so as to facilitate the removal of hollow occlusal rim while deflasking. It was finished and polished and secured on the hollow bulb palatal plate with the help of orientation grooves. It was fused with self cure acrylic resin and tried in patient's mouth [Figure 3c]. The occlusal scheme on the unaffected side was multiple simultaneous contacts between maxillary and mandibular teeth and on the affected side; contacts were provided upto second premolar and minimally light contacts thereafter [Figure 4]. Minor occlusal adjustments were carried out and necessary instructions were given to the patient. Significant improvement in speech, deglutition & mastication was reported by the patient.

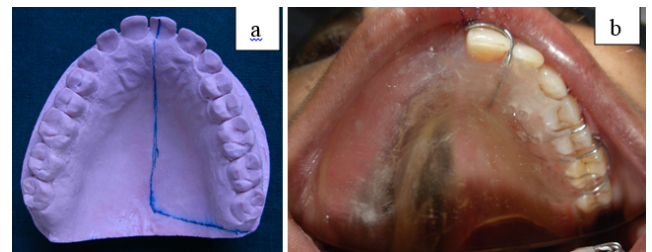


Fig. 1: (Surgical obturator), **1a:** Resection line, **1b:** In situ

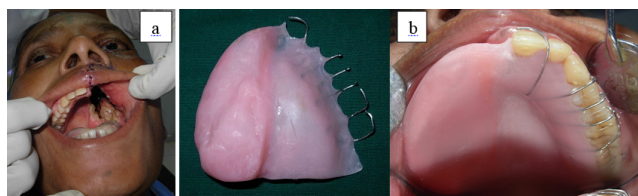


Fig. 2: (10th & 30th post op day Interim hollow bulb obturator), **a:** 1st interim obturator, **b:** 2nd Interim hollow bulb obturator.

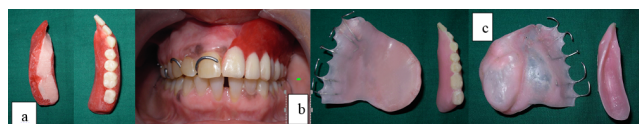


Fig. 3: (4 months post operative 3 piece hollow bulb obturator), **a:** Hollow occlusal wax rim, **b:** Try in, **c:** 3 Piece hollow bulb obturator

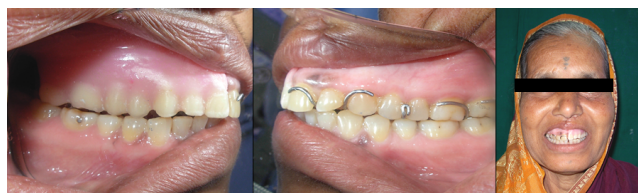

Fig. 4: (4 months post operative)

3. Discussion

The earliest attempts at obturator construction are credited to Ambrose Pare who, around 1530, described button-shaped obturators made of metal and sponge. An obturator is a disc or plate, natural or artificial which closes an opening or defect of the maxilla as a result of cleft palate or partial or total removal of the maxilla.⁴ An obturator acts as a framework over which tissues may be shaped by the surgeon, holds the surgical dressing, serves as a temporary prosthesis during the period of surgical correction and helps to restore a patient's cosmetic appearance as soon as possible after surgery. It is useful when surgical closure is contraindicated or when the patient's age contraindicates surgery; when the size and extent of the deformity contraindicates surgery; when the local avascular condition of the tissues contraindicates surgery.

There are three types of obturators i.e. Surgical, Interim and Definitive obturators.⁵ Surgical obturator is a base plate type appliance which is constructed from the pre-operative impression cast and inserted at the time of resection of the maxilla in the operation theatre. Interim obturator is constructed from the postsurgical impression cast and replaces the palate, ridge and generally has no teeth. The patient is usually reviewed every 2 weeks because of the rapid soft tissue changes that occur within the defect during

organization and healing of the wound. Approximately 3-4 months after surgery, definitive obturator prosthesis may be fabricated if the patient is comfortable and disease free. This type of obturator restores the lost palatal contours, ridge area and has a closed hollow bulb.

The bulb extending into the defect area could be open or closed but is usually made hollow. There are advantages and disadvantages to both open and closed designs of obturators. If the obturator is left open, nasal secretions accumulate leading to odour and added weight. If secretions do tend to accumulate, a small diagonal opening may be made through the inferior-lateral walls of the obturator to the cheek surface for drainage. The other disadvantages of an open type hollow obturator include difficulty in polishing and cleaning the internal surface which is necessary due to the accumulation of deposits from saliva, mucous crusts, and food.

3.1. Prosthodontic considerations to be conveyed to Oncosurgical team

1. Maintain as much hard palate as possible since it is vital for retention, stability and support of prosthesis.
2. Resection line should pass through the alveolar socket and not through inter-radicular area so as to preserve the tooth adjacent to that site.
3. Skin grafting of the buccal flap as well as exposed bony structure provides stress bearing area for the prosthesis subsequently. The lateral scar band at the junction of the oral mucosa and skin graft also aids in retention.
4. The inferior turbinate must be removed as it interferes with the prosthesis and reduces the height available for the hollow bulb portion.
5. Medial resection site (alveolar bone) should be covered with oral mucosa because if left uncovered could normally lead to bone necrosis due to post surgical radiation therapy. Bone necrosis could lead to loss of tooth as well as in extreme situation could lead to osteoradionecrosis.

4. Summary

Patients with intraoral defects due to partial maxillectomy in cases of neoplasms form a highly heterogeneous group. Each situation requires individual assessment for the best protocol for rehabilitation. It is critically important that prosthesis weight be minimized to reduce the likelihood of damage to the abutments. Recovery of patient's speech and deglutition after maxillectomy is desirable.

Various materials are used to fabricate the obturator like Polymethylmethacrylate, light-polymerized resin and silicone.^{6,7} Routinely the obturator is made in two parts i.e. the palatal portion and the hollow bulb.⁸ However in this case, an attempt was made to fabricate the prosthesis

into three individual components i.e. the palatal portion, the hollow bulb and the hollow occlusal rim. Since there was sufficient volume in the area of occlusal rim, a special effort was made to make that hollow as well to further reduce the weight of the prosthesis. Using the method described, the stability and retention of the obturator were improved, speech intelligibility increased, and food and liquid leakage to the nasal cavity were reduced.

Acceptable Prosthodontic care for the patient with the acquired maxillary defect should include cautious prosthesis design combined with routine maintenance to provide restoration of comfort, function, cosmetics, and minimal change to the compromised remaining structures.

5. Source of Funding

No financial support was received for the work within this manuscript.

6. Conflict of Interest

The authors declare they have no conflict of interest.

References

1. Aramany MA. Basic principles of obturator design for partially edentulous patients. Part I: Classification. *J Prosthet Dent* . 1978;40(5):554–7. doi:10.1016/0022-3913(78)90092-6.
2. Aramany MA. Basic principles of obturator design for partially edentulous patients. Part II: Design principles. *J Prosthet Dent*. 1978;40(6):656–62. doi:10.1016/0022-3913(78)90065-3.
3. Aras E, tert SC. Design and construction of pediatric interim obturators. *J Prosth Dent*. 1989;62(1):54–5. doi:10.1016/0022-3913(89)90048-6.
4. Key F. Obturator prostheses for hemimaxillectomy patients. *J Oral Rehabil*. 2001;28:821–9.
5. Sankaranarayanan R. Oral cancer in India: An epidemiologic and clinical review. *Oral Surg, Oral Med, Oral Pathol*. 1990;69:325–30. doi:10.1016/0030-4220(90)90294-3.
6. Mukohyama H, Sasaki M, Taniguchi H. Chairside modification of a surgical obturator: A clinical report. *J Prosth Dent*. 2004;91(6):518–20. doi:10.1016/j.prosdent.2004.03.023.
7. Grossmann Y, Savion I. The use of a light-polymerized resin-based obturator for the treatment of the maxillofacial patient. *J Prosthet Dent* . 2005;94(3):289–92. doi:10.1016/j.prosdent.2005.06.014.
8. Haraguchi M, Mukohyama H, Taniguchi H. A simple method of fabricating an interim obturator prosthesis by duplicating the existing teeth and palatal form. *J Prosthet Dent* . 2006;95(6):469–72. doi:10.1016/j.prosdent.2006.04.004.

Author biography

Poonam Prakash, Associate Professor

S K Bhandari, Professor and HOD

D S J D'Souza, Consultant

Cite this article: Prakash P, Bhandari SK, D'Souza DSJ. A novel technique to maximise retention in the rehabilitation of maxillectomy patients with three piece hollow bulb obturator – A case report. *IP Ann Prosthodont Restor Dent* 2020;6(4):224-227.