

## Rehabilitation of patient with ocular defects-Case report

Subodh Shrestha<sup>1</sup>, Kaushik Kumar Panday<sup>2\*</sup>, Pratibha Katiyar<sup>3</sup>, Fauzia Tarannum<sup>4</sup>, Shaily Tyagi<sup>5</sup>, Swati Mishra<sup>6</sup>

<sup>1,6</sup>Post Graduate Student, <sup>2</sup>Associate Professor, <sup>3</sup>Professor, <sup>4,5</sup>Assistant Professor, <sup>1-6</sup>Dept. of Prosthodontics, Career Postgraduate Institute of Dental Sciences and Hospital, India

**\*Corresponding Author: Kaushik Kumar Panday**

Email: kaushik.pandey05@gmail.com

### Abstract

Eyes are precious part of our body. Loss of an eye not only cause psychological trauma to patient but also impaired vision. Rehabilitating patients with prosthetic eye would give them social acceptance and good cosmetic results. A step by step, prosthodontic management of right eye defect in old age patient is described in this paper.

**Keywords:** Ocular defect, Rehabilitation, Eye prosthesis.

### Introduction

In living organism, eyes play a most important role. Eyes are observed first after watching the face. Congenital or accidental loss of eye can cause impaired vision and loss of facial esthetics. Patients are feeling ashamed in society due to ocular defects. So patient passes through the psychological trauma due to the ocular defects. Ocular defects after surgery can be classified in three types; evisceration, enucleation and extenteration. Term evisceration means the removal of ocular content from intact sclera. In enucleation surgeon preserves the periorbital and orbital structures while entire globe with its interocular content is removed. In extenteration the entire orbital content with globe and soft tissue is removed.<sup>1-3</sup>

Ocular defect is corrected in department of Prosthodontics by trained maxillofacial Prosthodontist. There are two main terms are given for ocular defects; 1) phthisical eye, 2) anophthalmic socket. In phthisical eye, sclera shell prosthesis is given to patients, as the defect is minimal. While for an anophthalmic socket, complete ocular prosthesis is suggested to the patients.

Surgical reconstruction of ocular defect requires trained super specialized ophthalmic surgeons. The surgical procedure is costly and prognosis is not clear. Sometimes patients are also not ready for surgery due to surgical phobia. In this situation, the only option is given to patient is the maxillofacial prosthetic eye. Prosthetic eye regain the confidence and social acceptance of the patients. Most popular material for ocular prosthesis is polymethylmethacrylate (PMMA). PMMA has many advantage over other materials indicated for ocular prosthesis. It is less technique sensitive, low cost, mostly non allergic material. In this paper, step by step procedure of fabrication and rehabilitation of a patient with ocular defect is presented. The ocular prosthesis with simultaneous rehabilitation of missing teeth which is described in this paper is fabricated in PG Clinic of department of prosthodontics, career post graduate institute of dental sciences and hospital, Lucknow.<sup>4-8</sup>

### Case Report

A 63 year old female patient reported to Career Post Graduate Institute of Dental Sciences & Hospital, Lucknow with chief complaint of difficulty in eating and loss of right eye. On extra oral examination it was found that her right eye was lost due to infection in childhood. There was no abnormality found in temporomandibular joint. Her face was ovoid. Her profile was straight. On intraoral examination it was found that full edentulous maxillary arch and missing 31,32,33,41,42,47 in mandibular arch. Patient was illiterate and housewife. She belonged to economically weaker section. On the basis of her current condition treatment plan given to her was full thickness scleral prosthesis, maxillary complete denture with meshwork and mandibular flexible RPD. After explaining treatment cost, duration and prognosis to patient and her relatives, they gave final consent for treatment. Fig.1,2

### Step

#### Impression procedure

#### Eye prosthesis

A conformer is selected for eye impression and trimmed according to patient's right eye. Syringe hood is attached with conformer before impression. Light body is filled in syringe and tray with hood is attached on it. Impression was taken. While taking impression, patient was asked to move his eye muscles in right, left, upper and lower direction so as to get molded impression. Fig. 3

#### Dental Prosthesis

Edentulous Stock tray for maxillary and perforated tray for mandibular primary impression was selected. Upper impression was taken with impression compound and lower impression was taken with alginate. Upper primary cast was poured and special tray was fabricated. Border molding and final impression was done for upper arch. Record base and rim was fabricated on upper and lower cast. Jaw relation was done. Teeth setting and try in was done. After processing dental prosthesis was delivered. Fig. 4,8

### Wax-pattern for Sclera

Final impression of ocular defect was poured in two half as to get two piece moulds. The white pattern wax was used to make the scleral wax pattern. After complete carving, the wax pattern was tried in on ocular defect of the patient. Patient was asked to sit upright and look straight during trial. Patient's left eye was taken as a guide for overall appearance. The shade of iris was selected and matching stock eye was brought. The iris was cut from the selected stock eye and sealed upon the center of scleral wax pattern. The patient's left iris position was marked with graph grid method and this was used to position the right iris of ocular prosthesis.<sup>9,10</sup> Fig. 5,6,7

### Flasking of Ocular Prosthesis

After the ocular prosthesis wax pattern was successfully tried in patient's right eye, lab procedure started. During this stage, upper half of the mould was not used as the ocular wax pattern was fabricated on lower half. An acrylic hood was attached on the centre of the iris, so as to prevent it from dislocation. Acrylic hood also helps in repositioning of the iris, if it gets dislodged after de-waxing. After applying petroleum jelly on acrylic hood, boxing of mould, the second pouring and completion of flasking done. After dewaxing, packing was done with heat cure resin. Shade matching was done earlier and same shade of acrylic resin was used for sclera. The curing was done on thermostatic acrylizer. After completion of curing, overnight bench cooling was done.<sup>4,6</sup>

### Finishing and characterization of ocular prosthesis

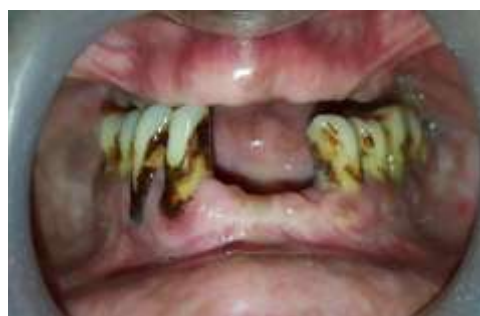After processing of ocular prosthesis, deflasking was done. The acrylic hood was trimmed first. Sharp margins were rounded off. The finishing and polishing was completed. Ocular prosthesis was first placed in defect to check the fitting. All the necessary adjustment was done. Once again the position, shade of iris and sclera was rechecked and verified with contra lateral eye. The ocular prosthesis should be characterized according to the normal natural eye. The red fibers form heat cure resin was used to mimic the blood supply in the ocular prosthesis. An external color was used to mimic the natural eye. All the colors and fibers were stabilized with a very thin layer of cyanoacrylate adhesive. A clear heat cure resin was used over the characterized ocular prosthesis. Again processing, finishing and polishing of the ocular prosthesis were done.<sup>11,12</sup>

### Final insertion of ocular prosthesis

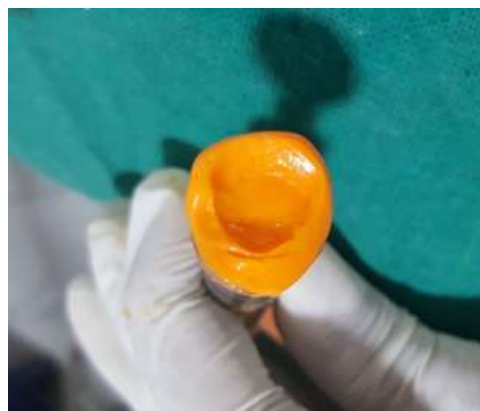After processing, the ocular prosthesis was inserted in the right ocular defect. The final fit, contour, shade matching and life like appearance were verified. Post insertion instruction was given to patient. Patient was recalled after regular interval for follow-up. During follow-up, no irritation, allergy, watering was found. Patient was also maintaining the ocular prosthesis properly and was fully satisfied with it.<sup>6-19</sup> Fig. 8



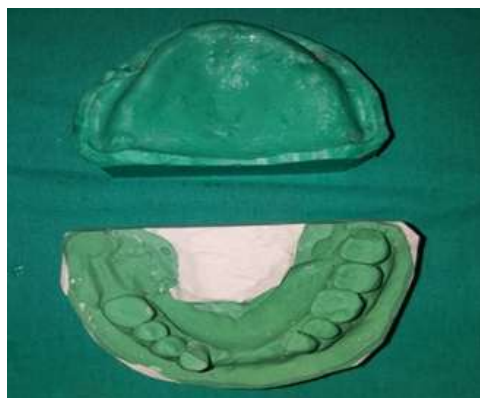**Fig. 1:** Preop front view showing defective right eye and missing teeth



**Fig. 2:** Preop intraoral front view showing missing teeth



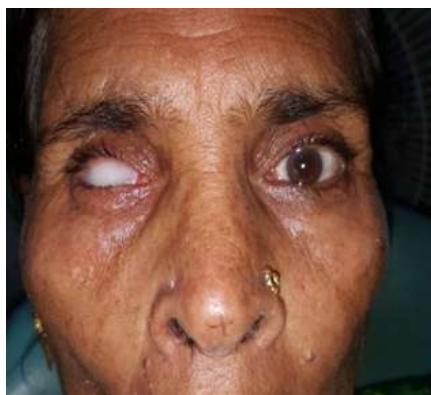**Fig. 3:** impression of ocular defect



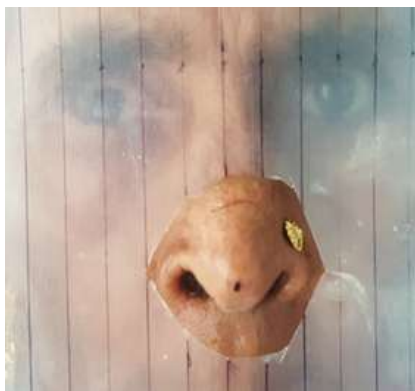
**Fig. 4:** Maxillary and mandibular master cast



**Fig. 5:** ocular impression poured and two piece cast is retrieved



**Fig. 6:** Scleral wax pattern try in



**Fig. 7:** marking of IRIS



**Fig. 8:** Post op view; eye prosthesis and denture delivered

## Discussion

In this case report customized ocular prosthesis and denture fabrication completed in same visits. Patient was happy with the esthetics of both denture and ocular prosthesis. Customized ocular prosthesis has the advantages over stock eyes like, better contouring, color matching, and coordinated movements with the contralateral eye.<sup>5-7</sup> A skilled clinician and lab-technician play a major role in success of customized ocular prosthesis. Customizing the iris demands extra skill and time from the operator. This can be avoided if stock iris matching with the contralateral natural eye is available. Semi-customizing the prosthesis using the stock iris and customized sclera will have advantages of both stock and custom prosthesis. This technique is not advised when the color, contour, and configuration of the stock iris is not satisfactorily matching with the contralateral natural eye of the patient.<sup>11-16</sup>

## Conclusion

Success of the ocular prosthesis largely depends on the precise laboratory technique and artistic skills of the operator. Through this technique, the contralateral natural eye can be matched with customized ocular prosthesis. Patient's satisfaction is greater than stock eye.

**Conflicts of Interest:** None.

**Source of Support:** None.

## References

1. Parr GR, Goldman BM, Rahn AO. Surgical considerations in the prosthetic treatment of ocular and orbital defects. *J Prosthet Dent* 1983;49:379-85. [PubMed]
2. Benson P. The fitting and fabrication of a custom resin artificial eye. *J Prosthet Dent*. 1977;38(5):532-8. [PubMed]
3. Murphey PI, Schlossberg L. Eye replacement by acrylic maxillofacial prosthesis. *Naval Med Bull* 1944;43:1085.
4. Dyer NA. The artificial eye. *Aust J Ophthalmol* 1980;8(4):325-7. [PubMed]
5. Allen L, Webster HE. Modified impression method of artificial eye fitting. *Am J Ophthalmol* 1969;67(2):189-218. [PubMed]
6. Taicher S, Steinberg HM, Tubiana I, Sela M. Modified stock-eye ocular prosthesis. *J Prosthet Dent* 1985;54(1):95-8. [PubMed]
7. Aggarwal H, Singh RD, Kumar P, Gupta SK, Alvi HA. Prosthetic guidelines for ocular rehabilitation in patients with phthisis bulbi: A treatment-based classification system. *J Prosthet Dent* 2014;111(6):525-8. [PubMed]
8. Guttal SS, Patil NP, Vernekar N, Porwal A. A simple method of positioning the iris disk on a custom-made ocular prosthesis. A clinical report. *J Prosthodont* 2008;17(3):223-7. [PubMed]
9. Parr GR, Goldman BM, Rahn AO. Postinsertion care of the ocular prosthesis. *J Prosthet Dent* 1983;49(2):220-4. [PubMed]
10. Sykes LM. Custom made ocular prostheses: A clinical report. *J Prosthet Dent* 1996;75(1):1-3. [PubMed]
11. Sykes LM, Essop AR, Veres EM. Use of custom-made conformers in the treatment of ocular defects. *J Prosthet Dent* 1999;82(3):362-5. [PubMed]
12. Beumer J, Curtis TA, Marunick MT. Maxillofacial rehabilitation, Prosthodontic and surgical considerations. St. Louis, 1996: The CV Mosby Co.

14. Dahane TM, Bhandari AJ. Prosthodontic Rehabilitation of a Patient with Orbital Defect: case report. *J Indian Prosthodont Soc* 2009;4:9-11.
15. Cain JR. Custom Ocular Prosthesis. *J Prosthet Dent* 1982;48:690-4.
16. Thomas D Taylor: Clinical Maxillofacial Prosthetics, Quintessence: Chicago, 2000;265-7.
17. Prashanti E, Reddy JM, Vinay Kumar, Mathew X, All about Ocular Prosthesis-A Review. *Indian Dent Res Rev* 2008;63:53-8.
18. Raizada K. Ocular prosthesis: Contact Lens Anter Eye. *J Am Dent Assoc* 2007;30:152-62.

**How to cite this article:** Bhasin T. Rehabilitation of patient with ocular defects-Case report. *J Nutr, Metab Health Sci*, 2019;2(2):46-9.