

Management of severely resorbed ridges with hollow dentures in neutral zone - A case report

Srinivas Ohatker^{1*}, Chitturi Ravi Kumar², Machha Sujesh³, Sreenivasulu. D⁴, Gurram Sunil Kumar⁵

¹Post Graduate Student, ²Professor and Head, ³Professor, ^{4,5}Reader, Dept. of Prosthodontics and Crown & Bridge, Mamata Dental College, Khammam, Telangana, India

***Corresponding Author:**
Email: srinivasin09@gmail.com

Abstract

Complete denture is the widely used and commonest form of treatment for the edentulous jaws but it becomes the most challenging task to provide a stable retainable prosthesis. To the rescue of this problem comes in the neutral zone of the patients oral cavity where the forces exerted during functions by the cheek and tongue are minimum and therefore it is called as the Zone of Minimum conflict.

This case report deals with resorbed residual ridge, for the construction of denture in the neutral zone and with an aim to readdress the use of materials and techniques which provides better stability and masticatory efficiency but also to make them rigid, tough, and substantially light weighted so as to make the prosthesis more sustainable. A subjective evaluation of these dentures on the patient perception was done based on the individual prosthesis provided.

Keywords: Denture stability, Neutral zone technique, Resorbed ridge, Hollow denture.

Introduction

The goal of dentistry is for patients to keep all of their teeth throughout their lives in health and comfort. If the teeth are lost despite all efforts to save them, a restoration should be made in such a manner as to function efficiently and comfortably in harmony with the muscles of the stomatognathic system and the temporomandibular joints.

Complete dentures are primarily mechanical devices, but since they function in the oral cavity, they must be so fashioned that they are in harmony with normal neuromuscular function. Failure to recognize the cardinal importance of tooth position, flange form and contour often results in dentures which are unstable and unsatisfactory, even though they were skillfully designed and expertly constructed.

The stable position of the teeth represents equilibrium of all the forces acting on them. If that position of equilibrium namely the neutral zone, is not found, the resulting dentition will not last long and will not be esthetically pleasing and the patients use of functional efficiency, maximum length of use and pleasing esthetics will not have been met.

Prosthodontic treatment in complete dentures is influenced by the concept that form follows function. Complete dentures that are constructed by concepts that do not take into consideration the unique functioning of the individual patient musculature are over looking this basic law of physiology.

1. If form is dictated by function, then in complete denture construction the operator must shape and form dentures to be in harmony with function
2. In all areas of dentistry, the ultimate problem in maintaining the health of the stomatognathic system throughout life is one of harmonious pressure distribution. The primary function of this

system is the application, distribution and dissipation of the pressure of the bite and of the muscles of the lips, cheeks and tongue.

3. To put it more simply, the primary function of the stomatognathic system is mastication.
4. The prosthodontist who is unaware of the effect of muscle function will be faced with cases of prosthodontic relapse -unstable dentures.

To understand the stable position of teeth, the concept of neutral zone is important.

Wealth in 1970, had demonstrated that there is a difference in the shape of the denture space and resultant arch form at rest as compared to the denture space and arch form established by function.

Neutral zone was coined by Beresin & Schiesserin 1976, as, that area in the mouth where, during function, the forces of the tongue pressing outward are neutralized by the forces of the cheeks and lips pressing inward.

In completely edentulous patients there exists within the oral cavity a void that may be called the potential denture space. The denture space is bounded by the maxilla and soft palate above, by the mandible and floor of the mouth below, by the tongue, medially or internally, and by the muscles and tissues of the lips and cheeks laterally or externally. Within the denture space there is an area that has been termed the neutral zone.

It is defined as "The potential space between the lips and cheeks on one side and tongue on the other, that area or position where the forces between the tongue and lips or cheeks are equal" (G.P.T 10)

Achieves 2 Objectives

1. No interference of teeth with normal muscle function
2. Muscular forces more favorable for stability & retention so that all the forces exerted are neutralized.

Case Report

A 60-year-old female by name Karunamma reported to the Department of Prosthodontics at Mamta Dental College with a chief complaint of unstable Dentures, difficulty in chewing food and wanted stable dentures.

The patient gave no significant medical history and did not report any signs of temporo-mandibular joint disorder or myofascial pain dysfunction. Extra oral examination revealed no facial asymmetry or muscle tenderness. The facial type of patient was oval. The mandibular range of motion was within normal limits. Intraoral examination revealed resorbed mandibular ridge with increased inter arch space. Dental history revealed her to be a denture wearer since 6 years.

Treatment options like implant supported complete denture were not feasible due to economic factors. As the lower ridge was resorbed, complete denture with in

the neutral zone was planned. Also to increase comfort and prevent the further residual ridge resorbition, hollow dentures were planned. Therefore the treatment plan concluded the preparation of a hollow complete denture with in the neutral zone. To compare this denture, a conventional Denture and a denture with in the neutral zone was also fabricated.

Clinical Procedure

The primary impression were made using impression compound with non-perforated metallic edentulous stock tray on the maxilla and for mandible impression compound low fusing Type I impression compound (green stick) mixed in with non-perforated metallic edentulous stock tray.

A customized tray was fabricated and border molding was performed using the low fusing Type I impression compound (green stick) to represent the muscle activity and for recording the functional depth and width of the sulcus. The final impressions were made using the low viscosity mucostatic zinc oxide eugenol paste and the master cast was poured in dental stone. Fabrication of wax occlusion rims were done on maxillary and mandibular cast.

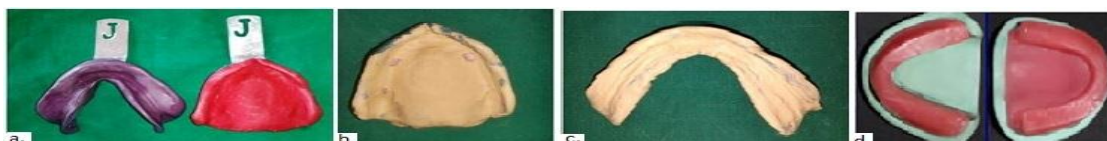

Fig. 1. a: Preliminary impression

Fig. 1. b, c: Maxillary and mandibular secondary impression

Fig. 1. d: Occlusal rims fabrication

Wax rims were used for Jaw relations carried out in the conventional method to record a tentative vertical dimension and centric relation. Facebow recorded and transferred to Hanau articulator. Casts were then articulated on the articulator. Denture base was made for both jaws, which were with spurs or fins projecting toward the opposite arches, also with occlusal stops to maintain the vertical dimension. Onto which the compound rim was fabricated.

Patient was made to sit in the comfortable upright position with the head unsupported. Recording of

neutral zone was done by asking the patient to perform a series of actions designed to simulate the physiological functioning like swallowing, drink water, whistling, pursing the lips. Tray was carefully adjusted in the articulator; occlusal plane was established for the upper arch by placing the upper compound rim and lower wax rim in CR. A plaster index was made around the molded impression compound rim upper compound rim to fabricate the wax occlusal rim by pouring wax into the space giving an exact representation of the neutral zone.



Fig. 2. e: Facebow recorded and transferred to Hanau articulator. Wax rims were used to record a tentative vertical dimension and centric relation and was transvered to the articulator.

Fig. 2. f, g: Denture bases with spurs or fins projecting toward the opposite arches, also with occlusal stops in order to maintain the vertical dimension, Fig. 2. h: Recording of neutral zone.

Fig. 2. i: Occlusal plane was established for the upper arch by placing the upper compound rim and lower wax rim in CR.

In a similar fashion, neutral zone for mandible was recorded. VD was established in the patient's mouth against upper occlusal rim and checked in the articulator. And plaster index was made followed by fabrication of wax occlusal rim in neutral zone. Teeth

arrangement was done with the help of the plaster index. During the setting of the teeth their position was checked by putting the indices together around the wax try-in. Wax Try-in was done.

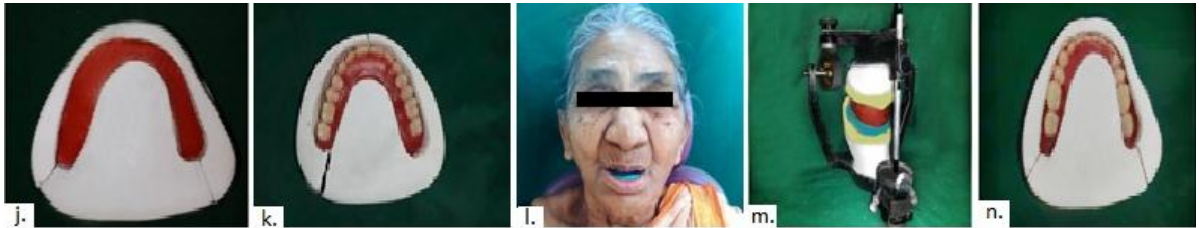

Fig. 3. j.: A plaster index was made for upper compound rim for the occlusal rim in wax
Fig. 3. k., n.: Teeth setting was done with the help of the plaster index.
Fig. 3. l., m.: Neutral zone for mandible was recorded

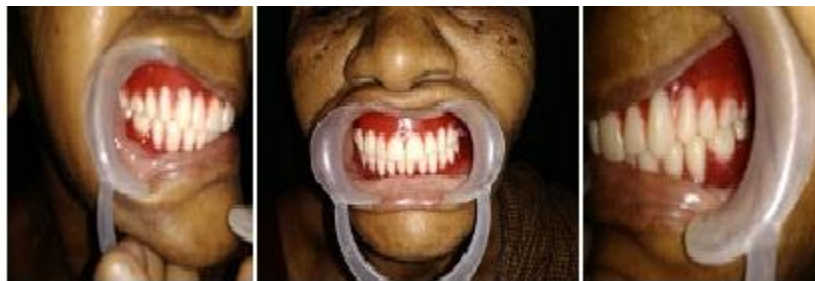

Fig. 4: Try-in done

Laboratory Procedures

Flasking and dewaxing was done. Heat cured permanent record base was fabricated. Sugar Syrup was placed over the Heat cured record base. Packing was done using Heat cured acrylic resins. A trail closure was done to check if the sugar syrup was properly

placed. After deflasking and acrylization dentures were obtained. Dentures were trimmed and polished. Hot water was flushed in to remove the sugar syrup.

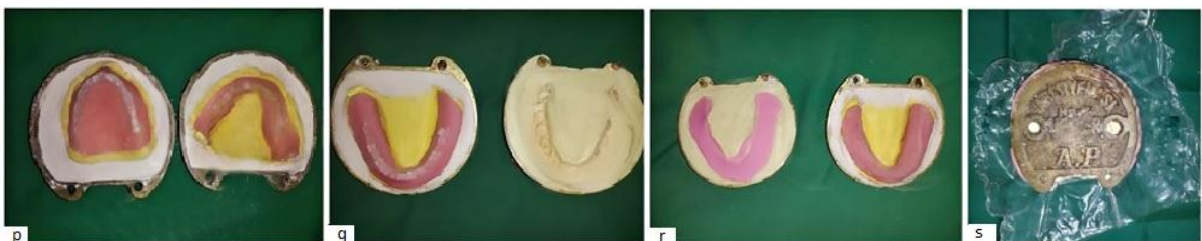


Fig. 5. p, q: Placement of sugar crystals over the denture base
Fig. 5. r: Packing done
Fig. 5. s: Trail closure

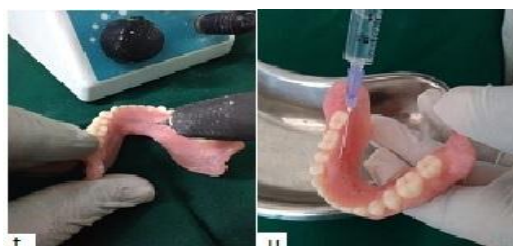


Fig. 6. t, u: Hot Water used to flush the sugar crystals

Insertion of the Hollow Complete denture with in the neutral zone was done



Fig. 7. v.: Insertion of hollow denture in neutral zone

Fabrication and insertion of a conventional denture and a denture in neutral zone was done. Patient was recalled after every 2 weeks made to wear a new set of denture. After 6 weeks, out of the three dentures,

patient was asked to choose one set of denture which she was comfortable with. Among the three dentures, patient chose hollow denture over the rest two.

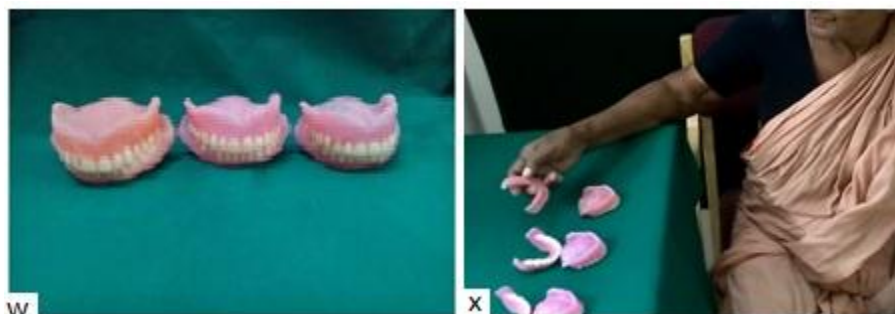

Fig. 8. w.: (Left to right) Hollow denture in neutral zone, denture in neutral zone, conventional denture
Fig. 8. x: Selection of the denture by the patient

Discussion

The severely atrophic Mandible poses a clinical challenge for fabrication of a successful complete denture.

Perhaps the greatest controversy lies in the arrangement of teeth. This concept does not advocate placement of teeth on the ridge. Rather it is most of the time buccal or labial. According to pound “tooth over the ridge concept is a fallacy”.

Pound, Pointed out that in advanced resorption the maxillary ridge moves lingually and the mandibular ridge moves buccally. He also stated that “tooth over the ridge is the greatest fallacy.

“Formerly all teeth were placed over the ridge. This was done for mechanical reasons when leverage was the big concern. Now however teeth are being successfully placed in the neutral zone which is in fact the zone previously occupied by the natural teeth. Leverage is not ignored but a lack of favorable leverage is counterbalanced by the controlling action of cheek, lips and tongue that confine the dentures. Thus the same factors that helped to position the natural teeth in the dental arches can help to maintain the artificial teeth in their places”. Boucher (1975)

The greater the ridge loss, the smaller the denture base area and the less influence the impression surface area will have on the stability and retention of the denture. Beresin and Schiesser, 1976.

The ultimate aim of the prosthodontics is to restore form, function and esthetics realizing the importance of the forces generated by various oral structures on the teeth, polished surfaces of the complete dentures and effect on the stability of complete dentures shed light on the Neutral Zone Technique. It has been shown that compromised retention, poor stability, phonetic problem, inadequate facial support, insufficient tongue posture/function increased gagging are all associated with functionally inappropriate arrangement of denture teeth and physiologically inadequate contours or volume of the denture base.

Several studies have compared denture fabricated by using neutral zone and conventional techniques, and it has been observed that neutral zone dentures are functionally more stable than conventional dentures, increase patient comfort and function, and experience minimum post-insertion problems.

However according to other authors, Nakashima et al. 1994 In a study using experimental dentures to load continuous pressure on the palate of the molar region of

rats, it was demonstrated that the low pressure (1.5 kPa) did not cause bone resorption, but higher pressure (3.4 and 4.9 kPa) caused RRR. It was concluded that osteoclastic bone resorption was a pressure threshold-regulated phenomenon with a lower threshold for continuous than for intermittent pressure. Kingsmill 1999 Prolonged pressure occludes the fine periosteal plexus of vessels, stimulating osteoclastic resorption by altering the local oxygen tension and reducing the pH. Ohkubo and Hosoi 1999 concluded that weighted dentures did not affect retention or stability. Patients were often dissatisfied due to compression of gingival tissues by the weighted mandibular denture. Zmyslowska et al. 2007 continuous pressure is more harmful than intermittent pressure. Jagadeesh and Patil 2013 In RRR, there is an osteoclastic activity, especially on the external surface of the crest of residual ridges.

Conclusion

In this case study, the patient was satisfied with the hollow denture over the other dentures, as she could open; close, talk, eat comfortably without dislodging of the dentures. Therefore this can be stated as novel method for fabrication of a hollow complete denture in a neutral zone.

References

1. The hollow maxillary complete denture: A modified technique, Michael O'Sullivan et al, J Prosthet Dent 2004;91:591-4.
2. Grunewald AH. Gold base lower dentures. J Prosthet Dent 1964;14:432-41.
3. Wormley JH, Brunton DA. Weighted mandibular dentures. J Prosthet Dent 1974;34:101-2.
4. Hurtado AJ. Internally weighted mandibular dentures. J Prosthet Dent 1988;60:122-3.
5. Beresin VE, Sciesser FJ. The neutral zone in Complete and Partial dentures. 2nd ed. CV Mosby: St Louis; 1978. p. 15-30.
6. Effect of weight change of mandibular complete dentures on chewing and stability: Ohkubo C, Hosoi T. A pilot study. J Prosthet Dent 1999;82:636-42.
7. Pragai G, Antal A. Load tolerance of the mandibular ridge and its extensions to the weight of the base plate of the total lower removable denture, in relation to alveolar involution. FogorvSz 1986;79:271-5.
8. Carlsson GE. Responses of jawbone to pressure. Gerodontology 2004;21:65-70.
9. Oki K, Sato T, Hara T, Minagi S. Histopathological changes in the tissues under a denture base in experimental osteoporosis with a non-pressure covering or bearing continuous pressure. J Oral Rehabil 2002;29:594-603.
10. Nakashima K, Sato T, Hara T, Minagi S. An experimental study on histopathological changes in the tissue covered with denture base without occlusal pressure. J Oral Rehabil 1994;21:263-72.
11. Brennon EF. Adding weight may promote retention of lower denture. Dent Surv 1973;49:30.
12. Holt RA Jr. A Hollow Complete lower denture. J Prosthet Dent 1981;45:4524.