

## Delayed replantation of an avulsed tooth– A case report

V. Bhavana<sup>1,\*</sup>, P.V. Durga Rao<sup>2</sup>, Aruna Kumari. G<sup>3</sup>, G. Leneena<sup>4</sup>

<sup>1</sup>Reader, <sup>2</sup>Professor, <sup>3,4</sup>Senior Lecturer, <sup>1</sup>Dept. of Conservative dentistry and Endodontics, Malla Reddy Dental College for Women, Suraram, Hyderabad, Telangana, <sup>2</sup>Dept. of Periodontics, Malla Reddy Dental College for Women, Suraram, Hyderabad, Telangana, <sup>3</sup>Dept. of Pedodontics, Malla Reddy Dental College for Women, Suraram, Hyderabad, Telangana, <sup>4</sup>Dept. of Conservative Dentistry and Endodontics, AIMST University, Kedah, Malaysia

**\*Corresponding Author:**

Email: drbhavana06@gmail.com

### Abstract

Dental injuries are very common and can occur at any age. Avulsion of tooth is a grievous injury and ranges from 1-16% among the traumatic injuries, of which maxillary anterior are the commonest. Replantation of the avulsed tooth is the treatment of choice, since it recovers the optimal function and esthetics, under ideal conditions and as the modern dentistry strives for the preservation of natural dentition. The present case report describes the management of an avulsed maxillary central incisor by replantation after 16 hours of extra-oral time in an 18 year old girl.

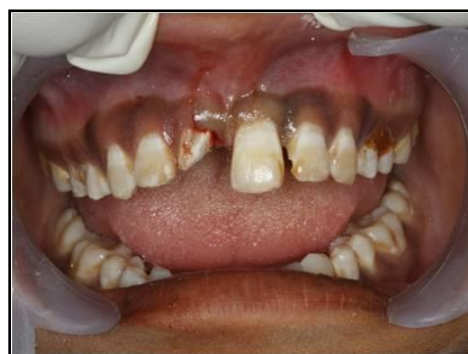**Keywords:** Avulsion, Replantation, Extra-oral time.

### Introduction

Tooth avulsion is defined as total displacement of the tooth out of its alveolar socket.<sup>(1)</sup> Avulsion is result a of traumatic injuries in the oro-facial region, and is classified as an injury of periodontal tissues, as well as extrusive, lateral, or intrusive luxation.<sup>(2)</sup> Traumatic injuries to newly erupted permanent anterior teeth are common during childhood and 0.5-16% of the 7-70 year-old group experience tooth avulsion.<sup>(1)</sup> Treatment of the avulsed tooth may include replantation of the tooth, which can restore the function and esthetic appearance at an early stage after injury.<sup>(1,3)</sup> The most important factor in determining its prognosis is viability of the remaining periodontal ligament cells on the root surface of a replanted tooth.<sup>(2,4)</sup> Degeneration of the periodontal ligament depends on several factors, such as trauma, extra-alveolar period, management of the root and storage medium.<sup>(2,4)</sup> But if appropriately managed, avulsed teeth with viable periodontal ligament which is re-implanted can remain functional for some years.<sup>(1,2,5)</sup> This is a case report which describes the management of an avulsed maxillary central incisor by replantation after 16 hours of extra-oral time in an 18 year old girl.

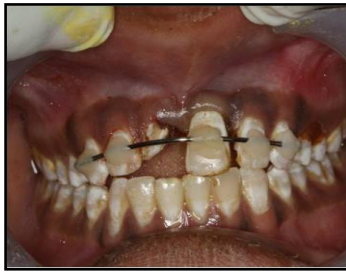### Case Report

An 18 year old girl reported to the department of Conservative Dentistry and Endodontics, with a chief complaint of trauma to the upper anterior teeth, due to fall from a tree. Extra-oral examination showed bruises on the chin, and intra-oral examination revealed avulsion of 21, and Ellis class 3 fractures of 11, (Fig. 1). The attendant (father) of the patient collected the avulsed tooth and stored in milk after the accident.

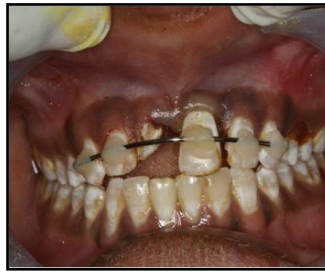

**Fig. 1: Preoperative Photograph**

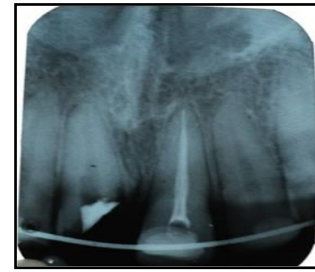
As the patient was young and was not interested in her tooth loss, replantation of the avulsed tooth was decided, to relieve her from psychological, cosmetic and functional trauma. Since the extra-oral time was more than 2 hours, root canal therapy was completed extra-orally by taking all the precautions to protect the viability of the periodontal ligament. The socket was irrigated with normal saline solution to remove the debris and the blood clots. The tooth was then placed in position inside the socket under local anesthesia, (Fig. 2). Composite splint was given followed by oral medication, (Fig. 3&4) in the form of Amoxicillin 500mg and metronidazole 400mg TDS and a combination of Ibuprofen 400mg and paracetamol 500mg TDS. The splint was removed after a period of 6 weeks and follow up radiographs were taken for one year, which revealed normal root configuration, intact periodontal ligament and without any periapical pathology, (Fig. 5). The adjacent fractured tooth was restored with cast post and core later, (Fig. 6).



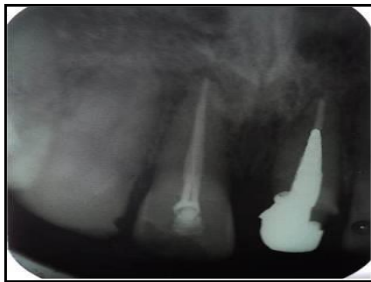
**Fig. 2: Raplanted Tooth**



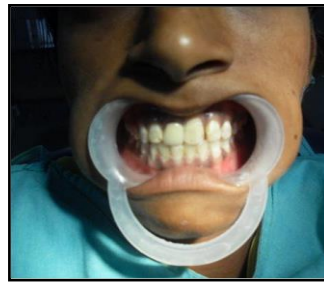**Fig. 3: Composite Splinting**



**Fig. 4: Postoperative Radiograph**



**Fig. 5: 1 Year Followup Radiograph**



**Fig. 6: 1 Year Followup photograph**

## Discussion

Tooth avulsion is the most serious of all dental injuries. The maxillary central incisors are the most prone teeth for avulsion, due to traumatic sports and automobile injuries. The prognosis of replantation of tooth depends on the measures taken at the place of accident or the time immediately after the avulsion.<sup>(5)</sup> Standard protocols must be followed for patients with dental trauma, i.e., examination of the avulsed tooth, cleaning of the region and the tooth, replantation of the tooth, splinting of the tooth, appropriate medication and follow-up. Many factors are involved: extra alveolar time, where the tooth was kept, and clinical procedures for the treatment of the avulsed tooth.<sup>(6)</sup> One of the most important factors for successful healing of the Periodontal membrane of a replanted tooth is the length of the extra alveolar time.<sup>(7,8)</sup> Keeping the avulsed tooth in air causes drying of the periodontal membrane and necrosis of the periodontal membrane cells.<sup>(7)</sup> The teeth replanted from 6 hrs to 48 hrs after avulsion and treated endodontically are shown to be clinically functional for a number of years.<sup>(8)</sup> The ideal extra-oral time is 20 mins, and the maximum extra-oral time, as reported in literature, is 48 hours.<sup>(8)</sup>

In this case, since the extra oral time was more than 16 hrs, it was possible that the tooth had lost its vitality, hence root canal treatment was completed prior to the replacement of tooth in the socket. In such cases of delayed replantation, the use of adequate media for storage and transportation of the avulsed teeth might improve the prognosis considerably.<sup>(9)</sup> Prognosis improved in this case, as the tooth was stored in milk soon after the accident. The presence of mind of patient's father in preserving the avulsed tooth in milk is

commendable and reflects the of rural folk's increased awareness towards dental practices. Milk has a physiologic osmolality and contains markedly fewer bacteria than does saliva.<sup>(7)</sup> Milk, saliva, saline, HBSS, propolis, Viaspan, and recently coconut water are being used as storage media, and all of these agents were investigated for their ability to maintain cell viability.<sup>(10,11)</sup> Favourable outcome of the tooth implies, asymptomatic, normal mobility, normal percussion sound, no radiographic evidence of resorption or periradicular osteitis and normal lamina dura. An appropriate treatment plan after an injury is of utmost important for a good prognosis.<sup>(12)</sup> We have achieved successfully objectives like acceptable esthetic appearance, occlusal function, and favorable healing. Patient was asymptomatic and fully satisfied with the treatment with a follow up of one year.

## Conclusion

In cases of avulsed tooth with extended extra oral time, although the risk of progressive replacement resorption and subsequent tooth loss is quite high, Replantation can be tried, as the technique seems to have advantage of maintaining aesthetic appearance and occlusal function. A Long term follow up with regular recall visits may confirm the success of the treatment. The one year follow up, in this case, has shown favourable healing and successful outcome of the treatment.

## References

1. Shiu-yin C, Ansgar CC. Replantation of an Avulsed Incisor After Prolonged Dry Storage: A case report. *J Can Dent Assoc.*2002;68:297-300.

2. Singla A, Garg S, Dhindsa A, Jindal SK. Reimplantation: Clinical Implications and Outcome of Dry Storage of Avulsed Teeth. *J Clin Exp Dent*.2010;2:e37-41.
3. Parolia A, Kundabala M, Shetty N, Manuel ST. Delayed replantation: Can it be a success? *Kathmandu University Medical Journal*.2008;6:497-501.
4. Zohreh K, Mahshid S, Ladan M. Delayed tooth replantation after traumatic avulsion: A case report. *Int Endod J* 2008;3:86-89.
5. Flores MT, Andersson L, Andreasen JO, Bakland LK, Malmgren B, Barnett F. Guidelines For The Management Of Traumatic Dental Injuries.II.Avulsion Of Permanent Teeth. *Dental Traumatology*.2007;23:130-136.
6. Erica LF, Flares BF, Gisele MC, Denise PL. Dental avulsion, from dental replantation to dental implant: A Case report with a 20-year follow-up. *Brazilian J Dent Traumatology*.2009;1:13-19.
7. Blomlof L, Lindskog S, Andersson L. Storage of Experimentally Avulsed Teeth in Milk Prior to Replantation. *J Dent Res*.1983;62:912-916.
8. Adil NF, Ahmed SS, Jindal MK, Arshad SH. Delayed Replantation of Avulsed Teeth. *J Indian Soc Pedod Prevent Dent*. 2007;Supplement:S17-19.
9. Sonoda CK, Wilson RP, Sonia RP, Sottovia AD, Okamoto T. Tooth replantation after keeping the avulsed tooth in oral environment: Case report of a 3-year follow-up. *Dental Traumatology*.2008;24:373-376.
10. Gopikrishna V, Parvinder SB, Venkateshbabu N, Toby T, Kandaswamy D. Comparison of coconut water, propolis, HBSS, and milk on PDL cell survival. *J Endodont*. 2008;34:587–589.
11. Thomas T, Gopikrishna V, and Kandaswamy D. Comparative evaluation of maintenance of cell viability of an experimental transport media “coconut water” with Hank's balanced salt solution and milk, for transportation of an avulsed tooth: An in vitro cell culture study. *J Conserv Dent*. 2008;11:22–29.
12. Bakland LK, Andreasen JO. Dental traumatology: Essential Diagnosis and Treatment planning. *Endodontic Topics*.2004;7:14–34.