

Rhinoscleroma- a case report

Anas Sami Siddiqui¹, Naeem Ahmad^{2*}, Adeeba Khan³, Arpita Khare⁴, Taseer Bashir⁵

^{1,3}Dental Surgeon, ²Reader, Dept. of Prosthodontics, ⁵Senior Lecturer, Dept. of Oral Medicine, Career Post Graduate Institute of Dental Sciences, Lucknow, Uttar Pradesh, ⁴Dental Surgeon, Saraswati Dental College, Lucknow, Uttar Pradesh

***Corresponding Author:**

Email: naeem_bds@yahoo.co.in

Abstract

Rhinoscleroma (RS) is defined as a specific disease of chronic nature involving upper respiratory passages and nasal area and is caused by *Klebsiella rhinoscleromatis* bacilli. The diagnosis of RS is based on the identification of mickulicz cells (MCs). These cells are mostly seen during granulomatous phase & absent during the sclerotic phase. The present case report highlights the diagnosis and management of Rhinoscleroma.

Keywords: Rhinoscleroma, Early diagnosis, Mickulicz cells, Diagnostic criteria

Introduction

Rhinoscleroma (RS) is a chronic granulomatous disease affecting the upper respiratory tract. It is an endemic disease especially in regions of Egypt.^(1,2) The disease mainly occurs in second & third decades of life especially among female subjects.⁽³⁻⁵⁾

Early diagnosis & treatment of RS is crucial in avoiding its progression & destruction to body.⁽⁶⁻⁸⁾ The present case report discusses the detailed pathological changes of RS in order to identify the early histopathological diagnostic features of the disease when the Mickulicz cells are missing.

Case Report

A 45 yr old female patient reported to the Department of Oral Medicine and Radiology, Career Post Graduate Institute of Dental Sciences, Lucknow with a chief complaint of pain in the right upper back tooth region since two weeks. History of presenting illness revealed that the patient was asymptomatic six months back then she felt mild pain and noticed swelling over right maxillary area with nasal discharge.

Pain aggravated during meal and subsided after medication. Swelling gradually increased in size.

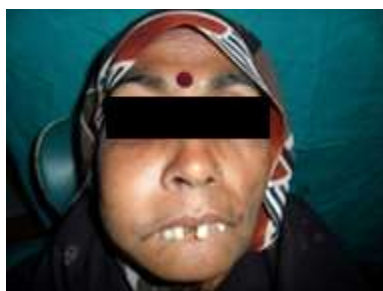

Fig. 1: Extra-oral view

Initially there was a watery nasal discharge associated with common cold only then it started with sneezing, coughing and during meal. Patient also felt nasal obstruction (difficulty in breathing) during

sleep/lying down position. There was no past relevant dental or any kind of medical ailment.

Extra-oral examination: Face was bilaterally asymmetrical. Right maxillary swelling was present involving Zygoma & lateral part of the right nose. Swelling was bony hard with tenderness.

Examination of Extraoral Swelling:

Inspection: An Extraoral diffuse swelling was present on right side of the mid-face region involving zygoma, lateral part of right nose. Superiorly upto the lower border of infra orbit. Inferior upto the inferior border of mandible. Posterior 1-2 cm in front of tragus. Anteriorly upto the ala of nose. Surface was smooth, skin over swelling was normal.

Palpation: All the Inspectory findings are confirmed. Consistency of the swelling was hard. No tenderness was present. No surface sinus and discharge was present

Intraoral examination:

Inspection: A solitary diffuse pink colored swelling was present in posterior region of the right maxilla.

Palpation: Swelling was tender. Consistency was hard. Surface of swelling was smooth. Reducibility and compressibility were absent.

Provisional diagnosis: Cystic Lesion/ Bony Tumor

Differential Diagnosis: Ameloblastoma, Dentigerous Cyst & Carcinoma Involving maxillary Sinus

Investigations: Radiograph, OPG & Biopsy were advised.

Radiographic interpretation: OPG showed well defined radiolucency seen in right maxillary sinus. Extension of radiolucency seen the lateral border of the maxillary sinus to medial surface of the maxillary sinus. Generalized horizontal bone loss was seen, radiolucency was seen in apical region of 13,14.

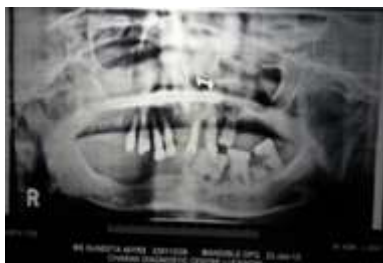

Fig. 2: OPG view

Radiographic diagnosis: Maxillary sinusitis

Biopsy Report: A multiple section study was done. Section showed few bone trabeculae and fibrous connective tissue. The latter showed infiltration by number of lymphocytes. Several multinucleated giant cells were seen in between the inflammatory exudates, there were masses of histolytic and macrophages with abundant clear or vacuolated cytoplasm. The cells had ovoid vesicular nuclei with small foci of necrosis. There were no signs of any kind of malignant change.

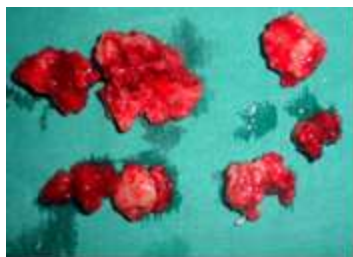


Fig. 3: Biopsy sample

Definitive diagnosis: Rhinoscleroma

Treatment Plan: Patient was referred to oral surgery department for removal of lesion.

Palliative therapy: The treatment for Rhinoscleroma was started with a dose of long-term antimicrobials which was followed by surgical intervention. Cephalosporins and clindamycin was started to eliminate sclerotic lesions which responded to the treatment. The choice of long-term antibiotic therapy was decided with patient's gender & age.

Surgical Care: As the patient was also having laryngeal obstruction of the second degree (granulomatous stage) hence tracheostomy was also done. Extensive granulomatous lesions were excised for quick recovery. Plastic surgery was also performed under GA as imperforation remained in the nasal cavity & pharynx.

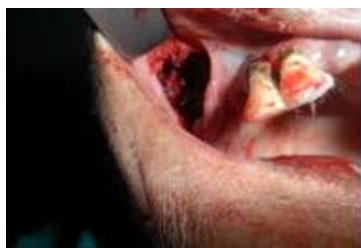

Fig. 4: Post-surgical view

Recall visit: Patient was recalled after 01 month and the healing were found to be uneventful.

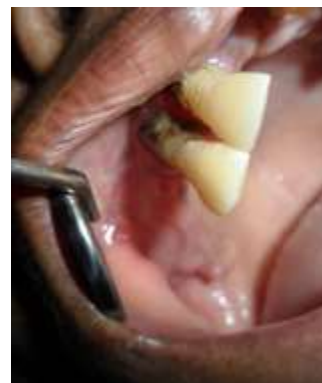

Fig. 5: Post-surgical view after 02 months

Discussion

Rhinoscleroma is defined as a chronic infection affecting nose & upper respiratory passage region. It is considered as a rare disease; hence the national and international epidemiological data is limited. Identification of the MCs is the basis of its diagnosis. However, detection of MCs in H & E stained sections is mostly challenging in either the early catarrhal or the late fibrotic stage of the disease.⁽⁵⁾

Iyengar et al⁽⁶⁾ reported that plasma cells & lymphocytes are present along with MCs in all RS situations while the eosinophils were rarely seen in only three cases while the Russel bodies which is a frequent histological finding in RS are nothing but modified plasma cell.⁽⁷⁾ This data support our proposed importance of plasma cells as a reliable diagnostic finding of RS. The exact reason for dominance of plasma cells compared to lymphocytes in cases of RS is still unclear.

Hence Rhinoscleroma is still a diagnostic and therapeutic challenge due to its chronic course, need for prolonged treatment and repeated relapses.⁽⁸⁾

Conclusion

The dominance of these plasma cells & the absence of eosinophils in biopsy samples obtained from subjects suffering from chronic nasal symptoms should raise the possibility of RS regardless of the detection of MCs especially in remote endemic areas.

Source of support: None

Conflict of interest: Nil

References

1. Chan TV, Spiegel JH. Klebsiella rhinoscleromatis of the membranous nasal septum. *J Laryngol Otol* 2007;121:998-1002.
2. Fernandez-Vozmediano JM, Armario Hita JC, Gonzalez Cabrerizo A. Rhinoscleroma in three siblings. *Pediatr Dermatol* 2004;21:134-8.

3. Montone KT. Infectious diseases of the head and neck: a review. *Am J Clin Pathol* 2007;128:35-67.
4. Von-Frisch A. Zur. Aetiologie des Rhinoscleroms. *Wien Med Wochenschr* 1882;32:96-7.
5. Hazem A. Gaafar, Alaa H. Rhinoscleroma: An updated experience through the last 10 years. *Acta Oto-Laryngologica* 2011;131:440-6.
6. Iyengar P, Laughlin S, Keshavjee S. Rhinoscleroma of the larynx. *Histopathology* 2005;47:224-5.
7. Berron Q, Guo W, Chen X. Rhinoscleroma: a retrospective study of pathologic and clinical features. *J Otolaryngol Head Neck Surg* 2011;40:167-74.
8. Zhong S, Tiba M, Salman M, Othman H. Clinical, radiological and pathological study of 88 cases of typical and complicated scleroma. *Clin Respir J* 2011;5:112-21.
9. Bailhache A, Dehesdin D, Francois A. Rhinoscleroma of the sinuses. *Rhinology* 2008;46:338-41.