

## Management of a tooth with talon cusp having immature apex

Shipra Nangalia Maitin<sup>1,\*</sup>, Nitin Maitin<sup>2</sup>, Sandeep Kaushik<sup>3</sup>

<sup>1</sup>Senior Lecturer, Dept. of Pedodontics & Preventive Dentistry, <sup>2</sup>Reader, Buddha Institute of Dental Sciences & Hospital, Patna, Bihar, <sup>3</sup>Senior Lecturer, Dept. of Conservative Dentistry & Endodontics, Teerthankar Mahaveer Dental College & Research Centre, Moradabad, Uttar Pradesh

**\*Corresponding Author:**

**Shipra Nangalia Maitin**

Senior Lecturer, Dept. of Pedodontics & Preventive Dentistry, Buddha Institute of Dental Sciences & Hospital, Patna, Bihar  
Email: shipranangalia@gmail.com

---

### Abstract

Talon cusp, which is a rare occurrence involving an extra cusp often on the palatal aspect of maxillary anterior teeth can be troublesome to the patient and may require professional intervention. This report describes the endodontic therapy of a tooth with talon cusp having an immature apex.

---

### Introduction

A talon cusp, also known as an "eagle's talon", is an extra cusp on an anterior tooth. The term refers to the same condition as dens evaginatus, but the talon cusp is the manifestation of dens evaginatus on anterior teeth. This anomalous structure is composed of normal enamel and dentin and either has varying extensions of pulp tissue into it or is devoid of a pulp horn. Clinical manifestations of this anomaly have led the Talon cusp to be described in many different ways: exaggerated cingula, cusp-like hyperplasia, accessory cusp, supernumerary cusp, interstitial cusp, and palatal accessory cusp<sup>1,2</sup>.

The aetiology of talon cusp is not well understood, but appears to have both genetic and environmental components<sup>3</sup>. This rare anomaly is thought to originate during the morphodifferentiation stage of tooth development and appears to be more prevalent in patients with Rubinstein-Taybi syndrome, Mohr syndrome (oral-facial-digital syndrome, type II), Sturge-Weber syndrome (encephalotrigeminal angiomas), or incontinentia pigmenti achromians, Alagille's Syndrome<sup>4</sup>.

The existence of pulpal tissue in a talon cusp has been of interest because of potential treatment difficulties. This case presentation reports on the existence of pulpal tissue in talon cusps affecting permanent left maxillary central incisor and discusses its treatment considerations.

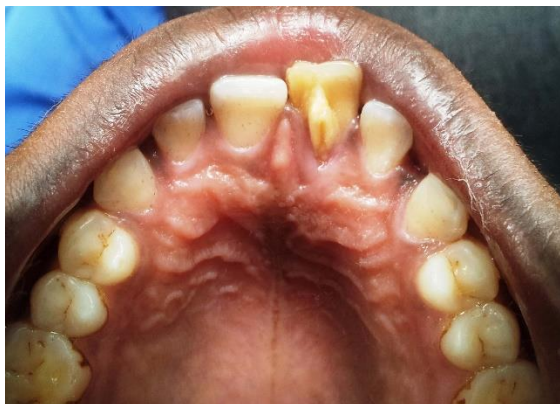### Case Presentation

An eleven year old mentally disabled male patient reported to outpatient department of Veena Dental Clinic, Patna, India with a chief complaint of pain and difficulty in biting in the upper frontal region of the jaw since last fifteen to twenty days having a history of trauma in the same region four years back.

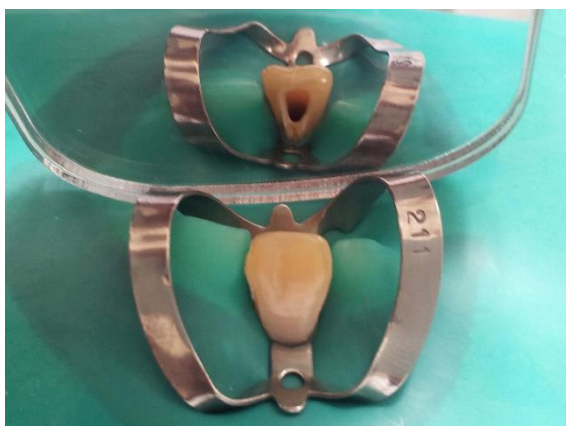Clinical examination revealed discoloured 21 with a supernumerary cusp on the palatal aspect, suspicious of a talon cusp (Fig. 1), Vitality test was performed

which presented the tooth to have a nonvital pulp because of previous trauma; all other hard and soft tissues appeared to be normal. A thorough medical history and general examination of the patient was performed to rule out any syndromic association. Intraoral radiograph was advised for the concerned tooth which revealed periapical osteitis associated with blunderbuss canal. A treatment plan was constituted which consisted of grinding of the supernumerary cusp followed by apexification in one visit and prosthodontic restoration.

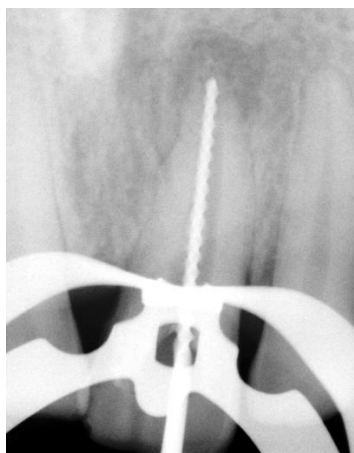
The supernumerary cusp was grounded using a pear shaped diamond bur, access was gained in the same appointment (Fig. 2), working length determination done using electronic method and confirmed radiographically (Fig. 3). Shaping and cleaning of the root canal was carried out using conventional techniques along with ultrasonic activation with warm 1% Sodium Hypochlorite. Calcium hydroxide Iodoform paste (Metapex, MetaBiomed) was used as an intracanal medicament which was left in place for two weeks. Apexification was performed by creating an apical plug of White Mineral Trioxide Aggregate (ProRoot MTA, Dentsply Tulsa), the patient was recalled the second day for definitive obturation of the remaining canal using thermoplastic gutta-percha technique and permanent sealing of the access cavity (Fig. 4) followed by metal ceramic crown.



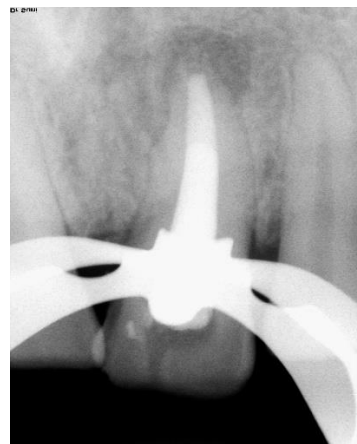
**Fig. 1: Supernumerary cusp on the palatal aspect of 21 suggestive of a Talon cusp**



**Fig. 2: Access opening on the palatal aspect of 21 after grinding of the Talon cusp**



**Fig. 3: Working length determination**



**Fig. 4: Post-operative radiograph showing apical plug of MTA and obturation**

### Discussion

Talon cusp has been reported more than 90% occurrence in maxilla-both for the primary and permanent dentitions<sup>5</sup>. Different studies have been conducted in the past for the prevalence of talon cusp in humans with inconsistent rates<sup>6</sup>. Clinical features of talon cusp varies with problems related to occlusion, speech and aesthetics. Associated grooves may lead to plaque retention leading to dental caries. If cusp is severely worn off due to masticatory forces, it may lead to pulpal exposure.

Early diagnosis of talon cusp is important, and, in most cases, a definitive conservative or endodontic treatment. The conservative treatment includes the removal and restoration of the carious grooves, gradual reduction of the talon over 6- to 8-week intervals to allow time for deposition of reparative dentine for pulpal protection. Under certain conditions, endodontic methods following complete reduction of the cusp and opening the pulp chamber can be used. The proper endodontic treatment in such cases is direct pulp capping or pulpotomy for an immature tooth or root canal treatment for mature tooth<sup>7</sup>.

On radiographic examination, trace talon has the typical V-shaped radiopaque appearance as for type 1, true talon and type 2, semi talon or tubercle-like structure, originating from the cervical third of root<sup>8</sup>. The talon cusp presented in this case report coincides with the definition for type 1, true talon.

In the present case, Mineral Trioxide Aggregate (MTA) was used for root end closure. MTA has excellent sealing properties, actively promotes hard-tissue formation, is biocompatible, has higher mechanical strength and setting of MTA is not adversely affected by presence of moisture. The use of MTA to achieve root end closure has many advantages over various other traditional materials and techniques<sup>8</sup>.

**References**

1. Dinesh Rao B, Hegde S. A talon cusp on fused teeth associated with hypodontia: Report of a unique case. *Eur J Dent* 2010;4:75- 80.
2. King NM, Tsai JS, Wong HM. Morphological and numerical characteristics of the Southern Chinese dentitions. Part I: Anomalies in the permanent dentition. *Open Anthropol J* 2010;3:54-64.
3. Davis PJ, Brook AH. The presentation of talon cusp: diagnosis, clinical features, associations and possible aetiology. *Br Dent J* 1986;160(3):84-8.
4. Güngör HC, Altay N, Kaymaz FF. Pulpal tissue in bilateral talon cusps of primary central incisors: report of a case. *Oral Surg Oral Med Oral Pathol Oral Radiol Endod.* 2000 Feb;89(2):231-5.
5. Karjodkar FR, Gupta A. Mandibular talon cusp: a case report. *Oral Surg Oral Med Oral Pathol Oral Radiol Endod.* 2007 May;103(5):e86-7.
6. Chinni S, Nanneboyina M, Ramachandran A, Chalapathikumar H. A facial talon cusp on maxillary permanent central incisors. *J Conserv Dent.* 2012 Jan;15(1):87-8.
7. Shetty P, Xavier AM. Management of a talon cusp using mineral trioxide aggregate. *Int Endod J.* 2011 Nov;44(11):1061-8.
8. Hattab FN, Yassin OM, Al-Nimri KS. Talon cusp in permanent dentition associated with other dental anomalies: review of literature and reports of seven cases. *J Dent Child* 1996;63:368-76.