

Content available at: <https://www.ipinnovative.com/open-access-journals>

IP Annals of Prosthodontics and Restorative Dentistry

Journal homepage: <https://www.aprd.in/>

Case Report

Immediate implant placement using socket shield technique followed by delayed implant loading in maxillary canine and premolar region: Two case reports with a follow-up period of 4 years

Shruti Potdukhe ^{1*}¹MGM Dental College and Hospital, Navi Mumbai, Maharashtra, India

ARTICLE INFO

Article history:

Received 30-03-2024

Accepted 28-06-2024

Available online 16-08-2024

Keywords:

dental implant loading

Ceramic

Partial extraction therapy

Root membrane technique

Partial root retention

ABSTRACT

Introduction: Tooth extraction leads to continuous bone resorption causing the collapsed bone wall. To prevent bone loss and buccal wall collapse in the esthetic areas the socket shield technique was developed.

Case description: Two cases of delayed implant loading of immediately placed implant with socket shield technique in the maxillary anterior and premolar region with a follow-up period of four years are described.

Conclusion: After a follow-up period of four years, both cases depicted higher survival and success rates, better patient satisfaction, and higher implant stability.

Clinical significance: Implant-fixed prosthetic rehabilitation of the non-restorable tooth using the socket shield technique can be one of the conservative, successful and durable treatment outcome for esthetic as well as non-esthetic zones.

This is an Open Access (OA) journal, and articles are distributed under the terms of the [Creative Commons Attribution-NonCommercial-ShareAlike 4.0 License](https://creativecommons.org/licenses/by-nc-sa/4.0/), which allows others to remix, tweak, and build upon the work non-commercially, as long as appropriate credit is given and the new creations are licensed under the identical terms.

For reprints contact: reprint@ipinnovative.com

1. Introduction

Due to a loss of sensory stimulus and blood flow from the periodontal ligament, tooth extraction results in persistent residual alveolar bone resorption. This reduces bone mass and collapses the buccal plate in the maxillary arch, jeopardising the insertion of dental implants.^{1,2} To prevent buccal bone loss, Hurzeler et al developed the socket-shield concept as a predictable and reliable technique for immediate implant placement in the esthetic zone region to preserve the remaining natural root and bone loss.³⁻⁷ He explained how the immediate implant placement technique was used in the region of a non-restorable endodontically treated tooth having a healthy root which was sectioned mesiodistally into buccal and palatal root halves, followed by extraction of the palatal half and preservation of the buccal half to maintain the attachment to bundle bone

and vascularity at implant surgical site.³⁻⁵ Many authors have reported the socket shield concept as a successful predictable technique for rehabilitation in the esthetic zones with immediate implant placement.⁶⁻¹³

Two cases of delayed implant loading of immediately placed implants using the socket shield technique in the maxillary anterior and premolar regions are described in this article having a four-year follow-up period.⁶⁻¹³

2. Case Presentation

2.1. Case report one

A 35-year-old male patient reported with the chief complaint of a fractured root canal treated right maxillary canine since 3 years and wanted a prosthesis.¹³ The relevant clinical findings were Ellis class III fracture with the right maxillary canine (Figure 1). A cone-beam computed tomography (CBCT) scan was taken which showed a residual bone width of 7.5 mm and bone height of 13 mm in

* Corresponding author.

E-mail address: shrutispotdukhe@gmail.com (S. Potdukhe).

the region of interest (Figure 2). Accordingly, the treatment planned was immediate implant placement of 4 mm X 13 mm dimension using socket shield technique followed by delayed implant loading. Detailed patient information sheet and written informed consent were obtained from the patient.

The implant surgical site was prepared and cleaned with betadine solution and saline. The level of coronal structure of the canine was at the gingival level, using a size 2 peeso reamer the entire gutta-percha was removed from the root canal space. Using a long shank bur the root was sectioned vertically in a mesiodistal direction with the centre at the access opening hole into buccal and palatal halves,⁷ followed by breaking of PDL fibres with the aid of periosteal elevator for atraumatic extraction of the palatal half with forceps.¹ The buccal half was reduced to bone level and kept 2mm thick using a long round end straight fissure bur thus forming a buccal shield (Figure 3). The osteotomy was done sequentially palatal to the buccal shield engaging the palatal bone for placement of a 4 mm x 13mm dimension DIO Implant (Figure 4). The jumping distance between the implant and the buccal shield was filled with 50% autogenous bone graft and 50% anorganic bovine bone mineral (Bio-oss) and the site was sutured with Vicryl 2.0. To prevent the chances of implant failure due to the lesser amount and less denser bone the second stage surgery was performed after three months of the healing period, for the placement of the temporary abutment and provisional (Figure 5). After two weeks of recall, a customised impression coping was used for making a closed tray implant-level impression using addition silicone (Figure 6). The cement-retained CAD lithium disilicate implant crown was fabricated to enhance the esthetic, enhance the crown coverage and eliminate the screw access hole (Figure 7).

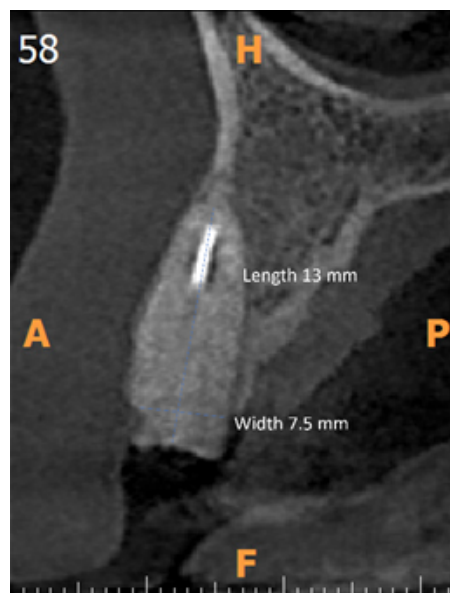


Figure 2: Pre operative radiograph of 13

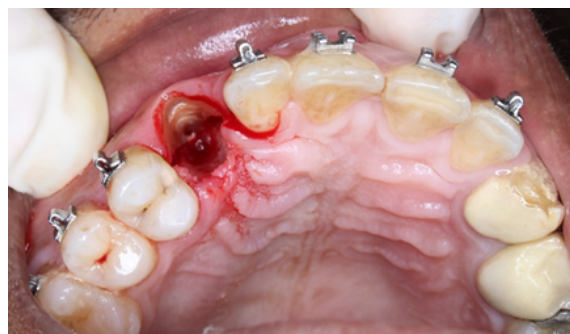

Figure 3: Sectioning of root followed by removal of palatal half and preparation of buccal shield with right maxillary canine

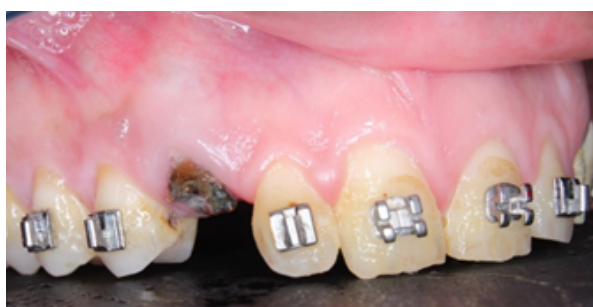

Figure 1: Pre operative intraoral picture showing Ellis class III fracture with right maxillary canine

2.2. Case report two

A 42-year-old female patient reported with the chief complaint of a fractured root canal treated maxillary right first premolar since eight months.¹⁴ The relevant

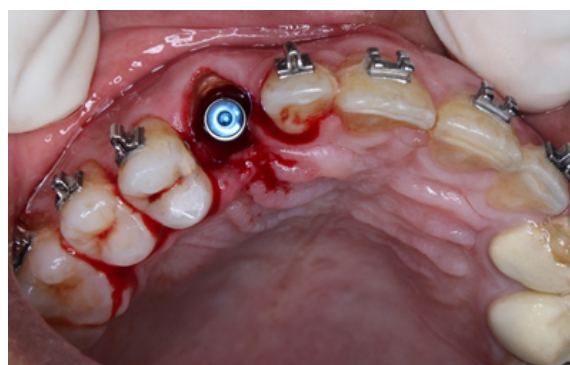


Figure 4: Immediate implant placement in right maxillary canine region

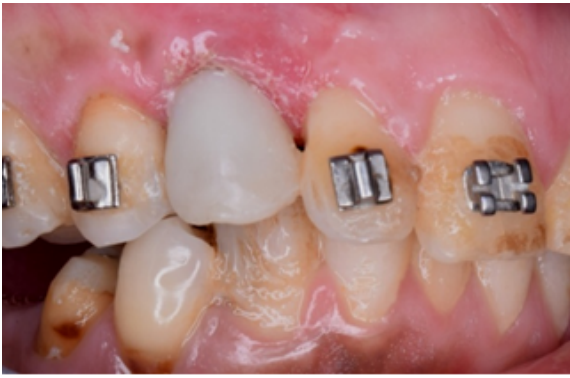

Figure 5: Provisionalisation with right maxillary canine

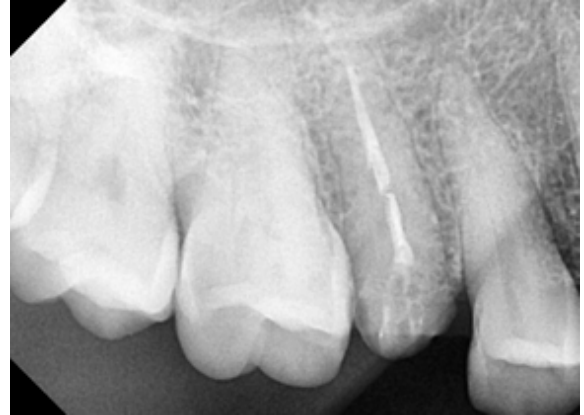

Figure 9: Pre operative radiograph of 15

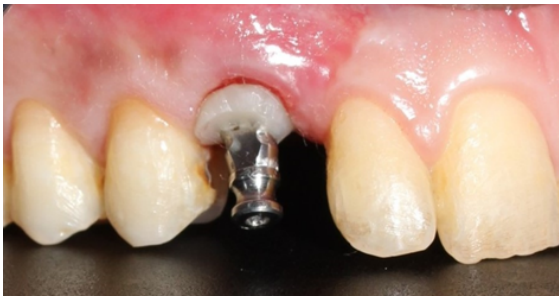

Figure 6: Customised impression coping

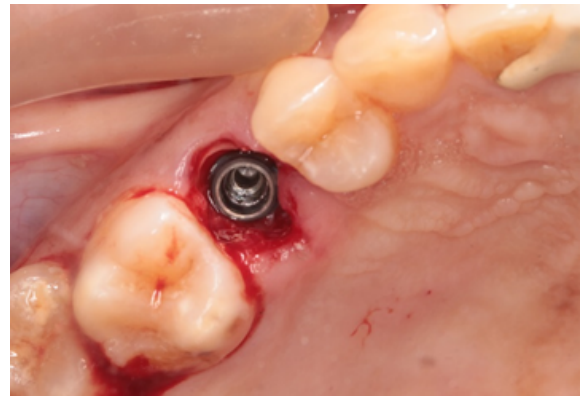


Figure 10: Preparation of buccal shield followed by immediate implant placement with right maxillary premolar region

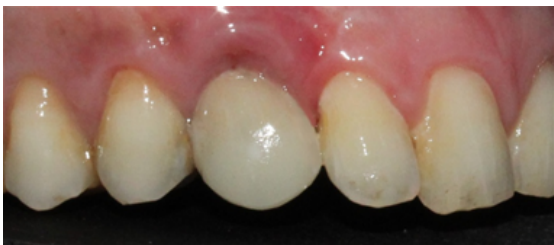

Figure 7: Cement-retained lithium disilicate implant prosthesis with right maxillary canine

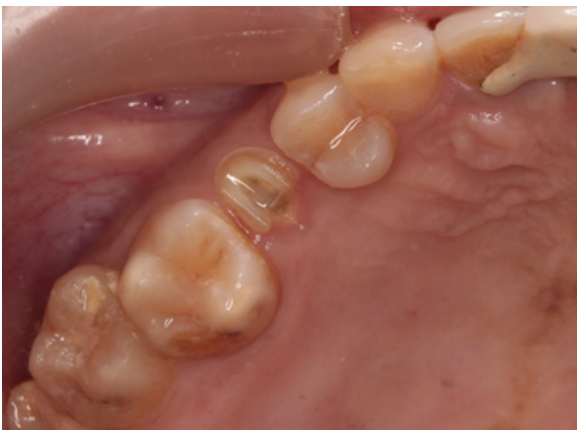

Figure 8: Preoperative intraoral picture showing Ellis Class III fracture with right maxillary second premolar

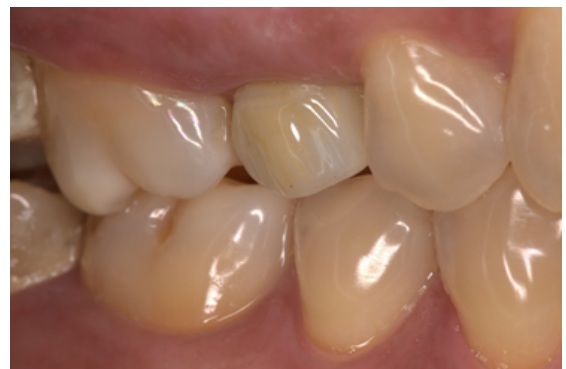

Figure 11: Customised screw-retained zirconia implant crown on right maxillary premolar

clinical findings were Ellis class III fracture, CBCT scan showed bone width of 6.5 mm and bone height of 12mm, (Figure 8) so the treatment planned was immediate implant placement of 4 X 10 mm dimension using socket shield technique followed by delayed implant loading (Figure 9). The surgical procedure included decoronation, root sectioning, implant placement, grafting the jumping distance and suturing followed by second-stage surgery and implant-level impression (Figure 10). For implant prosthesis customised screw-retained zirconia implant crown was screwed to the implant and canine-guided occlusion was given (Figure 11). Both cases were recalled immediately, after one week, after three months and annually for clinical and radiographic evaluation.²

To assess the implant stability ostell device was used and both implants showed higher implant stability of 70 implant stability quotient (ISQ) value.² The probing depth and bleeding on probing and radiographic assessment of bone loss were used to measure periimplantitis and both implants showed no signs of peri-implantitis. No technical and biological complications were reported for both implants.³ The visual analog scale was used to measure patient satisfaction and patients were highly satisfied with the implant prosthesis during the follow-up period of 4 years.⁴

3. Discussion

Hurzeler et al developed the socket-shield concept as a reliable technique to preserve the buccal wall collapse and bone loss in the esthetic areas for immediate implant placement.^{6–15} Immediate implant placement in the region of a non-restorable endodontically treated tooth having a healthy root which was sectioned mesiodistally into buccal and palatal root halves, followed by extraction of the palatal half and preservation of the buccal half to maintain the attachment to bundle bone and vascularity at implant surgical site.^{8–10,15} Many authors reported the socket shield technique as a predictable treatment for maxillary arch immediate implant placement.^{6,12–19} Two cases of delayed implant loading of immediately placed implants using the socket shield technique in the maxillary anterior and premolar regions are described in this article having a four-year follow-up period.^{6,11–14,19}

Preservation of the natural tooth and conservation of alveolar bone is always better than the total artificial replacement.^{7,11,13,19} Extraction followed by delayed implant placement, three-unit fixed dental prosthesis, adhesive bridges, and fibre-reinforced prosthesis are various treatment options for non-restorable, coronally fractured teeth in the maxillary arch.²⁰ However, tooth extraction without socket preservation can cause a collapse of the buccal wall, three-unit fixed dental prosthesis causes intentional tooth preparation of vital abutment tooth, adhesive bridges can debond after a certain time and

fibre-reinforced prosthesis can only be used as a long-term provisional.²⁰

Hurzeler et al presented the idea and documented a successful socket shield procedure with immediate implant placement in a beagle dog.^{6,7,9,12–15,19} Gluckman et al carried out a retrospective analysis of the implants in the esthetic and posterior areas placed using the socket shield technique.^{6,7,10–15,19} Atieh et al, carried out the research and showed favourable results for the buccal bone plate, peri-implant marginal bone levels, and aesthetics around the implants placed using the socket shield technique.^{6,7,10–15,19} Hang et al concluded that the modified socket shield technique has higher survival, stability and lower complication rates.¹⁰ Retained apical root fragments, mobility of buccal shield, failure in osseointegration of the implant, and loss of graft material are certain reported disadvantages of the socket shield technique.^{6–8,10–15,19}

Two cases of delayed implant loading of immediately placed implants using the socket shield technique in the maxillary anterior and premolar regions were described as having a successful outcome at a four-year follow-up period. However, for more conclusive outcomes on the survival and success rates, clinical trials with longer follow-up periods can be carried out.^{6,7,10–15,19}

4. Conclusion

After a four-year follow-up period, both patients showed higher implant stability, high survival and success rates, and better patient satisfaction. One of the most conservative, effective, long-lasting treatment options for non-restorable teeth is socket shield technique-based implant-fixed prosthetic rehabilitation.

5. Source of Funding

None.

6. Conflict of Interest


None.

References

1. Sharma SD, Vidya B, Alexander M, Deshmukh S. Periotome as an Aid to Atraumatic Extraction: A Comparative Double Blind Randomized Controlled Trial. *J Maxillofac Oral Surg.* 2015;14(3):611–5.
2. Potdukhe S, Iyer J, Nadgere J. Evaluation of implant stability and increase in bone height in indirect sinus lift done with the osseodensification and osteotome technique: A systematic review and meta-analysis. *J Prosthet Dent.* 2023;S0022-3913(23):00278–0. doi:10.1016/j.prosdent.2023.04.021.
3. Ramanauskaite A, Juodzbalsys G. Diagnostic Principles of Peri-Implantitis: a Systematic Review and Guidelines for Peri-Implantitis Diagnosis Proposal. *J Oral Maxillofac Res.* 2016;7(3):8. doi:10.5037/jomr.2016.7308.
4. Voutilainen A, Pitkääho T, Kvist T, Vehviläinen-Julkunen K. How to ask about patient satisfaction? The visual analogue scale is less vulnerable to confounding factors and ceiling effect than a symmetric Likert scale. *J Adv Nurs.* 2016;72(4):946–57.

5. Bartee B. Extraction site reconstruction for alveolar ridge preservation. Part 1: rationale and materials selection. *J Oral Implantol.* 2001;27(4):187–93.
6. Sharma A, Maheshwari K, Tiwari B, Naik D. Socket shield technique: An unconventional method for immediate implant placement - A review. *Natl J Maxillofac Surg.* 2022;13(1):24–35.
7. Nguyen VG, Flanagan D, Syrbu J, Nguyen TT. Socket shield technique used in conjunction with immediate implant placement in the anterior maxilla: a case series. *Clin Adv Periodontics.* 2020;10(2):64–8.
8. Abd-Elrahman A, Shaheen M, Askar N, Atef M. Socket shield technique vs conventional immediate implant placement with immediate temporization. Randomized clinical trial. *Clin Implant Dent Relat Res.* 2020;22(5):602–11.
9. Hurzeler MB, Zuhr O, Schupbach P, Rebele SF, Emmanouilidis N, Fickl S, et al. The socket-shield technique: a proof-of-principle report. *J Clin Periodontol.* 2010;37(9):855–62.
10. Gluckman H, Salama M, Toit JD. Partial Extraction Therapies (PET) Part 1: Maintaining Alveolar Ridge Contour at Pontic and Immediate Implant Sites. *Int J Periodontics Restorative Den.* 2016;36(5):681–7.
11. Gluckman H, Salama M, Toit JD, J. A retrospective evaluation of 128 socket-shield cases in the esthetic zone and posterior sites: Partial extraction therapy with up to 4 years follow-up. *Clin Implant Dent Relat Res.* 2018;20(2):122–9.
12. Abdelraheem AM, El-Feky A, Hosny AM. Socket shield technique versus sticky bone in immediate dental implant in esthetic zone. *Al-Azhar J Dent Sci.* 2022;25(4):445–53.
13. Dayakar MM, Waheed A, Bhat HS, Gurpur PP. The socket-shield technique and immediate implant placement. *J Indian Soc Periodontol.* 2018;22(5):451–5.
14. Singh M, Kumar L, Anwar M, Chand P. Immediate dental implant placement with immediate loading following extraction of natural teeth. *Natl J Maxillofac Surg.* 2015;6(2):252–5.
15. Saez-Alcaide LM, Fernandez-Tresguerres FG, Brinkmann JC, Segura-Mori L, Iglesias-Velazquez O, Perez-Gonzalez F, et al. Socket shield technique: A systematic review of human studies. *Ann Anat.* 2021;238:151779. doi:10.1016/j.aanat.2021.151779.
16. Oliva S, Capogreco M, Murmura G, Lupi E, Mariachiarra DC, D'Amario M, et al. The socket shield technique and its complications, implant survival rate, and clinical outcomes: a systematic review. *J Periodontal Implant Sci.* 2023;53(2):99–109.
17. Atieh MA, Shah M, Abdulkareem M, Alqahtani HA, Alsabeeha NH. The socket shield technique for immediate implant placement: A systematic review and meta-analysis. *J Esthet Restor Dent.* 2021;33(8):1186–200.
18. Han CH, Park KB, Mangano FG. The modified socket shield technique. *J Craniofac Surg.* 2018;29(8):2247–54.
19. Ghodpage P, Suroshe A. Mandibular Block Graft for Localised Ridge Augmentation Followed by Delayed Implant Placement: A Case Report. *Cureus.* 2023;15(2):34881. doi:10.7759/cureus.34881.
20. Potdukhe S. All ceramic pressable lithium disilicate maryland bridge: a case report with two year follow-up. *J Clin Diagn Res.* 2022;16(3):1–2.

Author biography

Shruti Potdukhe, Lecturer  <https://orcid.org/0000-0002-2806-8512>

Cite this article: Potdukhe S. Immediate implant placement using socket shield technique followed by delayed implant loading in maxillary canine and premolar region: Two case reports with a follow-up period of 4 years. *IP Ann Prosthodont Restor Dent* 2024;10(3):261–265.