

Content available at: <https://www.ipinnovative.com/open-access-journals>

IP Annals of Prosthodontics and Restorative Dentistry

Journal homepage: <https://www.aprd.in/>

Case Report

Finger prosthesis: Uplifting life, one finger at a time

Anulekha CK^{1*}, Sravya D.N.S¹, Haripriya Aligapally¹, Sreedevi Kondareddy¹,
Shilpa Pasham¹, Akhila Devi Kakarlapudi¹

¹Dept. of Prosthodontics and Crown And Bridge, Kamineni Institute of Dental Sciences, Narketpally, Telangana, India



ARTICLE INFO

Article history:

Received 23-03-2024

Accepted 07-06-2024

Available online 16-08-2024

Keywords:

Modes of retention for finger prosthesis

Attachment for finger prosthesis

ABSTRACT

Partial or complete loss of fingers is frequently encountered in cases of partial hand injuries, representing a prevalent occurrence. While traumatic events are a common cause of finger amputations, congenital malformations and diseases can also contribute to digit loss, thereby widening the spectrum of potential etiologies. Irrespective of the underlying cause, the absence of a finger poses significant challenges, affecting both the functionality and psychological well-being of individuals. Consequently, addressing these challenges becomes paramount, prompting the fabrication of partial or complete finger prostheses as a viable solution to alleviate the associated functional and psychological impacts.

This is an Open Access (OA) journal, and articles are distributed under the terms of the [Creative Commons Attribution-NonCommercial-ShareAlike 4.0 License](#), which allows others to remix, tweak, and build upon the work non-commercially, as long as appropriate credit is given and the new creations are licensed under the identical terms.

For reprints contact: reprint@ipinnovative.com

1. Introduction

Fingers are a type of digit, serving as organs of manipulation and sensation found in the hands of humans and other primates. Usually, humans possess five digits, known as phalanges, on each hand. They facilitate our interaction with the environment and assist in various day-to-day functions.

Partial or complete loss of fingers stands as a prevalent occurrence in cases of partial hand injuries, with traumatic events often serving as the primary cause of finger amputations, though congenital malformations and diseases can also contribute to digit loss.¹ Regardless of the underlying cause, the absence of a finger profoundly affects both the functionality and psychological well-being of an individual, presenting challenges that require careful consideration. To address these multifaceted issues, the fabrication of partial or complete finger prostheses emerges as a valuable and effective solution, offering not only functional restoration but also psychological support and improved quality of life for those affected. The fabrication

of an extraoral prosthesis is as much an art as it is a science. Prosthesis form, coloration, and texture must be as indiscernible as possible from the surrounding natural tissues.²

Retention in the maxillofacial prosthesis has always been a huge challenge. The anatomical constraints of the defect limit the retentive factor in the maxillofacial prosthetic rehabilitation. There are many modes of retention like in the form of implants and its attachments, finger rings, wrist bands, shims etc. However, with whatever mode of retention being used between the acrylic and silicone material, the bond that exists between the two materials has always been a question of debate. The use of primers enhances the chemical bond between the acrylic and MFP silicones but as the extent of the defect increases, the reliability of the bond between the materials is doubtful.

Hence this report describes an innovative approach that utilizes both chemical and mechanical modes of bonding between the two prosthetic materials by using the primer and a die pin. The versatile application of die pin introduced in this case report provides the best possible bond between

* Corresponding author.

E-mail address: anulekhaavinash@gmail.com (Anulekha CK).

the acrylic substructure and the maxillofacial silicone.

2. Case Report

A 60-year-old female patient reported to the Department of Prosthodontics, Kamineni Institute of Dental Sciences, Narketpally, Nalgonda with a chief complaint of a missing teeth in upper and lower jaw. Upon general examination it was found that her index finger on her left hand was partially missing. History revealed that the patient lost a part of her index finger when she was 10 years old because of a traumatic injury. The amputation was partial, involving the mid-part of the proximal phalanx of the left index finger. The residual stump was around 4mm in length.(Figure 1) The wound was completely healed, and the surrounding skin showed no signs of inflammation and infection. The patient had no history of a previous prosthesis. Informed consent was obtained before beginning the treatment procedure.

2.1. Fabrication of finger prosthesis

For the purpose of impression, a PVC pipe was used. It was cut into two halves with slots for correct orientation (Figure 2a). It was also perforated all around to allow excess material to escape (Figure 2b). A thin layer of petroleum jelly was applied to the patient's hand prior to making the impression with irreversible hydrocolloid impression material (Algitex, DPI) (Figure 3). Impressions were then poured with ADA type III dental stone (Gem stone, Shruti Products) to create positive replica of the hand (Figure 4).

Duplication of the residual stump was done and the cast was poured with ADA type IV dental stone (Gem stone, Shruti Products). Then the fabrication of an acrylic shim was done using heat cure acrylic resin. For this modelling wax of 2mm thickness was adapted all over the stump (Modelling wax, AARC, Dental) (Figure 5). For the purpose of retention double die pin with single head was used. The sleeve of the die pin was inserted into the distal end of the wax pattern for shim. The sleeve was covered with cotton and then the flasking of the stump with the wax pattern was done using dental plaster (Dental Plaster Type II, Shruti Products). Dewaxing followed by acrylization was done with heat cure clear acrylic resin (DPI Heat Cure). The shim along with the die pin sleeve was retrieved and tried on the patient's residual stump (Figure 6).

A donor's index finger impression was made with alginate (Figure 7). The positive replica was made with wax. The base of this wax finger was carved out to create a hollow space for the acrylic shim. The counter part of the die pin was inserted into the wax finger. It was then adapted onto the acrylic shim. The shim and the wax finger were attached to each other with the help of the die pin. This was tried on the patient's hand and the morphology of the wax pattern was modified according to the patient's adjacent fingers (Figure 8a,b).

This entire prosthesis was then invested in dental plaster. The mould was created using lost wax technique. A maxillofacial silicone primer (A330-G) was applied onto the acrylic shim.

The process of color matching was conducted meticulously in natural daylight conditions. Different colors were matched for both the upper (dorsal) and lower (ventral) surfaces. The suitable color was then mixed into the silicone material (Figure 9). After achieving the best possible color match, the mold's two halves were closed, placed under a bench press, and left to cure overnight. Once the curing was complete, the mold was opened, and the prosthesis was trimmed, refined, and fitted onto the patient's left hand (Figure 10).

To enhance the aesthetic appearance, prefabricated acrylic nails were applied to the silicone nail bed using cyanoacrylate resin. The prosthesis is held securely in place by a primer on the acrylic shim and a die pin positioned between the silicone prosthesis and the acrylic shim on the residual stump. This setup provides ample retention for the patient to carry out daily tasks comfortably.

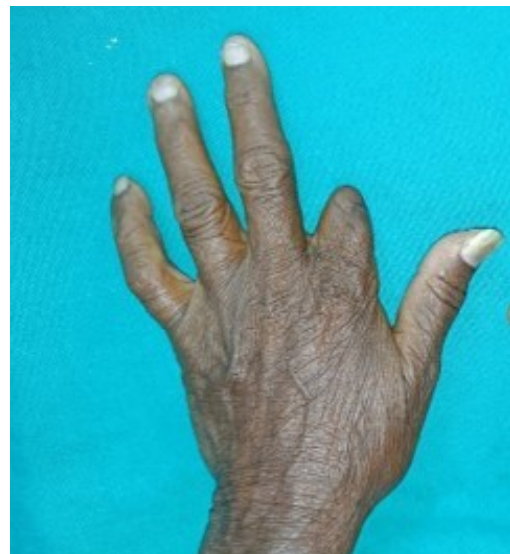

Figure 1: Residual stump of left index finger

3. Discussion

The absence of one or more fingers, whether caused by trauma or congenital factors, leads to a notable reduction in hand functionality and can give rise to social hurdles for the individual. While microsurgery offers the possibility of re-implantation for some traumatic finger injuries, there are instances where this may not be feasible or advisable, such as when patients are unwilling or due to cost considerations. In such cases, prosthetic solutions become essential and can provide significant psychological support to patients, helping them regain a sense of normality and functionality

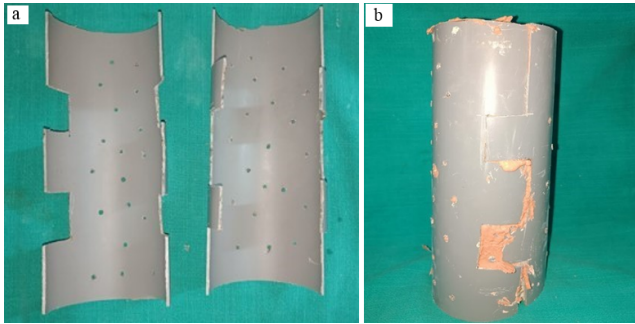


Figure 2: a,b: PVC pipes with slots for impression



Figure 5: Wax pattern for shim

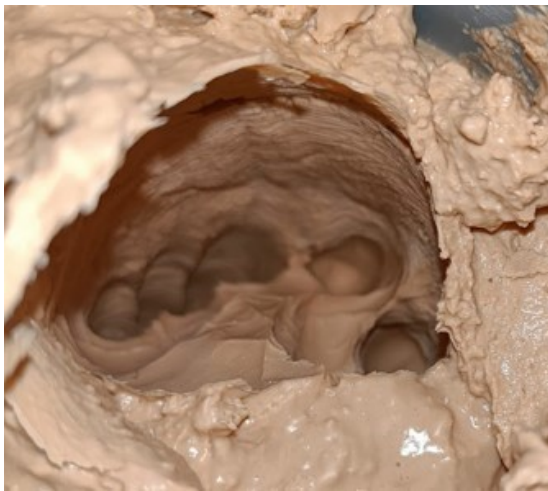

Figure 3: Impression of hand

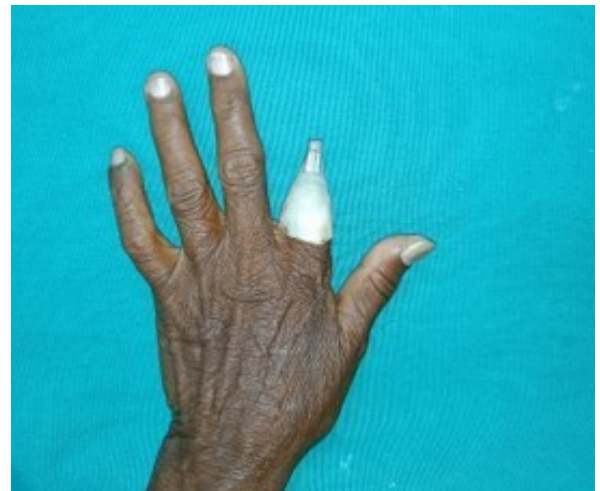

Figure 6: Try in of acrylic shim



Figure 4: Cast of hand



Figure 7: Impression of donor finger

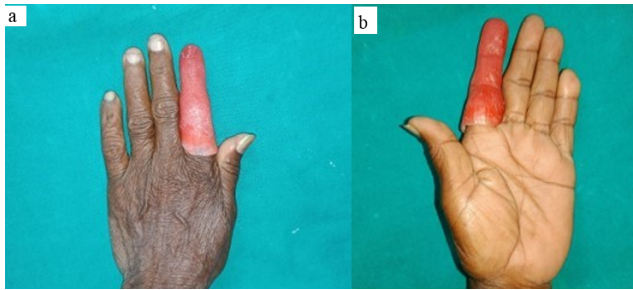


Figure 8: a,b: Wax try in of finger




Figure 9: Color matching and packing of silicone

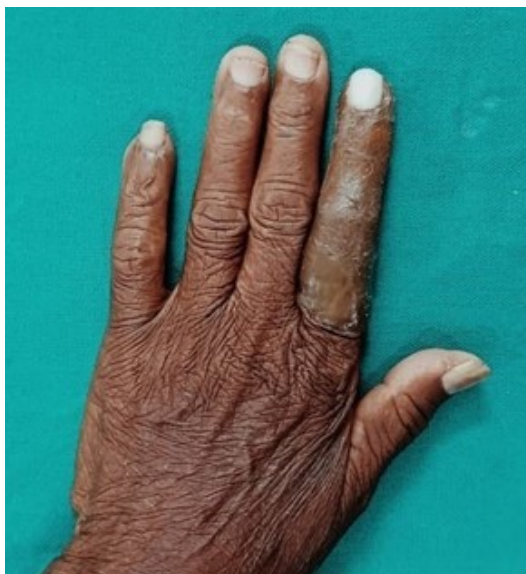

Figure 10: Final prosthesis

despite their loss.^{3,4}

While medical and surgical approaches provide various strategies for managing digital amputations, the fundamental goals of rehabilitation remain consistent: preserving functional length, maintaining useful sensitivity, and enabling the patient to swiftly resume daily tasks. The aesthetic function of the hand is no less important than its active function.⁵ Prosthetics worldwide share a common primary objective: restoring the functional capabilities of individuals with limb deficiencies, while also achieving optimal cosmetic outcomes.

Effective retention of finger prostheses is essential for ensuring both proper function and aesthetics. This relies on careful planning, accurate impression-taking, and meticulous fabricating procedures. Various methods can be employed to achieve retention, including the use of implants, finger rings, medical-grade adhesives, and scraping of the cast to ensure optimal tissue contact.^{6,7}

This case report describes a unique method of retention of the silicone prosthesis. In this case an acrylic shim was used to retain the entire prosthesis on the residual stump. This shim engaged the available tissue undercuts of the stump. The silicone prosthesis was then retained on this stump with the help of primer as well as die pins.

The resin/silicone junction is a point of weakness because the materials have different compositions and there is no chemical bond between them. Therefore, the silicone may tear or separate from the resin during the removal of the prosthesis by the patient.⁸ Clinical studies have indicated the application of primers and adhesives on the resin/silicone interface to enhance the bonding between these materials.⁹ Therefore in this report maxillofacial silicone primer was used to attain chemical bond between the acrylic shim and the silicone finger.

Die pins are generally used in the laboratory for the fabrication of crowns and bridges. But they were repurposed to serve as retention device for the silicone prostheses. This adaptation allows for a practical and efficient means of securing the prosthesis in place, offering an alternative method for retention beyond their conventional use in dental prosthetics. In future prospective also due to the continuous usage, if the silicone part of the prosthesis gets damaged then only that part can be refabricated. The acrylic shim can be reused by application of primer and if the chemical bond between the shim and silicone prostheses fails, still there is the presence of mechanical retention provided by the die pin.

4. Conclusion

The loss of one or more fingers due to traumatic amputation can significantly impact an individual's physical and psychological well-being. Aesthetic appeal and effective retention are crucial factors in successfully restoring a finger through prosthetics. Various retention methods, including

implants and adhesives, have been utilized. However, an alternative approach of using an acrylic shim and die pin for retention has shown considerable success. It offered improved comfort, stability, and functionality for the wearer. Continual research and refinement of prosthetic techniques are essential to enhance outcomes and address the multifaceted needs of individuals relying on these devices for functional and aesthetic restoration.

5. Source of Funding

None.

6. Conflict of Interest


None.

References


1. Michael JW, Buckner H. Options for finger prosthesis. *J Prosthet Orthot*. 1994;6(1):10–9.
2. Taylor TD. *Clinical Maxillofacial Prosthetics*. 1st ed. Chicago, Quintessence; 2000.
3. Pillet J. Esthetic hand prostheses. *J Hand Surg Am*. 1983;8(5 Pt 2):778–81.
4. Jacob PC, Shetty KHM, Garg A, Pal B. Silicone finger prosthesis. A clinical report. *J Prosthodont*. 2012;21(8):631–3.
5. Pereira BP, Kour AK, Leow EL, Pho RW. Benefits and use of digital prostheses. *J Hand Surg Am*. 1996;21(2):222–8.
6. Buckner H. Cosmetic hand prosthesis-a case report. *Orthot Prosthet*. 1980;34(3):41–5.
7. Shweta D, Saurabh L, Farhan S, Aeran H. Fabrication of a glove type finger prosthesis using silicon elastomers. *J Indian Prosthodont Soc*. 2008;8(3):165–8.
8. Gion GG. Surgical versus prosthetic reconstruction of microtia: the case for prosthetic reconstruction. *J Oral Maxillofac Surg*. 2006;64(11):1639–54.
9. Haddad MF, Goiato MC, Santos DMD, Crepaldi NDM, Pesqueira AA, Bannwart LC, et al. Bond strength between acrylic resin and maxillofacial silicone. *J Appl Oral Sci*. 2012;20(6):649–54.

Author biography


Anulekha CK, HOD  <https://orcid.org/0000-0002-5803-9341>

Sravya D.N.S, Post Graduate  <https://orcid.org/0009-0000-8045-0578>

Haripriya Aligapally, Post Graduate  <https://orcid.org/0009-0008-2399-0330>

Sreedevi Kondareddy, Senior Lecturer  <https://orcid.org/0000-0003-1631-703X>

Shilpa Pasham, Senior Lecturer  <https://orcid.org/0009-0003-8599-0313>

Akhila Devi Kakarlapudi, Senior Lecturer  <https://orcid.org/0000-0001-7783-1839>

Cite this article: Anulekha CK, Sravya D.N.S, Aligapally H, Kondareddy S, Pasham S, Kakarlapudi AD. Finger prosthesis: Uplifting life, one finger at a time. *IP Ann Prosthodont Restor Dent* 2024;10(3):245-249.