

Biodentine as material of choice for furcal perforation repair – A case report

Anacleta L. Heredia^{1,*}, Sumita A. Bhagwat², Lalitagauri P. Mandke³

¹Resident, ²Professor, ³Professor & Head, Dept. of Conservative Dentistry & Endodontics, DYPU School of Dentistry, Nerul, Navi, Mumbai

***Corresponding Author:**

Anacleta L. Heredia

Resident, Dept. of Conservative Dentistry & Endodontics, DYPU School of Dentistry, Nerul, Navi, Mumbai

Email: anacletaheredia80@gmail.com

Abstract

Perforations are pathologic or iatrogenic communications between the root canal system and the attachment apparatus. If a perforation occurs, the clinician is faced with the dilemma of repair, surgery or extraction. As the perforation creates a portal of exit in the root canal system it has to be sealed as quickly as possible, since periodontal involvement arising from the perforation can become irreversible with time. Now with the advent of many biocompatible materials, it can be treated successfully in a conservative manner and continue to function as it did before the perforation.

Keywords: Furcation, Perforation, Biodentine, Repair

Introduction

Like any other field in dentistry, a clinician may face several undesirable situations during root canal therapy which can affect the prognosis of the treatment. One such situation is a furcal perforation. Failure to detect and treat a perforation will cause a chronic inflammatory reaction of the periodontal apparatus. This can lead to irreversible loss of the periodontal attachment, bone resorption and, eventually, tooth loss.^[1,2]

Furcal perforation is often an iatrogenic error that occurs during access opening due to a misaligned bur or while searching for the orifices of canals in the floor of the pulp chamber.^[3]

Clinically, a furcal perforation can be determined by the presence of profuse bleeding which is bright red in colour and maybe pulsatile. If an apex locator is used by inserting the file in the perforation, the device will show an extended working length prematurely.

Radiographically, a furcal perforation can be seen as a radiolucency in the floor of the chamber that forms a communication between the pulp space and the periodontal attachment.

Once detected, the perforation should be treated immediately to improve the prognosis of the affected tooth.^[4]

Case Report

A 28 year old male patient came to the Department of Conservative Dentistry and Endodontics with a chief complaint of continuous dull pain since 6 months, a boil on his gums and dislodgement of a restoration in the lower right posterior region 1 day ago. The tooth was slightly tender on percussion and showed no mobility. The patient gave a history of root canal treatment 6 months prior which he had discontinued halfway. Intraoral examination (Fig. 1) Clinical examination

revealed a large access cavity and a perforation of 1.5 x 2 mm on the floor of the chamber (Fig. 2). Radiographic examination revealed a radiolucency in the floor of the chamber along with periapical radiolucencies in all three roots (Fig. 3). Patient was informed about the situation and it was decided to attempt repair of the perforation followed by root canal treatment. A signed consent was obtained from the patient and the treatment was initiated. The access cavity was refined and working lengths were determined using a no.10 and 15 files (Fig. 4). The canals were cleaned and shaped upto F2 with copious saline irrigation. Once cleaning and shaping was completed, the canals were then blocked with files to prevent the entry of the reparative material (Fig. 5). Biodentine™ was manipulated by mixing five drops of the liquid provided by the manufacturer into the capsule. The capsule was then placed on a mixing device, Technomix, at a speed of 4000–4200 rotations/minute for 30 seconds. The mix was carried to the site of perforation. A plugger was used to condense the mix at the site (Fig. 6). After the Biodentine™ had set, the files were removed from the canals and calcium hydroxide was placed in the canals. A cotton pellet was placed in the chamber and the access was temporized with zinc oxide eugenol. The patient was recalled after a week. The dentoalveolar abscess had reduced in size and no discharge was seen from the canals. The canals were irrigated with saline and a second calcium hydroxide dressing was given for another week. At the third appointment, the dentoalveolar abscess had resolved and the patient was asymptomatic (Fig. 7). The canals were irrigated and obturated by lateral condensation on a four month follow up, a radiograph was taken which showed that the periapical radiolucencies had reduced considerably along with absence of radiolucency in the furcal area (Fig. 9). The

tenderness on percussion had subsided and there was no recurrence of the dentoalveolar abscess.

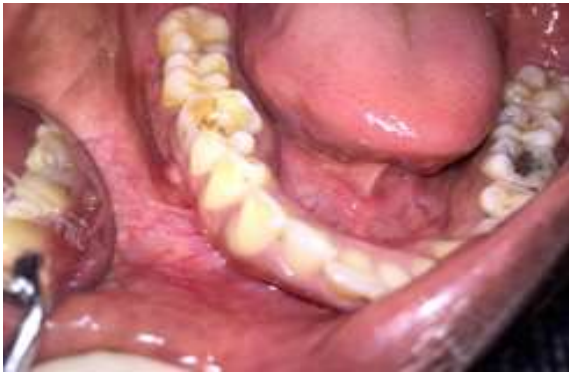

Fig. 1: Pre-operative clinical view showing the dentoalveolar abscess

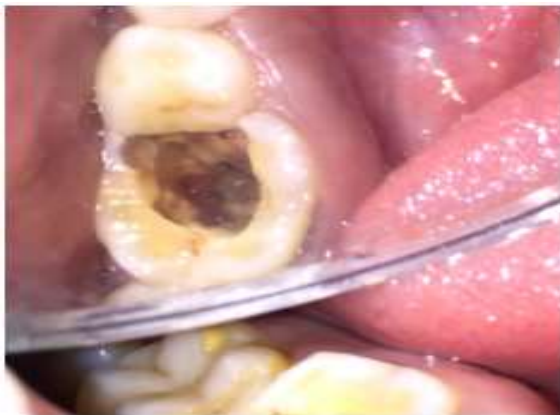

Fig. 2: Pre-operative clinical view showing the furcation perforation

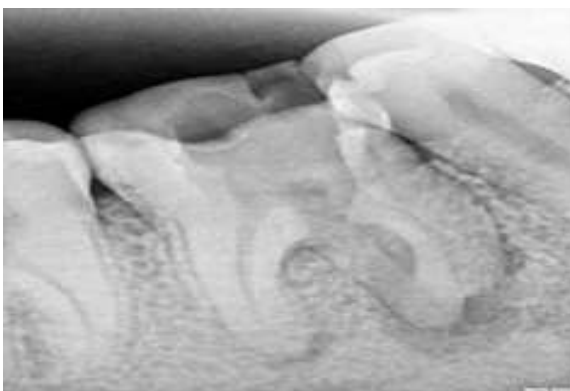


Fig. 3: Pre-operative radiographic view

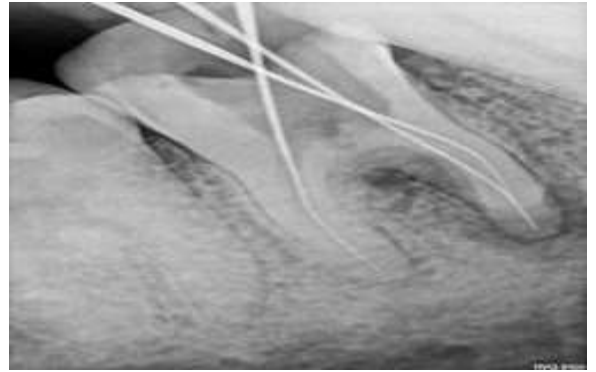


Fig. 4: Working length

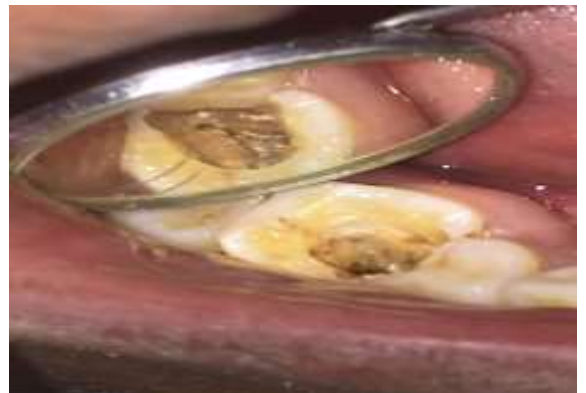


Fig. 5: Repair of perforation with biodentine

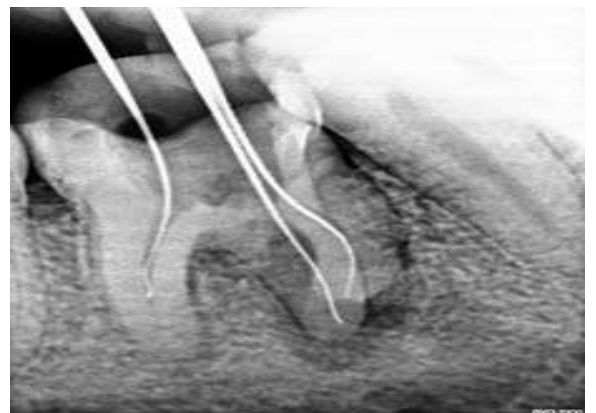

Fig. 6: Blocking of canals with files and repair with biodentine

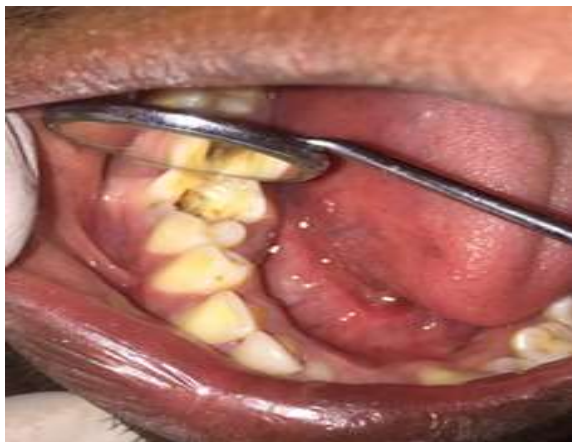

Fig. 7: Resolution of dento alveolar abscess

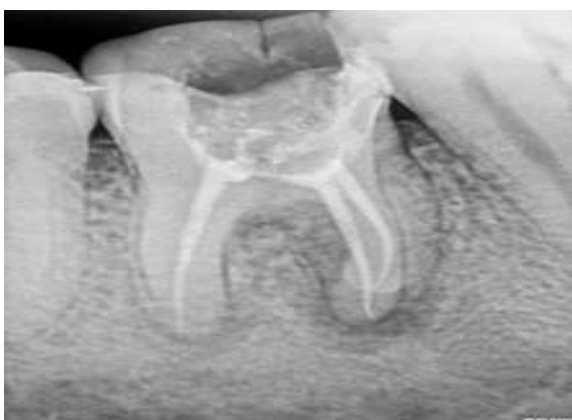

Fig. 8: Obturation of the canals

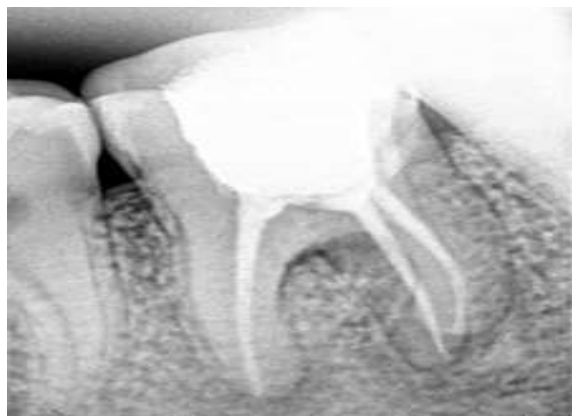

Fig. 9: 4 month follow up

Discussion

A perforation can negatively affect the prognosis of root canal therapy unless it is managed effectively and promptly. A study has reported that perforations are the second greatest cause of failures accounting for 9.62% of all unsuccessful cases.^[5] Therefore, this communication between the root canal system and the periodontal apparatus should be sealed with a biocompatible material as soon as possible.^[4]

Depending upon the status of the crown structure, the bone surrounding the roots and extent and location

of the perforation, a clinician has the option of repairing the perforation, performing a hemisection or bicuspidization or extracting the tooth.

In the current case, the perforation was chronic with minimal bone loss in the furcation and sufficient coronal structure was present. Hence it was decided to repair the perforation with a biocompatible material.

Biodentine™ is a new calcium silicate based reparative material. It has good handling characteristics with a short setting time of twelve minutes. Biodentine™ increases the secretion of TGF-B1 therefore it is also capable of angiogenesis, recruitment of progenitor cells, cell differentiation, and mineralization. It has a high compressive strength of 220 MPa and elastic modulus of 22 GPa, which is very similar to dentin itself.^[6]

Since the furcation area which is subjected to masticatory forces, the repair material used will also bear the brunt of the forces during tooth function. It will also bear the mechanical forces of condensation over the perforation repair site. Therefore it is necessary that the repair material have sufficient push out strength to counter these forces. A study has shown that the push out strength of MTA was lesser than Biodentine™ at 24 hours. Moreover the pushout strength of MTA contaminated with blood was slightly lesser than uncontaminated MTA. However, the presence of blood had not affected the pushout strength of Biodentine™.^[7]

Conclusion

Perforations represent pathologic or iatrogenic communications between the root canal system and the periodontal attachment apparatus. Treating a perforation may often require a multidisciplinary approach in order to establish an appropriate treatment plan, and the clinician must decide whether to extract the tooth or treat it with a nonsurgical and/or surgical approach. The prognosis of perforated teeth is better today than it was in the past, and this is largely due to use of biocompatible materials. With this approach, perforations can be more predictably repaired without surgery, thus reducing the need for invasive and more costly procedures.

References

1. Kvinnsland I, Oswald RJ, Halse A, Gronningsaeter AG. A clinical and roentgenological study of 55 cases of root perforation. *Int Endod J* 1989;22(2):75-84.
2. Jew RC, Weine FS, Keene JJ, Jr., Smulson MH. A histological evaluation of periodontal tissue adjacent to root perforation filled with Cavit. *Oral Surg Oral Med Oral Pathol Oral Radiol Endod* 1982;54(1):124-35.
3. Abhijeet Kamalkishor Kakani¹, Chandrasekhar Veeramachaneni², Chandrakanth Majeti³, Muralidhar Tummala⁴, Laxmi Khyani⁵. A Review on Perforation Repair Materials. *Journal of Clinical and Diagnostic Research*. 2015 Sep, Vol-9(9): ZE09-ZE13.
4. Pitt Ford TR, Torabinejad M, McKendry DJ, et al. Use of mineral trioxide aggregate for repair of furcal

- perforations. *Oral Surg Oral Med Oral Pathol Oral Radiol Endod.* 1995;79(6):756-63.
5. Seltzer S, Bender IB, Smith J, et al. Endodontic failure-an analysis based on clinical roentgenographic and histologic findings. II. *Oral Surg Oral Med Oral Pathol Oral Radiol Endod.* 1967;23(4):517-30.
 6. Saidon J, He J, Zhu Q, Safavi K, Spångberg LS. Cell and tissue reactions to mineral trioxide aggregate and Portland cement. *Oral Surg Oral Med Oral Pathol Oral Radiol Endod* 2003;95(4):483-9.
 7. Vivek Aggarwal, Mamta Singla, [...], and Sarita Kohli. Comparative evaluation of push-out bond strength of ProRoot MTA, Biodentine, and MTA Plus in furcation perforation repair. *J Conserv Dent.* 2014;7(1):95.