

## Rejuvenated Smile with Botox: Opening a new Frontier

Girish Chaudhary<sup>1,\*</sup>, Rajan Jairath<sup>2</sup>, Nimisha Chaudhary<sup>3</sup>, Anshul Chaudhary<sup>4</sup>, Karuna Bector<sup>5</sup>

<sup>1</sup>Senior Lecturer, Baba Jaswant Singh Dental College, Hospital & Research, Punjab, <sup>2</sup>Professor & Head, <sup>4,5</sup>Senior Lecturer, Dept. of Orthodontics, Christian Dental College, Ludhiana, <sup>3</sup>Ex-PG Student, Dept. of Prosthodontics, Kothiwal Dental College, Uttar Pradesh

### \*Corresponding Author:

Girish Chaudhary

Senior Lecturer, Dept. of Orthodontics, Baba Jaswant Singh Dental College, Hospital & Research, Punjab

Email: dr.girishchaudhary@gmail.com

### Abstract

Effects of botulinum toxin type A were reviewed on different areas of face by reviewing its mechanism of action and how can we utilize this toxin in improving the looks and appearance.

**Key Words:** Botulinum toxin, Botox, Acetyl choline

### Introduction

Just as a nice smile can act as a powerful communication tool, an unpleasing smile can have the equally powerful negative impact and this is often one of the reasons why patients seek orthodontic treatment. The display of excessive gingival tissue in the maxilla upon smiling has been called a “gummy smile,” a condition some consider esthetically displeasing. Sexual dimorphism in smile types indicates that the females are twice as likely as males to have gummy smiles.

A gummy smile may be present due to many factors. Most cases of gummy smile have skeletal, gingival and muscular factors as the etiology. Hyperfunction of the upper lip elevator muscle can all play a major etiological role in gummy smile and vertical maxillary excess may also be a contributing factor. The literature contains many reports that address the skeletal problem of vertical maxillary excess<sup>1-5</sup> and gingival problems related to delayed passive eruption.<sup>6-8</sup>

Gingival inflammation resulting from medication or exacerbated by orthodontic appliances contributing to a reduced effectiveness of tooth cleaning can also cause excessive gingival show. Another possible reason for a gummy smile is altered passive eruption when the gingivae does not recede to a normal level after the teeth have erupted. Sometimes a person has parafunctional habits such as Bruxism which can lead to excessive tooth wear and the teeth will appear short, and the gingivae excessively prominent.

The muscular capacity to raise the upper lip higher than average (hyperfunctional muscle) can cause excessive gingival display.<sup>9</sup> Upper lip elevator muscles include the levator labii superioris, levator labii superioris alaeque nasi, levator anguli oris, zygomaticus major, zygomaticus minor, and the depressor septi nasi.

A number of different treatment modalities have been described in the literature for the treatment of gummy smile caused by hyperfunctional upper lip

elevator muscles (mostly the levator labii superioris muscles).

These include both surgical and non-surgical options including: Le Fort 1 osteotomy, crown lengthening procedure, maxillary incisor intrusion, self-curing silicone implant injected at the anterior nasal spine and finally myectomy and partial resection of the levator labii superioris or muscle repositioning.

A nonsurgical alternative for reducing excessive gingival display caused by muscle hyperfunction can be the use of Botulinum toxin which has been under clinical investigation since the late 1970s for the treatment of several conditions associated with excessive muscle contraction or pain.<sup>10</sup>

### What is Botox?

Botulinum toxin, a neurotoxic protein, is produced by the controlled fermentation of an anaerobic bacterium *Clostridium botulinum*. There are 8 different serotypes of botulinum toxin produced by the different strains. Type A (BTX-A) is the most potent and the most commonly used clinically.

Botox (Allergan, Irvine, Calif) is a purified BTX-A. It is a stable, sterile, vacuum-dried powder that is used after dilution with saline solution without preservatives.

The total “dose” of Botox in each vial is always 100 units but different amounts of saline solution can be used with each vial depending on the intended use. Usually each vial contains 100 Units (U) of *Clostridium botulinum* type A neurotoxin complex, 0.5 milligrams of Albumin Human and 0.9 milligrams of sodium chloride in a sterile, vacuum-dried form without a preservative.

### Mechanism of Action

BTX-A weakens skeletal muscles by cleaving the synaptosome-associated protein SNAP-25. It blocks overactive nerve impulses, thus decreasing excessive

muscular contraction or glandular activity by blocking the release of acetylcholine from the Motor neurons for 3-6 months and enabling the repolarization of the postsynaptic terminal.

This blockade of the neuromuscular transmission has no effect on the production of acetylcholine and the effect is almost always reversible within 6 months.

Some investigators have reported a longer duration of this effect (more than 3-6 months) in patients exposed over a prolonged period of time.<sup>11</sup>

The action can be described in the following phases:

**Phase I: Nerve-Muscle Communication is blocked:**

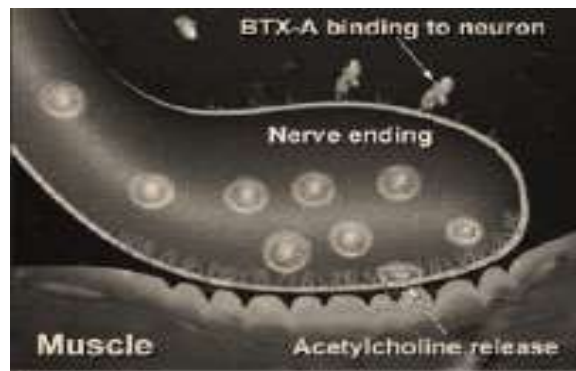
Botox blocks the transmission of overactive nerve impulses to the targeted muscle by selectively preventing the release of the neurotransmitter acetylcholine (ACH) at the neuromuscular junction, temporarily preventing muscle contraction. This is primarily a local effect. Botox may also prevent the release of pain-stimulating neuropeptides in peripheral nerves.

A. **Binding (Fig. 1):** The heavy chain portion of the active ingredient in Botox binds to the cell membrane of the motor nerve via an unidentified high-affinity “acceptor” molecule. This high-affinity binding action allows for efficient uptake of Botox by the motor nerve and facilitates selective, targeted treatment at the injection site.

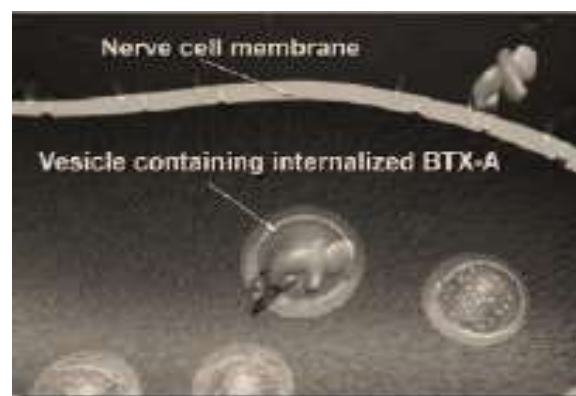
B. **Internalizing (Fig. 2):** After binding, the Botox protein molecule passes through the cell membrane of the motor nerve and into its cytoplasm via a process called endocytosis. It is here that the enzymatic component (light chain) of the Botox protein molecule is activated.

C. **Blocking (Fig. 3):** Inside the motor nerve, the light chain of the Botox protein molecule cleaves apart a protein (called SNAP 25) that enables vesicles which store the neurotransmitter acetylcholine to attach to the cell membrane. Cleaving SNAP 25 prevents these vesicles from fusing with the membrane and prevents the release of acetylcholine into the neuromuscular junction (the space between the motor nerve and the muscle).

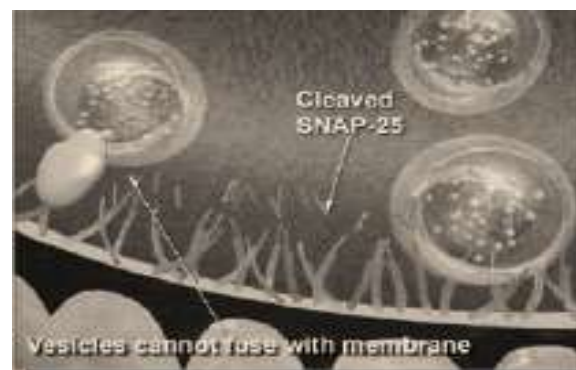
Thus, nerve impulses that control muscle contractions are blocked decreasing muscle activity. Cleaving SNAP25 also blocks release of neuropeptides involved in the transmission of painful sensations (including substance P, glutamate and calcitonin gene-related peptide, or CGRP), theoretically reducing pain sensitization of peripheral nerves. This may be how Botox reduces the neck pain associated with cervical dystonia, although the exact mechanism of action is unknown.



**Fig. 1: Binding**



**Fig. 2: Internalizing**



**Fig. 3: Blocking**

**Phase II: Nerve-Muscle Communication is restored:**

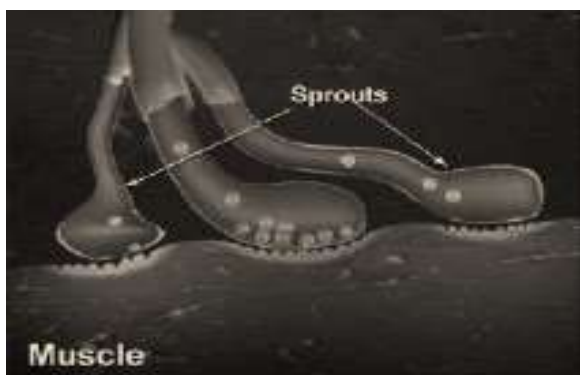
The effect of Botox is generally temporary. Previous nerve impulse activity and associated muscle contractions resume over the course of a few to several months, depending on the individual patient and the indication for which they are being treated.

A. **Nerve Sprouting (Fig. 4):** New nerve endings sprout and connect to the muscle after the original nerve ending is blocked, renewing the ability of the nerve to cause muscle contractions.

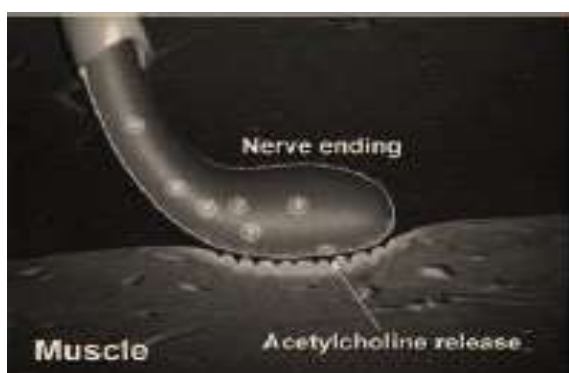B. **Original Nerve Connection Re-established (Fig. 5):** Eventually, the new nerve sprouts retract and the original nerve ending regains its function, suggesting that treatment with Botox does not permanently alter the neuromuscular junction.

BTX-A has been used to treat strabismus,<sup>12</sup> cervical dystonia,<sup>13</sup> blepharospasm and hemifacial spasm,<sup>14</sup> hyperfunctional larynx,<sup>15</sup> juvenile cerebral palsy,<sup>16</sup> spasticity,<sup>17</sup> pain and headache,<sup>18</sup> occupational dystonia and writer's cramp.<sup>19</sup> Since 1987, BTX-A has been widely used for the cosmetic treatment of hyperfunctional facial lines.<sup>20</sup>

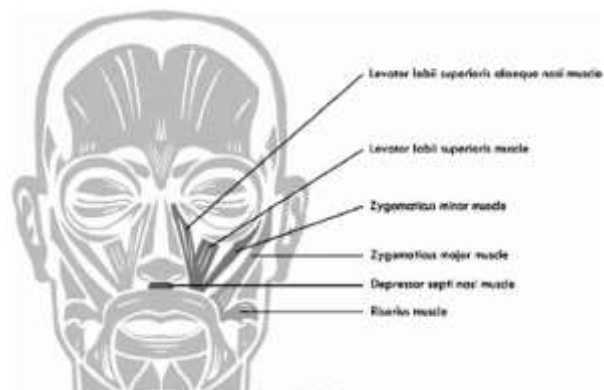
In Dentistry, It has been used in the treatment of Trismus, sialorrhoea, temporomandibular disorders,<sup>21</sup> myofascial pain,<sup>22</sup> Masseteric hypertrophy, and oromandibular dystonia and bruxism,<sup>23</sup> and several other conditions like retraining muscles during orthodontic therapy, in patients with a very strong musculature, in training the patient to get used to new dentures especially in patients with strong irregular muscle contractions who have been edentulous for a long time and have old dentures and they are significantly overclosed, in Jaw line contouring by injecting into masseter muscle thus weakening it and some bulk of this muscle is reduced, resulting in a more tapered jawline.



**Fig. 4: Nerve Sprouting**



**Fig. 5: Re-establishment of Original Nerve Connection**



**Fig. 6: Yonsei point**

### Procedure for injection

For correction of a gummy smile, Botox is injected into the hyperactive elevator muscles of the lip blocking excessive contractions and, thus, preventing the lip from being pulled too far up while smiling. It will be important for the patient to avoid taking aspirin or related products, such as ibuprofen or naproxen if possible after the procedure to keep bruising to a minimum.

Prior to injection, reconstitute vacuum-dried Botox with sterile normal saline without a preservative; 0.9% Sodium Chloride Injection is the only recommended diluent.

Draw up the proper amount of diluent in the appropriate size syringe, and slowly inject the diluent into the vial. Botox should be administered within four hours after reconstitution. During this time period, reconstituted Botox should be stored in a refrigerator (2° to 8°C). Reconstituted Botox should be clear, colourless and free of particulate matter.

Mario Polo<sup>24</sup> has advocated injection of Botox at LLS, LLSAN, LLS/ZM overlap and in severe cases at depressor nasii & OO also. The ideal dosage might be 2.5 U per side at the LLS & LLSAN, 2.5 U per side at the LLS/ZM sites, and 1.25 U per side at the OO sites.

Very recently Hwang et al<sup>25</sup> have proposed an injection point for botulinum toxin-A, and named it as YONSEI POINT and they recommend a dose of 3U at each Yonsei point

**Yonsei point is located at the centre of the triangle formed by (Fig. 6)**

1. Levator labii superioris [LLS]
2. Levator labii superioris alaeque nasi [LLSAN]
3. Zygomaticus minor [ZMi].

**How often do patients need to return for additional injections?**

Effect of Botox is seen within 5-10 days and lasts about 6 months, with a range of 4 to 8 months, at which time the patient can return to repeat the process. It is important not to give injections prematurely (before the effects of the treatment have worn off), as this can

result in a build-up of antibodies to Botox that would dilute the effect of further treatments.

### Contraindications

1. During pregnancy or while breast feeding
2. Presence of inflammation or infection at the site of proposed injection
3. Anyone with known hypersensitivity or allergies to human albumin, Botox toxin, or saline solution.
4. Anyone with known motor neuropathy, neuromuscular disorders such as amyotrophic lateral sclerosis, myasthenia gravis, Lambert-Eaton Syndrome, muscular dystrophy, multiple sclerosis etc.
5. Anyone taking Aminoglycoside antibiotics because aminoglycosides may interfere with neuromuscular transmission and potentiate the effect of Botox therapy.
6. Anyone taking Calcium Channel Blockers

### Advantages

1. Psychological benefit to the patient
2. Minimally invasive

### Disadvantages

1. Short term effect
2. Asymmetrical/unnatural appearance of smile sometimes due to improper injection technique
3. Cost factor

### Side effects

1. Nausea
2. Localized pain
3. Infection
4. Inflammation
5. Tenderness
6. Swelling
7. Redness
8. Bleeding/Bruising

### Should dentists administer Botox therapy?

It is certainly time to recognize that dentists can be just more efficient in these injections than any of the other healthcare providers as dentists have much greater expertise in the oral and maxillofacial areas and are also trained to be experts in the muscles of mastication and the muscles of facial expression, which routinely receive these treatments.

### Conclusion

Botox therapy is a conservative, minimally invasive treatment that can expand our therapeutic options for the benefit of patients.

### References

1. Fish LC, Wolford LM, Epker BN (1978). Surgical-orthodontic correction of vertical maxillary excess. *Am J Orthod* 73,241-57.
2. Schendel SA, Eisenfeld J, Bell WH, Epker BN, Mishelerich DJ (1976). The long face syndrome: vertical maxillary excess. *Am J Orthod* 70,398-408.
3. Bell WH(1977). Correction of maxillary excess by anterior maxillary osteotomy. A review of three basic procedures. *Oral Surg Oral Med Oral Pathol* 43,323-32.
4. Poulton DR. Surgical orthodontics: maxillary procedures (1976). *Angle Orthod* 46,312-31.
5. Coslet JG, Vanarsdall RL, Weisgold A (1977). Diagnosis and classification of delayed passive eruption of dentogingival junction in the adult. *Alpha Omegan* 70,24-8.
6. Conley RS, Legan HL (2002). Correction of severe vertical maxillary excess with anterior open bite and transverse deficiency. *Angle Orthod* 72,265-74.
7. Garber DA, Salama MA (1996). The aesthetic smile: diagnosis and treatment. *Periodontol* 11,18-28.
8. Peck S, Peck L, Kataja M (1992). The gingival smile line. *Angle Orthod* 62,91-100.
9. Brin MF, Hallett M, Jankovic J. Preface. In: Brin MF, Hallett M, Jankovic J, editors. *Scientific and therapeutic aspects of botulinum toxin*. Philadelphia: Lippincott Williams and Wilkins; 2002. p. v-vi.
10. Binder WJ, Blitzer A, Brin MF (1998). Treatment of hyperfunctional lines of the face with botulinum toxin A. *Dermatol Surg* 24,1198-1205.
11. Scott AB. The role of botulinum toxin type A in the management of strabismus. In: Brin MF, Hallett M, Jankovic J, editors. *Scientific and therapeutic aspects of botulinum toxin*. Philadelphia: Lippincott Williams and Wilkins; 2002. p. 189-95.
12. Comella CL. Cervical dystonia: treatment with botulinum toxin serotype A as Botox® or Dysport®. In: Brin MF, Hallett M, Jankovic J, editors. *Scientific and therapeutic aspects of botulinum toxin*. Philadelphia: Lippincott Williams and Wilkins; 2002. p. 359-64.
13. Mauriello JA. The role of botulinum toxin type A (Botox®) in the management of blepharospasm and hemifacial spasm. In: Brin MF, Hallett M, Jankovic J, editors. *Scientific and therapeutic aspects of botulinum toxin*. Philadelphia: Lippincott Williams and Wilkins; 2002. p. 197-206.
14. Blitzer A, Zalvan C, Gonzalez-Yanez O, Brin MF. Botulinum toxin type A injections for the management of the hyperfunctional larynx. In: Brin MF, Hallett M, Jankovic J, editors. *Scientific and therapeutic aspects of botulinum toxin*. Philadelphia: Lippincott Williams and Wilkins; 2002. p. 207-16.
15. Delgado MR. The use of botulinum toxin in juvenile cerebral palsy. In: Brin MF, Hallett M, Jankovic J, editors. *Scientific and therapeutic aspects of botulinum toxin*. Philadelphia: Lippincott Williams and Wilkins; 2002. p. 217-22.
16. Moore AP. Botulinum toxin type A in the treatment of spasticity. In: Brin MF, Hallett M, Jankovic J, editors. *Scientific and therapeutic aspects of botulinum toxin*. Philadelphia: Lippincott Williams and Wilkins; 2002. p. 223-32.
17. Brin MF, Binder W, Blitzer A, Schenrock L, Pogoda JM. Botulinum toxin type A BOTOX® for pain and headache. In: Brin MF, Hallett M, Jankovic J, editors. *Scientific and therapeutic aspects of botulinum toxin*. Philadelphia: Lippincott Williams and Wilkins; 2002. p. 233-50.
18. Karp BI. The role of botulinum toxin type A in the management of occupational dystonia and writer's cramp. In: Brin MF, Hallett M, Jankovic J, editors. *Scientific and therapeutic aspects of botulinum toxin*. Philadelphia: Lippincott Williams and Wilkins; 2002. p. 251-8.

19. Sposito MM (2002). New indications for botulinum toxin Type A in cosmetics: mouth and neck. *Plast Reconstr Surg* 110,601-11.
20. Schwartz M, Freund B. Botulinum toxin A therapy for temporomandibular disorders. In: Brin MF, Hallet M, Jankovic J, editors. *Scientific and therapeutic aspects of botulinum toxin*. Philadelphia: Lippincott Williams and Wilkins; 2002. p. 259.
21. Royal MA. The use of botulinum toxins in the management of myofacial pain and other conditions associated with painful muscle spasm. In: Brin MF, Hallet M, Jankovic J, editors. *Scientific and therapeutic aspects of botulinum toxin*. Philadelphia: Lippincott Williams and Wilkins; 2002. p. 309-22.
22. Tintner R, Jankovic J. Botulinum toxin type A in the management of oromandibular dystonia and bruxism. In: Brin MF, Hallet M, Jankovic J, editors. *Scientific and therapeutic aspects of botulinum toxin*. Philadelphia: Lippincott Williams and Wilkins; 2002. p. 343-50.
23. Mario polo (2005). Botulinum toxin type A in the treatment of excessive gingival display. *AJO DO* 127,214-218.
24. Woo-Sang Hwang, Mi-Sun Hur, Kyung-Seok Hu, Wu-Chul Song, Ki-Seok Koh, Hyoung-Seon Baik et al (2009). Surface anatomy of the lip elevator muscles for the treatment of gummy smile using botulinum toxin. *Angle Orthod.* 79,70-77.