

Content available at: <https://www.ipinnovative.com/open-access-journals>

IP Annals of Prosthodontics and Restorative Dentistry

Journal homepage: <https://www.aprd.in/>

Case Report

Rehabilitation of an ocular defect with custom ocular prosthesis- A case report

Raj Chandrakant Salvi^{1*}, Manish Chauhan¹, Jyoti Tembhurne¹, Arti Gangurde¹, Pratiksha Shetty¹

¹Dept. of Prosthodontics and Crown and Bridge, Government Dental College and Hospital, Mumbai, Maharashtra, India



ARTICLE INFO

Article history:

Received 31-10-2023

Accepted 16-11-2023

Available online 04-12-2023

Keywords:

Ocular defect

Anophthalmic cavity

Custom ocular prosthesis

Tooth coloured heat cure acrylic

ABSTRACT

This abstract introduces a custom ocular prosthesis crafted from tooth-colored acrylic. This innovative prosthesis offers a natural and aesthetically pleasing solution for individuals with ocular defects. The tooth-colored acrylic material seamlessly blends with surrounding tissues, enhancing both cosmetic appearance and comfort. The fabrication process employs advanced techniques to ensure a personalized fit and accurate color matching. The prosthesis not only restores visual symmetry but also boosts the individual's self-esteem and overall quality of life. By addressing cosmetic and functional concerns, this advancement in ocular prosthetics holds the potential to significantly improve the quality of life for those in need of such interventions.

This is an Open Access (OA) journal, and articles are distributed under the terms of the [Creative Commons Attribution-NonCommercial-ShareAlike 4.0 License](https://creativecommons.org/licenses/by-nc-sa/4.0/), which allows others to remix, tweak, and build upon the work non-commercially, as long as appropriate credit is given and the new creations are licensed under the identical terms.

For reprints contact: reprint@ipinnovative.com

1. Introduction

The loss of an eye is the most tragic of all sensory organ losses; as a result, until one is partially or completely lost, its true value is never fully realised.¹⁻³ Ocular prostheses have been essential in helping people with anophthalmia to regain their cosmetic and functional qualities.⁴ In general, there are three different kinds of acrylic resin eye prostheses: (1) custom-fitted eye prostheses created from an impression of the socket; (2) stock (prefabricated) eye prostheses; and (3) stock eye prostheses modified in various ways.^{5,6}

The challenges of getting a perfect fit, a realistic look, and ideal comfort in traditional stock ocular prostheses have fueled advances in custom ocular prosthesis design and production.⁷ Custom ocular prostheses are tailored to the individual's unique eye socket shape and colour, resulting in a more natural appearance and enhancing the overall experience for the wearer, which can positively impact the wearer's self-esteem and confidence.⁸

* Corresponding author.

E-mail address: raj.salvi54@gmail.com (R. C. Salvi).

This case report aims to highlight a notable instance of an ocular loss patient who was successfully treated with a customised ocular prosthesis. The patient's distinctive anatomical features were carefully matched to the prosthesis, producing an improved aesthetic result.

2. Case Report

A 49 year old male patient came to the department of prosthodontics and crown and bridge, with chief complaint of unesthetic appearance due to missing left eye. The patient encountered a road traffic accident 18 years back. He suffered major trauma to his left eye, nose and maxilla. The left eye was enucleated. He was suffering from severe emotional trauma due to deformed facial esthetics.

On examination a ocular defect with shrunken anophthalmic cavity with intact soft tissue bed was observed. The eyelid movements were normal. The periorbital tissues show no signs of inflammation. The midface was depressed due to the partial maxillectomy and absence of nasal prominence. (Figure 1) After the detailed examination,

patient was explained regarding rehabilitation using a custom ocular prosthesis.

2.1. Procedure

Patients anophthalmic socket was irrigated with saline followed by light lubrication with lubricant. A semi customized impression tray was made with an addition silicone light body applicator tip (Avue gum light body, Dental Avenue, India) and plastic spoon. (Figure 2)

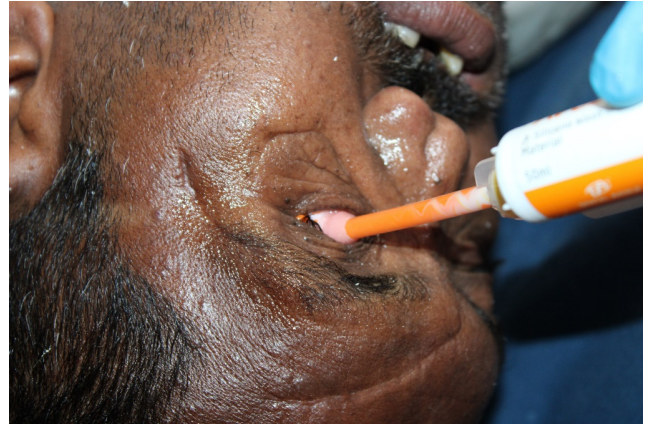

Figure 3: Recording of primary impression



Figure 1: Frontal photo

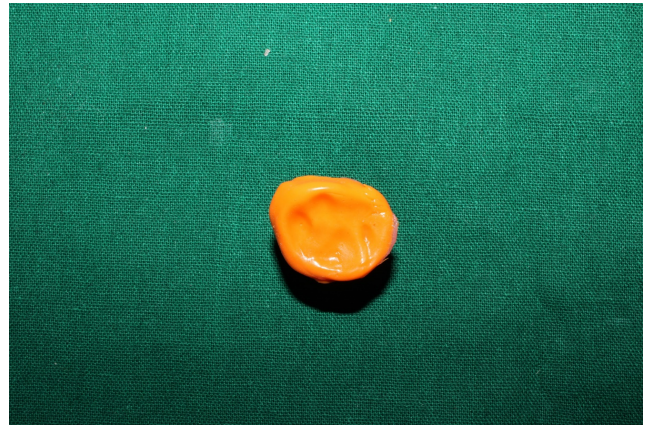

Figure 4: Final impression

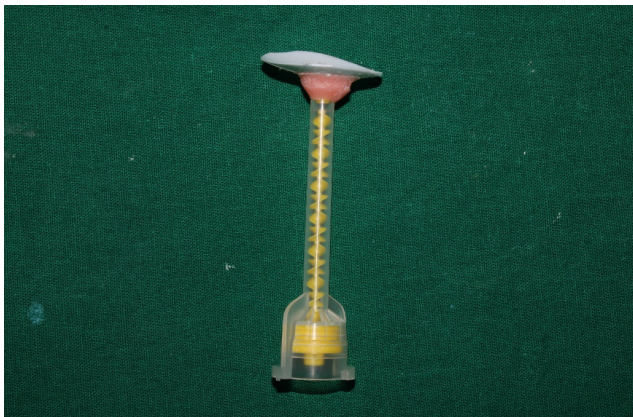

Figure 2: Semi customized impression tray

After all the corrections in the tray, the light body was injected in the anophthalmic cavity and the patient was instructed to close the eyelids and perform various eye



Figure 5: Marking points for iris centering



Figure 6: Trial of wax pattern along with centered iris




Figure 8: Stabilization of iris

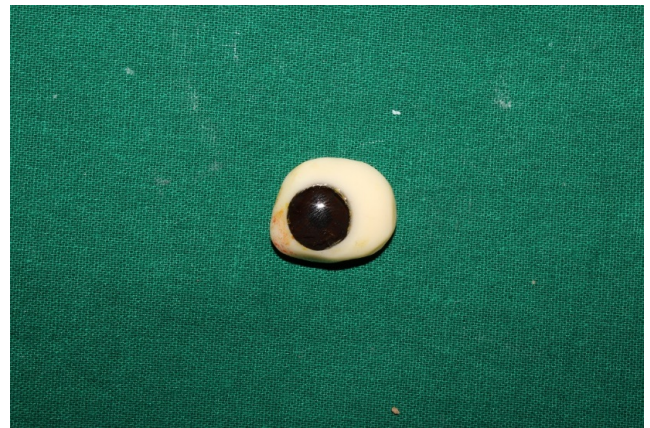


Figure 9: Characterized ocular prosthesis

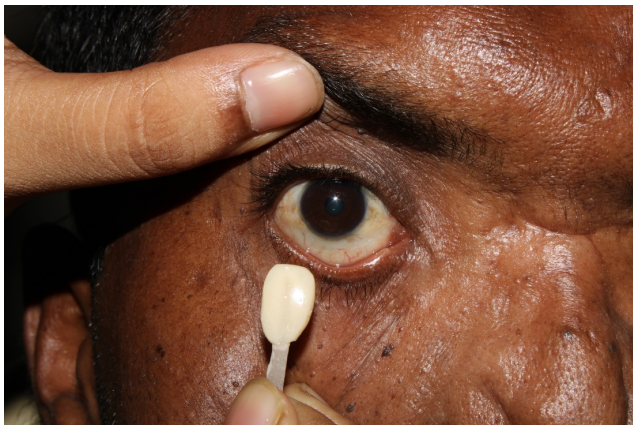

Figure 7: Scleral shade selection



Figure 10: Delivery of ocular prosthesis

movements. (Figure 3) After setting the primary impression was removed and inspected for any voids. Boxing was done with modelling wax.

The impression was poured to obtain a split cast. The first pour was done till the convexity or height of contour of the ocular defect with type III dental stone (Kalrock; Kalabhai Karson, India) followed by a second pour with type IV dental stone. (Kalstone; Kalabhai Karson, India) The cast were retrieved and evaluated for any errors.

Custom tray was fabricated with self cure acrylic resin. (DPI self-cure tooth moulding powder, Mumbai) The final impression was made using light body similar to the primary

impression. The final impression was removed and checked for any error. (Figure 4) This was followed by beading and boxing. A final cast was made in similar way to obtain a split cast. Wax pattern was made to duplicate the contour of contralateral eye. Patient was instructed to perform various eye movements to check the fit and comfort.

Stock iris was selected to match the size and color of patients contralateral iris. Iris centering was done by marking points on patients face. These points were facial midline, centre of the iris of contralateral eye and third point was marked at the same distance from first point on the left side as per distance measured from first and second point with metal scale. (Figure 5) The lines were transferred on the wax pattern and final cast followed by centering of the iris which was placed in patients anophthalmic cavity. (Figure 6)

Patients scleral shade was selected using customized shade guide created with tooth coloured heat cure acrylic resin. (Figure 7) The iris was stabilized with plastic cap of gas torch and adhesive. (Figure 8) Flasking was done followed by dewaxing, packing and processing with tooth colored heat cure acrylic resin. (DPI heat-cure tooth moulding powder, Mumbai)

The prosthesis was retrieved followed by characterization with acrylic colors to match the patients contralateral eye. A thin layer of spacer wax was adapted on this ocular prosthesis and flasking, dewaxing, and processing was done with heat cure clear acrylic resin. The final custom ocular prosthesis was retrieved followed by finishing and polishing. (Figure 9) This final prosthesis was delivered to the patient and evaluated critically for lid drape, contour, and dimension. (Figure 10) The follow-up was done after a week.

3. Discussion

One significant maxillofacial defect that requires prosthetic replacement is an ocular defect.^{9,10} The prosthodontist is someone who steps in to provide the patient with an artificial eye to ease the pain of losing an eye in cases of absence or loss.^{1,11}

Ocular defects refer to the loss of an eye due to various reasons, such as trauma, congenital abnormalities, or disease.¹² Ocular prostheses are designed to restore the natural appearance and provide psychological benefits to the patient. In recent years, custom-made ocular prostheses using tooth-coloured heat-cure acrylic resin have gained popularity due to their aesthetic appeal and improved comfort.

The use of ocular prostheses dates back to ancient times, when materials like painted clay or precious metals were used to create artificial eyes.^{13,14} The evolution of prosthetic materials and techniques has come a long way. In the mid-20th century, advancements in dentistry led to the adoption of tooth-coloured acrylic resins, which revolutionised the

field of ocular prosthetics.

Customized ocular prostheses are individually crafted for each patient, taking into consideration their unique facial anatomy and eye socket. The process involves taking an impression of the eye socket, capturing details of the surrounding tissues, and selecting the appropriate shade to match the patient's existing eye.

The use of tooth-coloured acrylic resin allows for a more seamless integration with the remaining natural eye, making it challenging to distinguish between the prosthetic and the real eye.¹⁵ Acrylic resin is well tolerated by the body, reducing the risk of allergic reactions or irritations. The prosthesis is custom-made, ensuring an accurate fit and a natural look, enhancing the patient's self-esteem and confidence.

Acrylic resin is a durable material, providing longevity to the prosthesis with proper care and maintenance. The lightweight nature of acrylic resin reduces strain on the eye socket and surrounding tissues, improving comfort for the wearer.

4. Conclusion

This case report highlights the successful fabrication of a custom ocular prosthesis using heat-cure tooth-colored acrylic resin. The patient with ocular defect achieved significant improvements in appearance and self-esteem with the prosthetic intervention. The tooth-colored acrylic resin allowed for a realistic and aesthetically pleasing prosthesis, closely resembling the natural eye with enhanced comfort and ease of use. The use of heat-cure tooth-colored acrylic resin offers a promising material choice for durable and biocompatible ocular prostheses, enhancing the quality of life for patients with ocular defects.

5. Source of Funding

None.

6. Conflict of Interest


None.

References

1. Doshi PJ, Aruna B. Prosthetic management of patient with ocular defect. *J Indian Prosthodont Soc.* 2005;5(1):37–45.
2. Moore DJ, Ostrowski JS, King LM. A quasi-integrated custom ocular prosthesis. *J Prosthet Dent.* 1974;32(4):439–42. doi:10.1016/0022-3913(74)90355-2.
3. Newton JT, Fiske J, Foote O, Frances C, Loh IM, Radford DR, et al. Preliminary study of the impact of loss of part of the face and its prosthetic restoration. *J Prosthet Dent.* 1999;82(5):585–90.
4. Goiato MC, Bannwart LC, Haddad MF, Santos DM, Pesqueira AA, Miyahara GI, et al. Fabrication techniques for ocular prostheses—an overview. *Orbit.* 2014;33(3):229–33.
5. Bartlett SO, Moore DJ. Ocular prosthesis: A physiologic system. *J Prosthet Dent.* 1973;29(4):450–9.

6. Moore DJ, Firtell DN. A simplified method of measuring the diameter of the anterior segment of the eye. *Am J Ophthalmol.* 1969;67(5):769–70.
7. Baylor E, Phillips PW. Custom-made ocular prostheses: A review. *J Prosthet Dent.* 2004;91(4):386–90.
8. Pires RTF, Vaz-Pereira S, Lagoa R. Improving the quality of life of patients with ocular prosthesis: Benefits and Design of Custom Ocular Prostheses. *J Craniofac Surg.* 2018;29(7):675–8.
9. Guttal SS, Patil NP, Vernekar N, Porwal A. A simple method of positioning the iris disk on a custom-made ocular prosthesis. A clinical report. *J Prosthodont.* 2008;17(3):223–7.
10. Shivji AR, Bhat S, Shetty P. Prosthodontic management of an ocular defect - A case report. *J Indian Prosthodont Soc.* 2001;1(3):33–5.
11. Laney WR. Maxillofacial Prosthetics. 1st edn. The University of Michigan, PSG Pub. Co.; 1979. p. 279–306.
12. Perman KI, Baylis HI. Evisceration, enucleation and exenteration. *Otolaryngol Clin North Am.* 1988;21(1):171–82.
13. Mccord CP. Artificial eyes; the early history of ocular prostheses. *J Occup Med.* 1965;7:61–8.
14. Danz-Sr W. Ancient and contemporary history of artificial eyes. *Adv Ophthalmic Plast Reconstr Surg.* 1990;8:1–10.
15. Sykes LM. Custom made ocular prostheses: A clinical report. *J Prosthet Dent.* 1996;75(1):1–3.

Author biography

Raj Chandrakant Salvi, Post Graduate Student  <https://orcid.org/0009-0007-0675-4056>

Manish Chauhan, Associate Professor

Jyoti Tembhurne, Professor and Head

Arti Gangurde, Associate Professor

Pratiksha Shetty, Post Graduate Student

Cite this article: Salvi RC, Chauhan M, Tembhurne J, Gangurde A, Shetty P. Rehabilitation of an ocular defect with custom ocular prosthesis- A case report. *IP Ann Prosthodont Restor Dent* 2023;9(4):239-243.