

Content available at: <https://www.ipinnovative.com/open-access-journals>

IP Annals of Prosthodontics and Restorative Dentistry

Journal homepage: <https://www.aprd.in/>

## Case Report

# Functional balancing in complete dentures: Revisiting the Paterson's technique- A case report

Varsha Pathiyil<sup>1\*</sup>, Richa<sup>1</sup>, Irfanul Huda<sup>1</sup>, Santosh Anand<sup>1</sup>, Preeti<sup>1</sup>

<sup>1</sup>Dept. of Prosthodontics, Patna Dental College and Hospital, Patna, Bihar, India



### ARTICLE INFO

#### Article history:

Received 02-11-2023

Accepted 16-11-2023

Available online 04-12-2023

#### Keywords:

Paterson's Technique

Functionally Generated Path

Chewin Method

Occlusal Plane

Complete Denture

### ABSTRACT

**Introduction:** A good occlusion is the key to the comfort and longevity of a prosthesis.

**Case characteristics:** This case report presents a 63 year old male patient who reported with the complaint of difficulty in chewing since past 3 months.

**Outcome:** On examination, the patient presented with completely edentulous upper and lower arches. A detailed case history was recorded, followed by primary and secondary impressions. The maxillo-mandibular relation was recorded conventionally on wax occlusal rims. A trough was then made in the wax and filled with a mixture of dental plaster and carborundum. The mix was kept 2mm above the plane. The rims were inserted and the patient was instructed to perform lateral and protrusive movements resulting in the incorporation of the compensating curves. The recorded plaster index served as a guide for the teeth arrangement. The denture was processed and delivered with very minimal need for post insertion corrections.

**Discussion:** According to Paterson (1923), an articulator with lateral movements is not necessary to establish a balanced occlusion when using the functional technique. The teeth arrangement is entirely dependent on the established curves for obtaining balance.

**Conclusion:** Various techniques are cited throughout the literature to provide a successful prosthesis. With all the advances in the digital era, denture fabrication is not an automated procedure. It is pertinent that the clinicians master the fundamentals of prosthesis fabrication, without which any amount of technology and/or persistence might be in vain.

This is an Open Access (OA) journal, and articles are distributed under the terms of the [Creative Commons Attribution-NonCommercial-ShareAlike 4.0 License](https://creativecommons.org/licenses/by-nc-sa/4.0/), which allows others to remix, tweak, and build upon the work non-commercially, as long as appropriate credit is given and the new creations are licensed under the identical terms.

For reprints contact: [reprint@ipinnovative.com](mailto:reprint@ipinnovative.com)

## 1. Introduction

In the month of April 1923, Dr. Alexander Horn Paterson, a lecturer in the Department of Advanced Prosthetic Dentistry in the University of Maryland, USA, read a paper before the First District Dental Society of New York on "Construction of Artificial Dentures". He discussed in detail the steps involved in fabrication of a complete denture, the difficulties faced during this and concluded saying that "the time will never come when dentures will be made without an effort".

\* Corresponding author.

E-mail addresses: [varsha1892@gmail.com](mailto:varsha1892@gmail.com) (V. Pathiyil), <https://orcid.org/0009-0000-3263-8664> (Richa).

He said that improvements in procedures will definitely aid in the work but never will it be universal for all to be successful cases. Even after a 100 years of this historic event in dentistry, even after all the inventions and developments up to the digital age that has descended right now, the concluding statement of this extraordinarily written paper holds good- "the prosthetist supplies a part that cannot possibly be incorporated in an articulator".<sup>1</sup>

A century later this paper was published, an effort is being made in different parts of the world trying to figure out the various advantages the "Paterson technique" provides in the fabrication of complete denture and if this technique can still be utilized and/or modified with all the advancements

in knowledge and technology we currently have.

This article discusses a modification of the Paterson technique and how it can be used in day-to-day practice along with its various advantages and disadvantages through a case report.

## 2. Case Report

A 63-year-old male patient reported to the PG clinic of the Prosthodontics Division at Patna Dental College and Hospital complaining of difficulty in chewing with the existing dentures and the displeasure in its unesthetic appearance.

A thorough clinical examination revealed completely edentulous maxillary and mandibular arches with well-rounded residual ridges and healthy mucosa. On TMJ examination, patient gave history of clicking with no history of pain. Deviation to the left was seen during mouth opening. The patient also presented with sharp and acute gonial angles bilaterally.

The existing prosthesis showed an overvalued occlusal vertical dimension and poorly distributed occlusal contacts.

After contemplation, a decision was made to provide the patient with newly fabricated dentures in bilateral balanced occlusion, using a functionally generated path, keeping in mind, the functionally compromised temporomandibular joint..



Figure 1:

### 2.1. Procedure

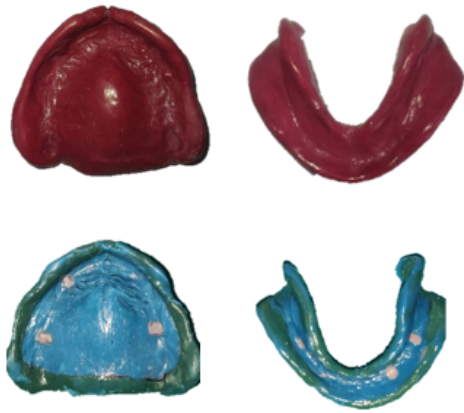1. Primary and secondary impressions were made as for conventional complete dentures. (Figure 2)
2. The maxillary occlusal plane was determined using a Fox Plane ((Dr. Frank Fox; Dentsply /York division, York, PA), keeping the anterior plane 2mm below the upper lip. The lower rim was adjusted according to the patient's occlusal vertical dimension and sealed in centric relation position.

3. The maxillomandibular record was then transferred and articulated on a mean value articulator. (Figure 4)
4. The height of the upper rim was reduced by 2mm from the occluding surface, the wax was removed to form a trench with wax walls around to hold the material in. (Figure 5)
5. Petroleum jelly was applied on the occluding surface of lower rim.
6. A plaster-carborundum paste was made in 1:1 ratio (Figure 6) and the trench on the upper rim was filled. The articulator was then closed against the lower rim, excess removed and left to set. (Figure 7)
7. Steps from 4-6 was repeated on the lower rim.
8. Once the mix was set, the rims were transferred intra-orally and the patient was asked to perform lateral and protrusive movements. (Figure 8)
9. Short breaks were taken in between to allow the patient to rinse the mouth and rest and to verify the pre-determined vertical dimension on the articulator.
10. The mandibular movements were continued till the rims touched evenly in both lateral as well as protrusive movements i.e. till the Christensen's phenomenon was overcome. Anterolateral and posterolateral curves were found to be developed in glass plate relation.(Figures 9, 10, 11 and 12)
11. Arrangement was done with labio-lingual and mesio-distal inclination as per regular guidelines. The occlusal plane was determined by the plane that was obtained on the rims.
12. After arranging the upper anterior teeth in the required arch form, the upper posteriors were arranged in such a way that both the buccal as well the palatal cusps evenly touched the plane obtained on the lower occlusal rim.(Figures 13, 14, 15, 16, 17, 18 and 19).
13. The trial denture was inserted and checked for static and dynamic occlusal contacts.
14. The trial denture was then processed with heat cure acrylic and the final denture was again checked for any premature contacts in both centric and eccentric positions. (Figures 23, 24, 25 and 26 )

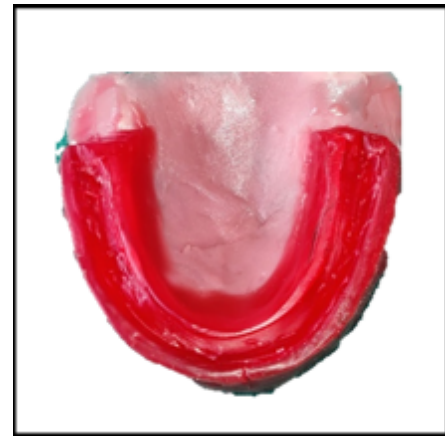
## 3. Discussion

It was observed that following teeth arrangement according to the obtained functionally generated plane, the occlusal plane-glass plate relation was found to be in accordance with the principles of ideal teeth arrangement. In addition, bilateral balanced occlusion and even occlusal contacts in eccentric movements were established intra-orally in final dentures, which improved patient comfort and satisfaction with the new dentures.

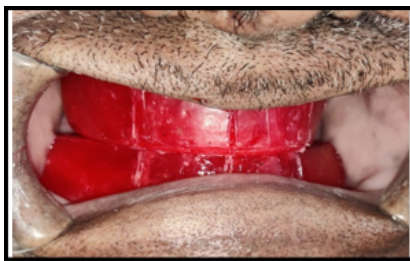The Paterson's technique was introduced by Alexander Horn Paterson in 1923.<sup>1</sup> Paterson described the curve of Spee as an anatomic, antero-posterior curve that begins at




**Figure 2:** Maxillary and mandibular primary and secondary impressions




**Figure 5:** Trench made within the rim to hold the material



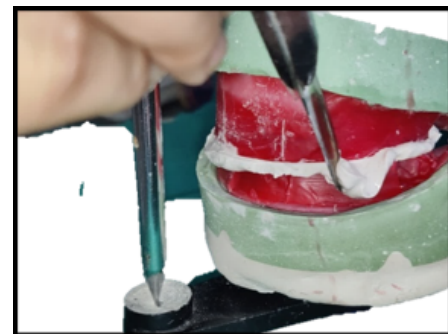
**Figure 3:** Maxillomandibular relation recorded



**Figure 6:** Plaster-carborundum paste in 1:1 ratio



**Figure 4:** Jaw relation transferred to mean value articulator



**Figure 7:** Articulator closed against the mandibular rim

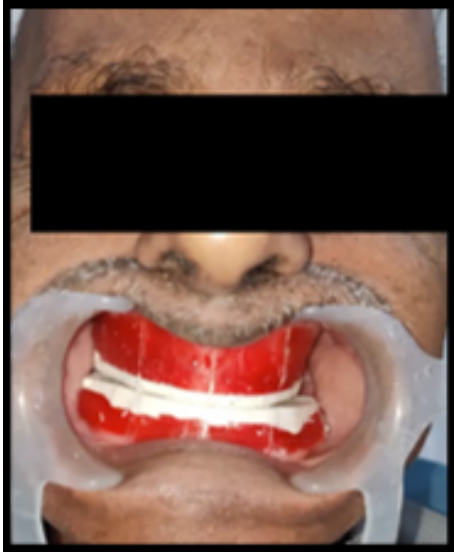the incisal edges of the lower anterior teeth, passes over the cusps of the bicuspid and molars and ends in the coronoid process of the temporal bone.<sup>2</sup>

In addition to this curve, he said that a lateral curve can be seen over the occlusal surfaces of the teeth in a natural dentition. He concluded by stating a few advantages:

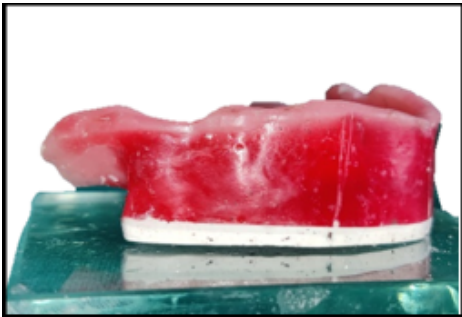1. The movements of the mandible are harmonized with the movements of the condyle heads in the glenoid fossa.<sup>2</sup>
2. The pressure under biting stress is equalized owing to the milling of the planes.<sup>2</sup>

3. The method of arranging the teeth is simplified and perfect balance of the finished dentures is established.<sup>2</sup>


The importance of establishing a Curve of Spee has been explained thoroughly by J.W. Needles in his article in 1923.<sup>3</sup> He stated that if the Curve of Spee is in harmony with the condylar path, the mandible may move to any occlusal position without changing its position from the maxillae. He further said that this in turn will confine the mandibular movement entirely to the joint between the fibrocartilage and the articular eminence. There is no



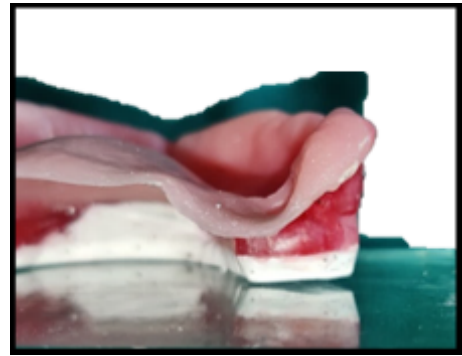
**Figure 8:** Patient performing lateral and protrusive movements



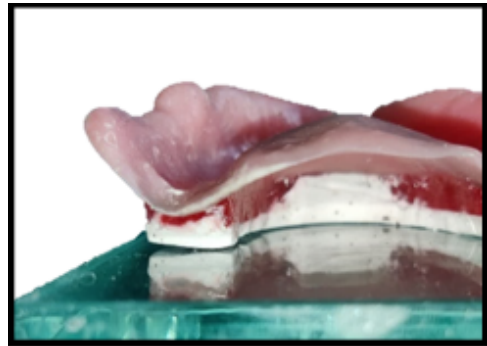
**Figure 9:** Anteroposterior curve after functional movements (right)



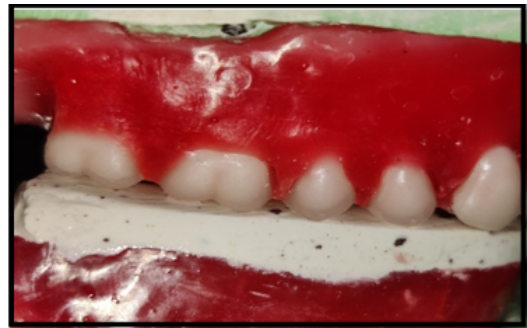**Figure 10:** Anteroposterior curve after functional movements (Left)



**Figure 11:** Mediolateral curve after functional movements (Right)



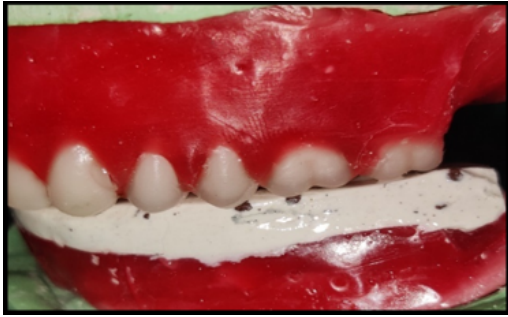
**Figure 12:** Mediolateral curve after functional movements (Left)



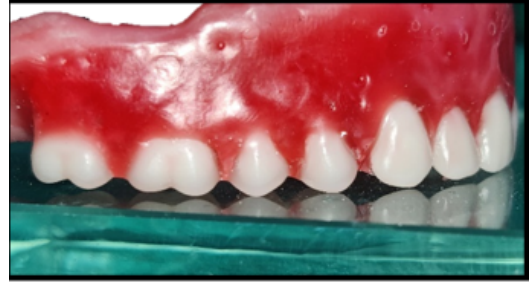**Figure 13:** Posterior teeth arrangement (Buccal cusps, Right)



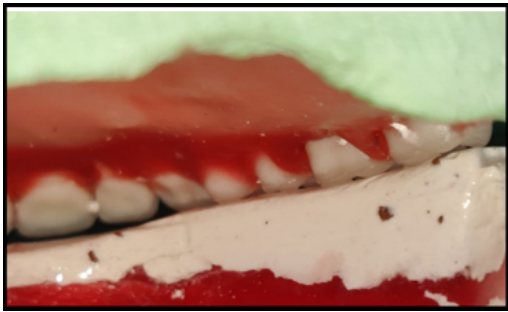
**Figure 14:** Posterior teeth arrangement (Palatal cusps)



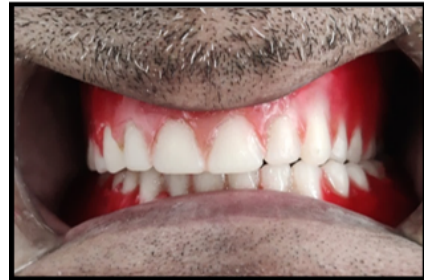**Figure 15:** Posterior teeth arrangement (Buccal cusps, Left)



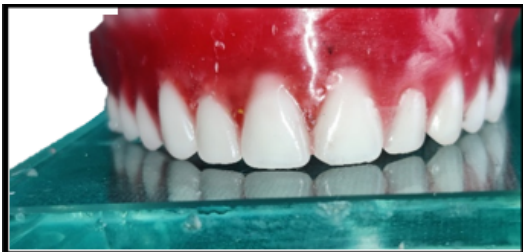**Figure 19:** Antero-posterior curve obtained (Right)



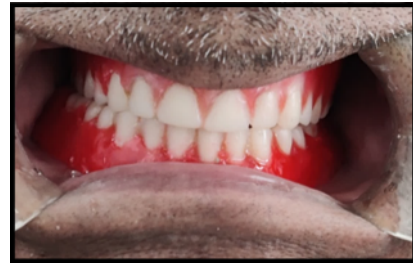**Figure 16:** Posterior teeth arrangement (Palatal cusps, Left)



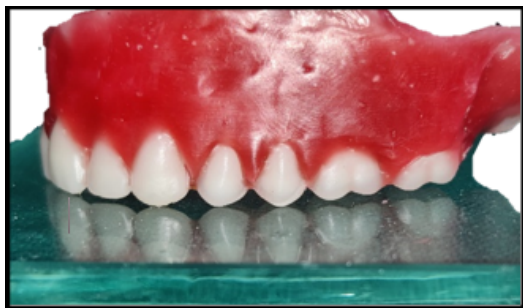**Figure 20:** Right lateral



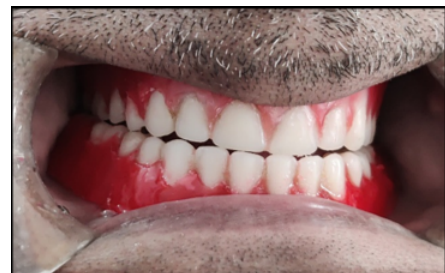**Figure 17:** Maxillary anterior teeth arrangement



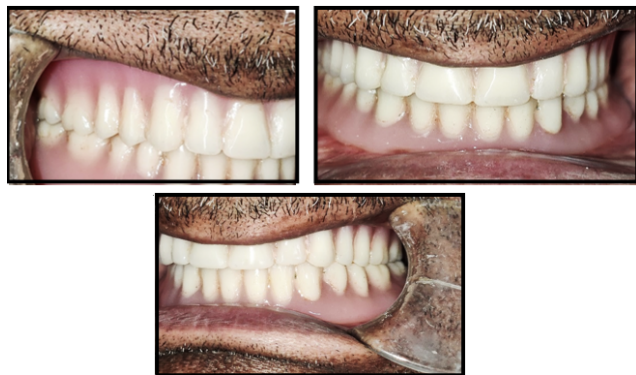**Figure 21:** Left lateral



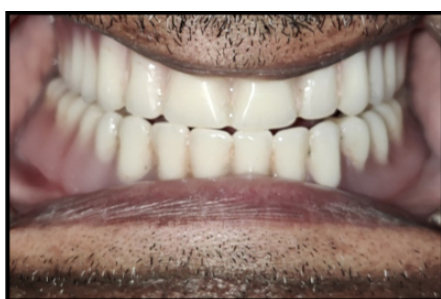**Figure 18:** Antero-posterior curve obtained (Left)



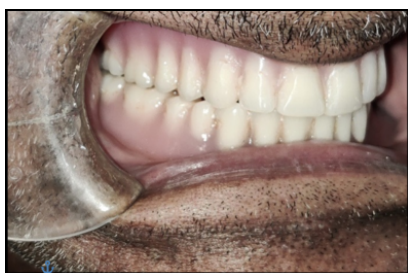**Figure 22:** Protrusive



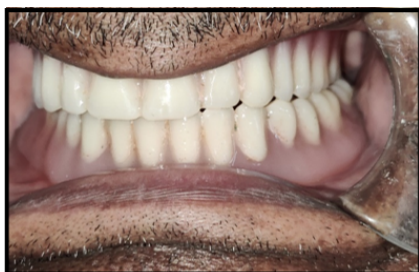**Figure 23:** Occlusion in centric position



**Figure 24:** Protrusive



**Figure 25:** Left lateral



**Figure 26:** Right lateral

movement that will happen between the fibrocartilage and the condyle.

This is in accordance with Bonwill's concept, which stated that protrusion of the mandible can be represented by a mandibular arc which is in constant contact with the maxillary arc without any separation.<sup>4</sup>

Fredrick. S. Meyer in 1957, published a paper on the Generated Path Technique<sup>5</sup> in which he discussed the principles and procedures associated with the same. He said that occlusal paths which are obtained through functionally generated path are in complete harmony with the condylar paths and the neuromuscular system.

In another paper of his in 1935, he defined balanced occlusion as one in which the teeth touch with equal pressure at three or more points of a triangle laid out on the occlusal surfaces of the teeth, which he referred to as a three-point balance.

The 9<sup>th</sup> edition of the Glossary of Prosthodontic Terms<sup>6</sup> defines balanced occlusion as the bilateral, simultaneous posterior occlusal contact of teeth in maximal intercuspal position and eccentric positions.

An article by Goldstein et al in 2021 on Complete Denture Occlusion<sup>7</sup> concluded that a bilaterally balanced occlusion has a positive impact on the residual alveolar ridge resorption and that it is the most favourable occlusal schemes for patients presenting with ridges that might compromise stability or retention.

The main disadvantage of this technique was the inability to do a facebow transfer.

However, the authors found it noteworthy that the same procedures can be followed, if necessary, on an articulator that can accept a facebow transfer. A double-blind study done by Nascimento et al<sup>8</sup> in 2004 concluded that the patients were more comfortable in dentures made without facebow transfer than in those made after doing a facebow transfer.

Another disadvantage as pointed out is that of unequalled pressure while registering the records using any of the functional methods. This can be a cause for creating a non-balanced occlusion, which might need chairside corrections during the trial phase.

#### Advantages

1. Easy to adapt to and execute the technique.
2. Can be trained to perform at an undergraduate level
3. No sophisticated articulators or tracing required.
4. Less number of visits compared to the usual facebow transfer, gothic arch tracing procedures.
5. A fairly well-balanced occlusion is obtained

#### Disadvantages

1. Centric relation cannot be verified.
2. Need a really stable denture base
3. Patients must have good neuromuscular coordination to participate in such a recording procedure

4. They must also be capable of following instructions.
5. Chances of fracture of index during the functional movements.

#### 4. Conclusion

The Paterson's technique is a time tested golden technique. It is easy to learn and execute and provides satisfactory results. This technique can be introduced in an undergraduate or a rural clinic set up where an adjustable articulator is not available.

In the present era of digital revolution in the field, a thorough knowledge of its evolution and adhering to the basic principles of Prosthodontics become all the more important. As Dr. A. H Paterson said "The prosthetist supplies a part that cannot possibly be incorporated in an articulator."<sup>1</sup>

#### 5. Source of Funding

None.


#### 6. Interest of Conflicts

None.

#### References

1. Paterson AH. Construction of artificial dentures. *Dent Cosmos*. 1923;65:683–4.
2. Paterson AH. Influences of mandibular movements on balanced occlusion. *J Am Dent Assoc*. 1922;15(6):1118–23.
3. Needles JW. Practical use of the curve of Spee. *J Am Dent Assoc*. 1923;10(10):918–27.
4. Bonwill WGA. Articulation and articulators. *Trans Am Dent Assoc*. 1864;26:76–9.
5. Meyer FS. The generated path technique in reconstruction dentistry: Part I: Complete dentures. *J Prosth Dent*. 1959;9:354–66. doi:10.1016/0022-3913(59)90064-2.
6. Ferro KJ, Morgano SM, Driscoll CF, Freilich MA, Guckes AD, Knoernschild KL, et al. The glossary of prosthodontic terms. *Glossary Prosthodont Terms*. 2017;117(5s):e1–105.
7. Goldstein G, Kapadia Y, Campbell S. Complete denture occlusion: Best evidence consensus statement. *J Prosthodont*. 2021;30(S1):72–7.
8. Nascimento DF, Patto RB, Marchini L, Cunha VD. Double-blind study for evaluation -oof complete dentures made by two techniques with and without face-bow. *Br J Oral Sci*. 2004;3(9):439–45.

#### Author biography

**Varsha Pathiyil**, Post Graduate  <https://orcid.org/0000-0003-1654-9818>

**Richa**, Post Graduate

**Irfanul Huda**, HOD

**Santosh Anand**, Senior Lecturer

**Preeti**, Post Graduate

**Cite this article:** Pathiyil V, Richa, Huda I, Anand S, Preeti. Functional balancing in complete dentures: Revisiting the paterson's technique- A case report. *IP Ann Prosthodont Restor Dent* 2023;9(4):228-234.