

Content available at: <https://www.ipinnovative.com/open-access-journals>

IP Annals of Prosthodontics and Restorative Dentistry

Journal homepage: <https://www.aprd.in/>

Case Series

Syndrome of trephined: Rehabilitation with PMMA alloplastic implant prosthesis-Case series

Sonam Yangchen¹, Parag Dua^{b1,*}, Thiruvalluvan Nagarajan¹, Saurav Kumar¹, Navdeep Singh¹

¹Dept. of Prosthodontics and Crown & Bridge, Armed Forces Medical College, Pune, Maharashtra, India



ARTICLE INFO

Article history:

Received 19-02-2023

Accepted 24-02-2023

Available online 21-03-2023

Keywords:

Syndrome of Trephined (SoT)

Craniectomy

Cranioplasty

ABSTRACT

Large defects of the skull leading to neurological defects and facial disfigurement can be traumatizing for the patient. Such defects can be rehabilitated using various biomaterials, polymethyl methacrylate being the most commonly used.

This is an Open Access (OA) journal, and articles are distributed under the terms of the [Creative Commons Attribution-NonCommercial-ShareAlike 4.0 License](#), which allows others to remix, tweak, and build upon the work non-commercially, as long as appropriate credit is given and the new creations are licensed under the identical terms.

For reprints contact: reprint@ipinnovative.com

1. Introduction

"Syndrome of the trephined" (SoT) is an uncommon consequence of craniectomy that involves a sunken skin flap above the calvarium bone defect. It exhibits neurological symptoms such as headaches, mental confusion, seizures, and focus impairments and is associated with disfigurement.¹ This syndrome is the result of the direct effect of atmospheric pressure onto the scalp and dura which causes closure of the subarachnoid space and reduces the perfusion pressure of the brain and may be accompanied with contralateral hemiparesis, hemispheric collapse and epilepsy.^{2,3}

This case series describes the rehabilitation of two such cases with cranioplasty using polymethyl methacrylate (PMMA).

2. Clinical Report 1

A 48-year-old female was referred by the maxillofacial surgery department for the fabrication of a cranial plate prosthesis. The patient had undergone craniectomy a year

ago due to intracranial hypertension. Recently her daughter observed a change of speech and inability to converse. A left fronto-temporo-parietal defect measuring 11cm supero-inferiorly and 13.5cm antero-posteriorly was observed. [Figure 1]

The borders of the defect were demarcated. Impression was made with irreversible hydrocolloid (Alginate,MDM,India),reinforced with orthoplast strips to support the impression material and poured in type 3 Dental stone (Kalstone)[Figure 2] on which the wax pattern was fabricated with modeling wax. Wax "try-in" was done and processed in heat cure clear PMMA for a long curing cycle. The prosthesis was retrieved, finished and polished after reconfirming the contour. Patient was taken up for cranioplasty by the department of maxillofacial surgery.

2.1. Cranioplasty

Patient was taken up for cranioplasty by the department of maxillofacial surgery. The plate was tried onto the defect intraoperatively and minor adjustments were done. Holes were drilled with a no $\frac{1}{2}$ round bur on the plate to enhance fibrous tissue growth. Titanium plates and screws were used to anchor the prosthesis [Figure 3].

* Corresponding author.

E-mail address: duaparag@gmail.com (P. Dua).

2.2. Patient review and follow up

24 hours post-operatively, there was very mild swelling and tenderness [Figure 4]. The subsequent follow ups were at 1 week, 1 month and 3 month intervals. Swelling had reduced and the patient was satisfied with her improved aesthetics. The patient's daughter reported an improvement in her speech, language and memory. The patient was able to speak her mother tongue fluently.

3. Clinical Report 2

A 21 year old male was referred by the neurosurgical team for fabrication of a cranial plate. He had undergone craniectomy two years back. He had suffered extradural haemorrhage with severely comminuted frontal bone bilaterally due to RTA. Patient was disoriented, confused and had weakness in upper and lower limbs. The fronto-parietal defect measured 25cm mesio-distally and 12cm supero-inferiorly [Figure 5].

3.1. Prosthetic fabrication

The extent of the defect was outlined. Impression compound was used to make a moulage and gauze pieces were embedded on the impression surface to help retain the final impression in alginate. Cast was poured in Type III dental stone (Kalstone). The cast was relieved in the marked area to a depth of approx. 1.5mm to compensate for the tissue overlying the defect. The contour of the surface was corrected by blocking out undercuts and excessive depths with plaster. Modelling wax (Pyrax, India) was used to fabricate the wax pattern which was tried in. Acrylization was done by long curing cycle.

The prosthesis was retrieved and perforated uniformly with round acrylic bur, finished and polished and delivered to the operation theatre 48 hours prior to allow gas sterilization.

3.2. Cranioplasty

The defect was exposed and cranial plate was secured using 1-0 prolene sutures with the adjacent bony margins [Figure 6].

Patient Review and Follow up

Post-op recovery was eventful. Patient was reviewed 24 hours, 1 week, 1 month and 3 months [Figure 7]. The motor skills of the patient had improved. He could walk without support and could also speak with comprehension. The patient is presently under regular follow up.

4. Discussion

Grant and Norcross first defined 'Syndrome of Trepined' as a collection of symptoms such as headache, dizziness, and pain/discomfort at the craniectomy site. It was so called 'SoT' because of the surgical instrument called

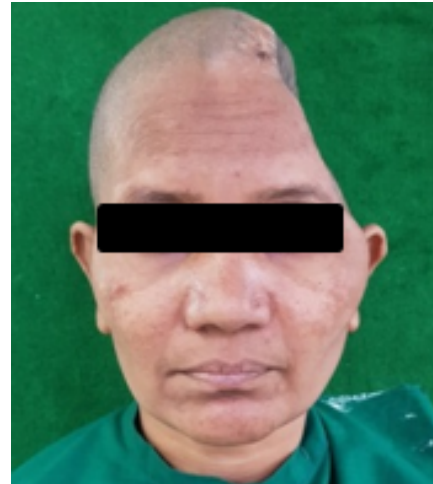

Fig. 1: Preoperative photograph showing left cranial bonedefect.

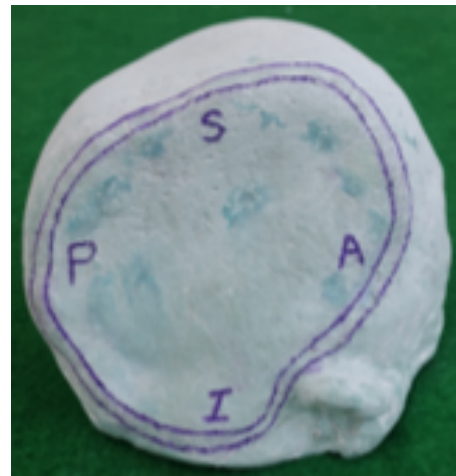


Fig. 2: Working cast

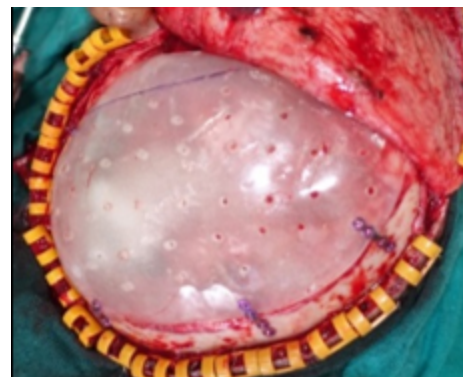


Fig. 3: Raised skin flap and prosthesis placement.

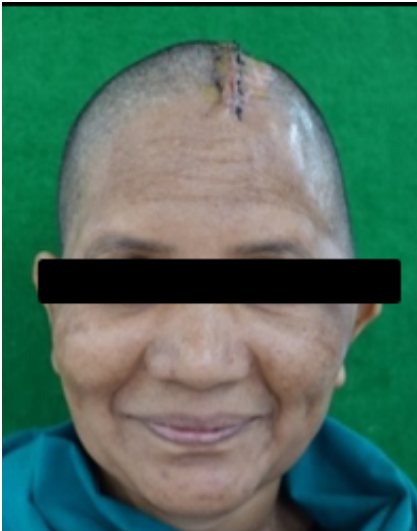

Fig. 4: 24 hours post-operative

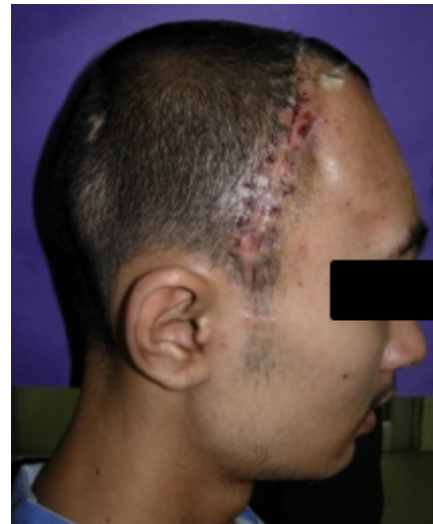

Fig. 7: 1 moth post-operative (Lateral view)

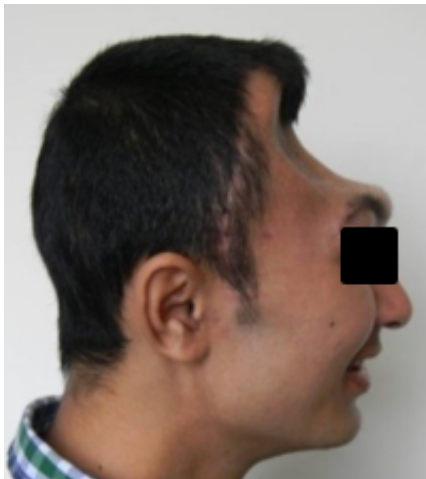

Fig. 5: Preoperative photograph (Lateral view)

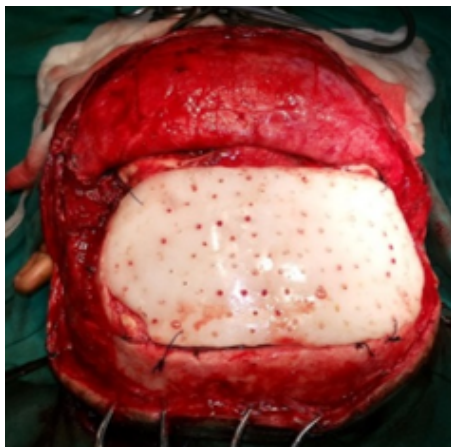


Fig. 6: PMMA plate fixation

‘trephine’ used to create cylindrical holes in the skull to relieve intracranial pressure. Since then, a combination of symptoms has been identified in a number of cases, with three main components: (1) Neurological changes that begin weeks to months post craniectomy, (2) Occurrence is independent of the location of the lesion, and (3) Clinical post cranioplasty improvement. The patient had exhibited symptoms closely related to the ‘SoT’. The Monroe-Kellie doctrine states the skull in a closed compartment with the brain parynchyme, cerebrospinal fluid and blood vessels in a state of equilibrium. Any disruption in any of these components leads to severe effect on the patient’s health. Increased Intracranial pressure is one of the leading causes for emergency craniectomy which affects the patients cognitive and sensorium functions post operatively. The most effective treatment in such cases is cranioplasty which places a cranial prosthesis in the patients defect area. Auto grafts are the gold standard for craniofacial skeletal reconstruction. However their use is limited by the availability of suitable donor site especially for large defects, additional expensive surgeries, tissue harvesting problems, donor site morbidity, patient discomfort, and infection at the recipient and donor sites, increased surgical time, and resorption of the graft. This led to the search of suitable alloplastic materials such as ‘Titanium’, ‘Stainless steel’, ‘PEEK’, ‘Tantalum’, and ‘Ceramic.’⁴ Their role in cranioplasty is to repair lost bone and improve the aesthetics. Among these, titanium and PMMA are the popular choices. Titanium and PEEK although biocompatible are expensive and require specialised lab equipment. PMMA has been used since 1940 by Zander to repair craniofacial defects and has the advantage of being molded preoperatively into the shape of the cranial defect and it is economical.⁵

The recent concept of digitization in the fabrication of the cranial implant prosthesis has yielded precisely fitting and accurate prostheses. The cone beam computed tomography can be utilised effectively for this. The ideal cranial implant material fabricated by CAD/CAM process would fit the cranial defect precisely and achieve complete closure, be radiolucent, resistant to infections, have good biomechanical properties and inexpensive.⁶

5. Conclusion

‘SoT’ is an uncommon, yet highly significant consequence that most commonly affects patients after neurotrauma and manifests as an unexplained loss in motor function following craniectomy. It requires early intervention to enhance treatment outcomes, and provide evidence-based advice for craniectomy patients. In spite of many new materials in the market, PMMA still remains a common choice for its reconstruction owing to its biocompatibility, easy accessibility, patient acceptance and less cost.⁷ In the present cases, the patients were diagnosed with ‘SoT’ and successfully treated with cranioplasty. The results and patient recovery following cranioplasty using PMMA cranial plate prosthesis were highly encouraging.

6. Conflict of Interest

None.

7. Source of Funding


None.

References

1. Sarov M, Guichard JP, Chibarro S, Guettard E, Godin O, Yelnik A, et al. Sinking skin flap syndrome and paradoxical herniation after hemispherectomy for malignant hemispheric infarction. *Stroke*. 2010;41(3):560–2.
2. Fodstad H, Love JA, Eksted J, Friden H, Liliequist B. Effect of cranioplasty on cerebrospinal fluid hydrodynamics in patients with the syndrome of the trephined. *Acta Neurochir (Wien)*. 1984;70(1-2):21–30. doi:10.1007/BF01406039.
3. Dujovny M, Aviles A, Agner C, Fernandez P, Charbel FT. Cranioplasty: cosmetic or therapeutic? *Surg Neurol*. 1997;47(3):238–41. doi:10.1016/s0090-3019(96)00013-4.
4. Parthasarathy J, Modeling. Custom Implants and its Future Perspectives in Craniofacial Surgery. *Ann Maxillofac Surg*. 2014;4(1):9–18.
5. Campolina AC, Maricevich P. Reconstruction of the skullcap with PMMA prototyped implant after decompressive craniectomy. *Braz J Implantol Health Sci*. 2020;2(1):1–9.
6. Thakur A, Chauhan D, Viswambaran M, Yadav RK, Sharma D. Rapid prototyping technology for cranioplasty: A case series. *J Indian Prosthodont Soc*. 2019;19(2):184–9.
7. Bandyopadhyay T, Thapliyal G. Dubey Reconstruction of Cranial Defects in Armed Forces Personnel - Our Experience. *MJAFI*. 2005;61(1):36–40.

Author biography

Sonam Yangchen, Resident

Parag Dua, Assistant Professor  <https://orcid.org/0000-0002-9467-1176>

Thiruvalluvan Nagarajan, Assistant Professor

Saurav Kumar, Assistant Professor

Navdeep Singh, Resident

Cite this article: Yangchen S, Dua P, Nagarajan T, Kumar S, Singh N. Syndrome of trephined: Rehabilitation with PMMA alloplastic implant prosthesis-Case series. *IP Ann Prosthodont Restor Dent* 2023;9(1):59-62.