

Content available at: <https://www.ipinnovative.com/open-access-journals>

IP Annals of Prosthodontics and Restorative Dentistry

Journal homepage: <https://www.aprd.in/>

## Case Report

# Prosthodontic management of completely edentulous young ectodermal dysplasia patient: A case report

Bhavika Makkar<sup>1</sup>, Neeta Pasricha<sup>1,\*</sup>

<sup>1</sup>Dept. of Prosthodontics, I.T.S Centre for Dental Studies and Research, Ghaziabad, Uttar Pradesh, India



### ARTICLE INFO

#### Article history:

Received 19-02-2023

Accepted 24-02-2023

Available online 21-03-2023

#### Keywords:

Ectodermal dysplasia

Edentulous

Completely edentulous

Patient

### ABSTRACT

Ectodermal Dysplasia is a hereditary disorder commonly associated with trichodysplasia (abnormal hair), onchodysplasia (abnormal nails), dyshidrosis (abnormal or missing sweat glands) and abnormal dentition. Due to ectodermal dysplasia, for missing, abnormally shaped, and mal-positioned teeth, a wide range of prosthetic options are available for oral rehabilitation. This case report represents prosthodontic rehabilitation of completely edentulous young Ectodermal Dysplasia patient using a characterized complete denture.

This is an Open Access (OA) journal, and articles are distributed under the terms of the [Creative Commons Attribution-NonCommercial-ShareAlike 4.0 License](https://creativecommons.org/licenses/by-nc-sa/4.0/), which allows others to remix, tweak, and build upon the work non-commercially, as long as appropriate credit is given and the new creations are licensed under the identical terms.

For reprints contact: [reprint@ipinnovative.com](mailto:reprint@ipinnovative.com)

## 1. Introduction

Ectodermal dysplasia (ED) includes hereditary disorders of ectodermal origin that involve defects of hair, nails, teeth, skin and glands. Adequate social and psychological development of young ED patients is dictated by how they look and feel as normal as possible.<sup>1–5</sup> The orofacial features associated with this syndrome include anodontia or hypodontia, abnormally shaped teeth, underdeveloped alveolar ridges, frontal bossing, a depressed nasal bridge, everted lips and sparse or thin hair.<sup>6–8</sup> The lack of tooth bud formation manifests as hypoplastic alveolar bone, leading to a reduced vertical dimension of occlusion. Therefore, an old-age appearance is common in affected individuals.<sup>9</sup> Since the dental manifestations of the ED syndromes persist throughout the life, dentists can anticipate close working with children, adolescents, and adults.

Prosthodontic Management of ED includes fixed, removable or implant supported prosthesis. Based on proper clinical assessment, age and cost considerations treatment plan is customized for every patient. Treatment

options for the present case were removable prosthesis or implant supported removable/fixed prosthesis but the patient opted for removable complete denture as she was reluctant for surgical phase of implant therapy. So in the present case report of young ectodermal dysplasia patient, removable complete denture prosthesis was planned with a technique of denture characterization that enhanced the overall aesthetics of the patient.

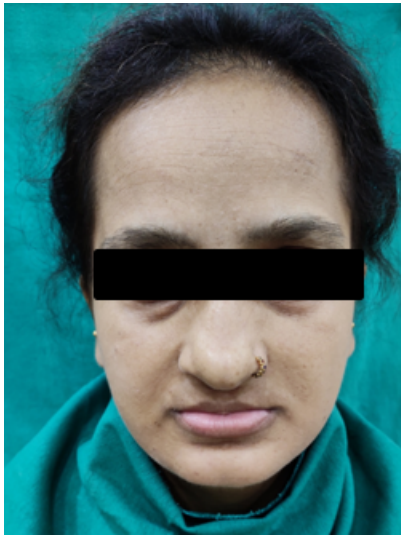For an aesthetic appearance of an artificial denture, characterization plays a significant role. Characterizing the denture bases can give a more natural and life-like appearance. Various techniques have been used to characterize the dentures such as using absorbent tissue paper with acrylic stains, externally staining the denture after polymerization by using various shades of gingival composite resin, involving extrinsic stains using the brush-on technique etc.<sup>10–12</sup> In this case report case a technique of characterizing the artificial teeth and denture base using acrylic based intrinsic stains to obtain optimum esthetics is discussed.

\* Corresponding author.

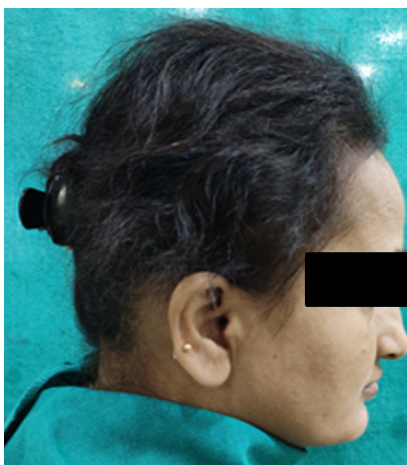E-mail address: [pasrichaneeta@yahoo.com](mailto:pasrichaneeta@yahoo.com) (N. Pasricha).

## 2. Case Report

A 29 year old completely edentulous female patient reported to the Department of Prosthodontics. Her chief complaint was inability to chew properly because of lack of teeth. Her past dental history revealed that she had delayed eruption of permanent dentition with multiple missing and abnormally shaped teeth. Due to carious lesions, extractions at very young age led to complete edentulism, five years ago. Extraoral examination revealed frontal bossing, pronounced chin, protuberant lips, reduced facial height, hyperpigmented skin around eyes, saddle nose, thin, sparse and dry hair on scalp and brittle, grossly deformed nails (Figures 1, 2 and 3). These findings matched typical features of hypohidrotic ectodermal dysplasia.

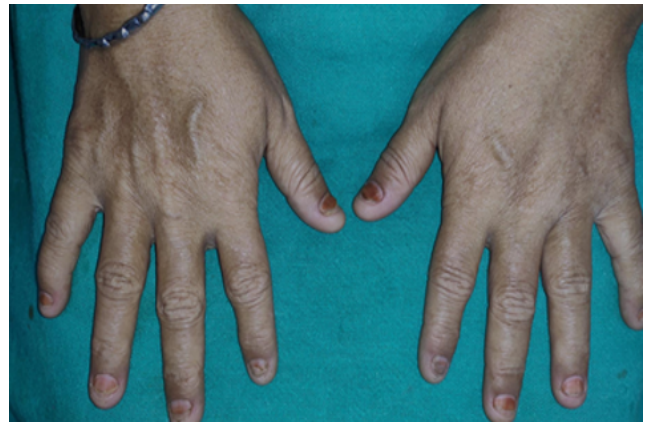

**Fig. 1:** Frontal view of patient

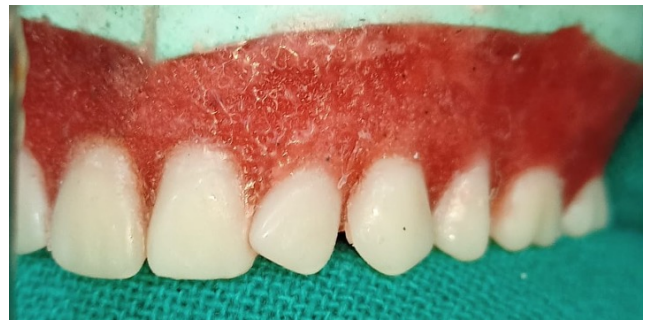

**Fig. 2:** Lateral view of patient

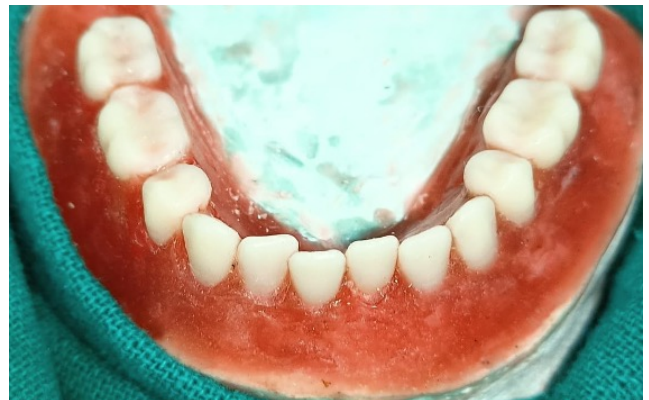Patient was aesthetically conscious and psychologically affected, thus she desired for her denture to be natural



**Fig. 3:** Brittle and grossly deformed nails



**Fig. 4:** Tilting and slight overlapping of lateral incisor



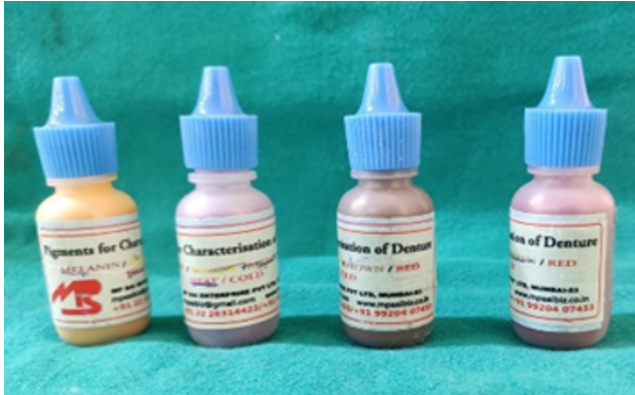**Fig. 5:** Misaligned mandibular central and lateral incisors

looking. She was told about the treatment procedure and she gave consent for the adding intrinsic stains to the denture base and aligning the artificial teeth in a modified way to give natural appearance.

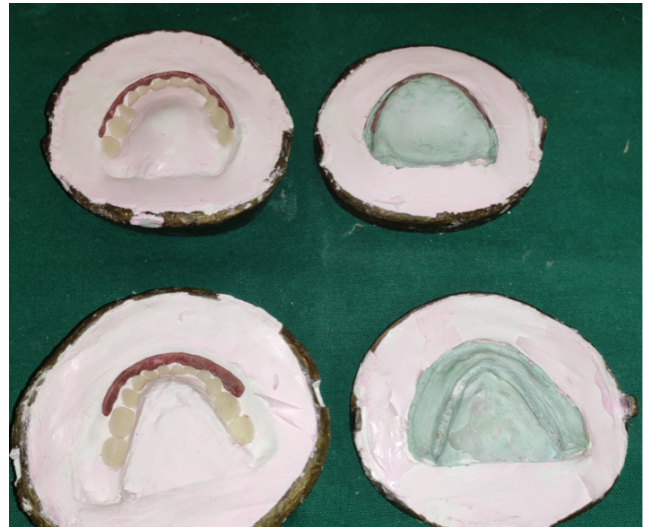
### 2.1. Clinical procedure

After detailed case history and examination, primary impressions, secondary impressions and jaw relations were recorded in conventional manner. Teeth arrangement was

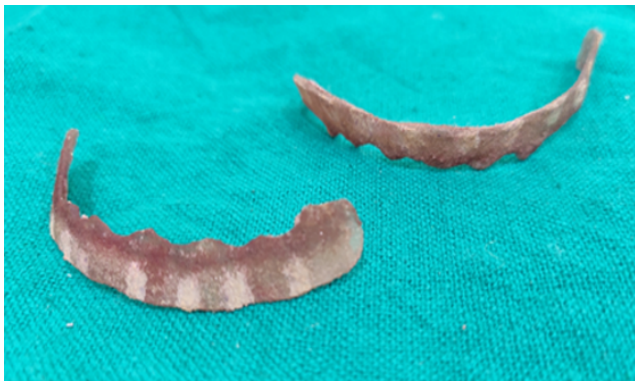



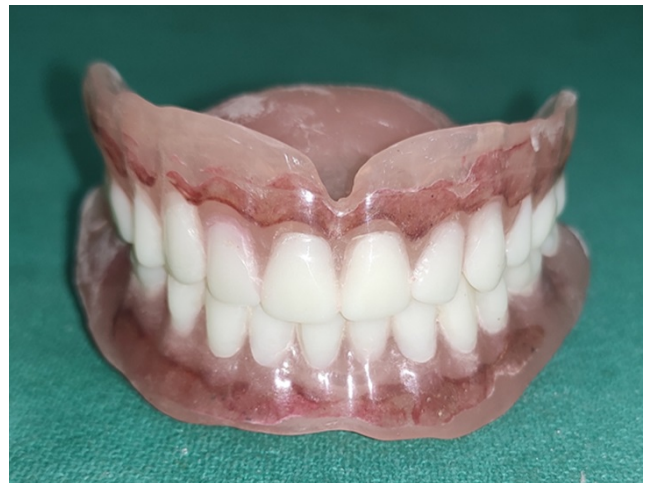**Fig. 6:** Acrylic based denture characterization pigments for intrinsic stains



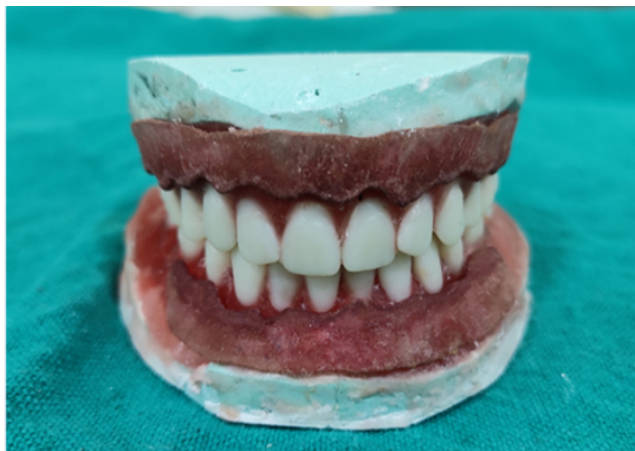**Fig. 9:** Alignment of self-cure acrylic color templates



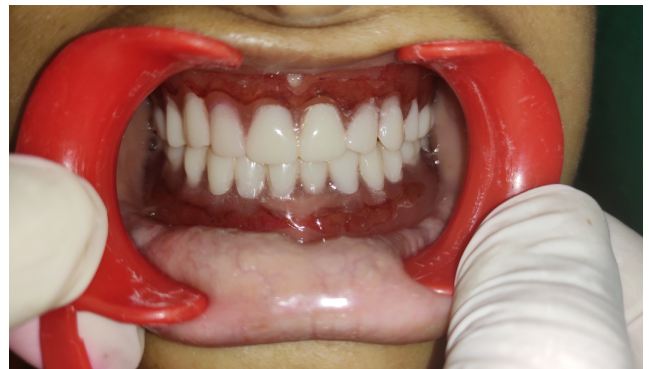**Fig. 7:** Stained self-cure acrylic templates



**Fig. 10:** Characterized complete denture with modified teeth arrangement



**Fig. 8:** Colored templates with scalloped borders adapted on waxed up cast



**Fig. 11:** Intraoral view of patient post denture insertion

characterized to enhance the aesthetics. Modified teeth arrangement was done instead of ideal and well aligned arrangement. Tilting of maxillary right lateral incisor, tilting and mild overlapping of maxillary left lateral incisor, slight labial inclination of canine and crowding of mandibular incisors was done. (Figures 4 and 5). Required alterations were done according to patient's desires and optimum aesthetics at the time of try-in.

After try-in, wax-up was completed, separating medium was applied on the waxed portion. Then, a thin layer of clear self-cure acrylic resin (DPI-RR cold cure, Mumbai, India) was applied on the carved contours according to the scalloping pattern of gingiva around teeth on maxillary and mandibular labial region where the staining was planned. After the auto-polymerization, the thin cured acrylic layer was delicately separated from the contours of waxed denture. This formed a template for staining the planned area. It was trimmed and finished with sandpaper to get a smooth surface and again adapted on the waxed denture.

Acrylic based intrinsic stain powder (Characterization Pigment, MP Sai Enterprises, Mumbai, Figure 6) was mixed in self-cure monomer with zero sized camel brush on a palette and after getting the desirable shade that matched with pigmentation of the oral mucosa of the patient, the mixed shade was painted on self-cured acrylic templates and kept aside. (Figures 7 and 8)

Flasking and dewaxing procedure was performed in conventional manner. After dewaxing, separating medium (KBI cold mould seal, KBI products, New Delhi) was applied on the moulds. Painted acrylic templates were placed and adaptation was checked over the labial and buccal gingival portion of maxillary and mandibular moulds. (Figure 9) After checking the fit of templates, they were again removed to be added later at the time of packing. A thin layer of heat cure acrylic denture base (DPI Heat Cure, Dental products of India, Mumbai, India) resin dough was adapted on the labial and buccal gingival surface in the mould. The stained self-cured acrylic templates were placed and fixed over the thin layer of heat cure resin in the mould.

Packing of rest of the mould space was completed with the heat cure acrylic denture base resin dough and flask was closed under the hydraulic pressure clamp. Following bench curing, the packed molds were cured in conventional manner. Then the denture was retrieved and finished and polished in conventional manner. (Figure 10) The polished dentures were delivered to the patient. (Figure 11)

### 3. Discussion

Oral rehabilitation of patients with ectodermal dysplasia is necessary for improving their facial profile and aesthetics. When implant therapy is indicated in such patients, the main problem is insufficient bone; if bone atrophy progresses in these already alveolar deficient patients, implant placement may not be possible without bone grafting.

The most common treatment plan is removable prosthesis. Removable partial or complete dentures require regular adjustments and should be replaced when a decreased vertical dimension of occlusion and an abnormal mandibular posture is detected. In patients with ectodermal dysplasia, dryness of the oral mucosa and the underdeveloped maxillary tuberosities and alveolar ridges are challenging for resistance and stability of the dentures.<sup>9</sup> When fabricating dentures for these patients, care should be taken to obtain a wider distribution of occlusal loads by extending the denture base as much as possible.

Since the dentogenic concept was introduced, it brought revolution into aesthetics of artificial dentures. Modification in the arrangement of artificial teeth like altering the direction of the long axis of teeth helps in accentuation of natural effects that can give more life-like appearance to complete dentures. Surface characterization or extrinsic staining technique which involves application of pigments on the surface layer of the denture can also be done for denture characterization. But surface tints do not have sufficient abrasion resistance of the stains.<sup>13–16</sup>

In the mentioned technique, the thickness and color of the outer layer of the denture base will affect the extent of tint. The same degree of characterization to that of painted self-cure acrylic template can be expected, if thin outer layer of clear/transparent heat cure resin is used. If the outer layer of heat cure denture base resin is pink, the tinting has to be slightly darker on the template.<sup>10</sup>

As the tinted self-cured acrylic templates are embedded in the heat cure resin, it is difficult to distinguish whether a foreign pigmented template is added or characterization is given in the heat cure resin itself. Because the pigmented self-cured acrylic templates are integrated deeply in the denture and therefore will not be easily affected or removed during finishing and polishing procedure. Self-cure resin undergoes changes in physical structure and appearance due to changing oral temperature and pH of saliva.<sup>17</sup> Since it is not in direct contact with oral fluids, no such problem is supposed to encounter.

Limitation of placing the self-cured acrylic template over the first thin layer of heat cure is to maintain it in its fixed position in the denture base is very critical. The bulk of dough can displace the self-cured templates from its position; therefore these templates were fixed in position over the first thin layer of heat cure. So, skilled and careful handling is needed during positioning of the pigmented template and packing of heat cure acrylic dough.[18]

### 4. Conclusion

Treatment of young completely edentulous ectodermal dysplasia patients with removable partial or complete denture is an acceptable, available and cost effective modality, which improves function, speech, esthetics and psychosocial condition. As much prosthesis is necessary

to be suitable for better function, equally it should be satisfactory enough for the patient in terms of aesthetics. Characterization of denture base and tooth arrangement can produce excellent results with more natural smile like appearance. Advantages of skillful tinting with intrinsic stains are that, they are incorporated deeply in the denture and the operator has control over extent of the tint.

## 5. Conflict of Interest

None.

## 6. Source of Funding

None.

## References

1. Tanner BA. Psychological aspects of hypohidrotic ectodermal dysplasia. *Birth Defects Orig Artic Ser.* 1988;24(2):263–75.
2. Nowak AJ. Dental treatment for patients with ectodermal dysplasias. *Birth Defects Orig Artic Ser.* 1988;24(2):243–52.
3. Jones JE, Yancey JM, Snawder KD. Psychological concomitants of treating the dentally handicapped adolescent: report of case. *ASDC J Dent Child.* 1978;45:313–8.
4. Nussbaum B, Carrel R. The behavior modification of a dentally disabled child. *ASDC J Dent Child.* 1976;43(4):225–61.
5. Levin LS. Dental and oral abnormalities in selected ectodermal dysplasia syndromes. *Birth Defects.* 1988;24(2):205–27.
6. Bixler D, Saksena SS, Ward RE. Characterization of the face in hypohidrotic ectodermal dysplasia by cephalometric and anthropometric analysis. *Birth Defects.* 1988;24(2):197–203.
7. Champlin TL, Mallory SB. Hypohidrotic ectodermal dysplasia: A review. *J Ark Med Soc.* 1989;86(3):115–7.
8. Clarke A. Hypohidrotic ectodermal dysplasia. *J Med Genet.* 1987;24(11):659–63.
9. Hekmatfar S, Jafari K, Meshki R, Badakhsh S. Dental Management of Ectodermal Dysplasia: Two Clinical Case Reports. *J Dent Res Dent Clin Dent Prospects.* 2012;6:108–120.
10. Pattanaik S, Pattanaikb. Internal Characterization of Denture Base by Using Acrylic Stains and Tissue Paper. *J Indian Prosthodont Soc.* 2011;11(3):202–4.
11. Zimmerman DE, Pomerantz JM, Sanfacon DG, Berger AW. Denture esthetics (III), Denture base color. *Quintessence Int Dent Dig.* 1982;13(7):747–58.
12. Power JL. Brush - on technique in natural coloring of cured cross-linked plastic artificial denture materials. *J Prosthet Dent.* 1953;3:350–3. doi:10.1016/0022-3913(53)90011-0.
13. Lagdive S, Darekar A, Lagdive S. Review: Characterization of Denture Bases -Redefining Complete Denture Esthetics. *Int J Health Care Biomed Res.* 2012;1:16–20.
14. Srivastava R, Choukse V. Characterization of Complete Denture. *Int J Dent Clin;*2011(1):56–9.
15. Winkler S, Vernon H. Coloring acrylic denture base resins. *J Prosthetic Dent.* 1978;40(1):4–7.
16. Wood G. Investing in the upper half of the flask. *J Prosthetic Dent.* 1955;5(2):205.
17. Sanjeevi J, Rizwaan N, Subhashini MHR. Dimensional changes of self-cure acrylic when subjected to alcohol, listerine, and chlorhexidine. *Drug Invention Today.* 2019;12(2):289–92.

## Author biography

**Bhavika Makkar**, Senior Lecturer

**Neeta Pasricha**, Professor and Head  <https://orcid.org/0000-0003-4069-2972>

**Cite this article:** Makkar B, Pasricha N. Prosthodontic management of completely edentulous young ectodermal dysplasia patient: A case report. *IP Ann Prosthodont Restor Dent* 2023;9(1):48-52.