

Content available at: <https://www.ipinnovative.com/open-access-journals>

IP Archives of Cytology and Histopathology Research

Journal homepage: <https://www.achr.co.in/>

Case Report

Flexible partial denture- material science and a case report

Surbhi Sharma^{1,*}, Kamaldeep Sharma¹, Kirtika¹, Ashish¹, Ravudai Singh¹,
Sumit Chopra¹

¹Dept. of Prosthodontics and Crown Bridge, Genesis Institute of Dental Sciences & Research, Firozpur, Punjab, India



ARTICLE INFO

Article history:

Received 28-05-2022

Accepted 06-08-2022

Available online 30-09-2022

Keywords:

Flexible dentures

Injection moulding

Valplast

ABSTRACT

Partially edentulous patients need treatment to restore missing teeth and surrounding structures. Partial dentures are mode of treatment for replacing some of the missing teeth in either arch. Partial dentures are made of variety of materials. Some are made of only acrylic material and some are metal framework with acrylic extensions to replace missing teeth. Recently flexible materials are in use to fabricate tooth supported prosthesis. These materials has advantage over conventional metal and acrylic dentures as there is no metal clasp around the tooth, they are more retentive giving life like prosthesis and are translucent by which they match the color of underlying mucosa.

It is seen that patient acceptance is more for flexible partial dentures as they are less likely to cause mucosal irritation and pain.

This is an Open Access (OA) journal, and articles are distributed under the terms of the [Creative Commons Attribution-NonCommercial-ShareAlike 4.0 License](https://creativecommons.org/licenses/by-nc-sa/4.0/), which allows others to remix, tweak, and build upon the work non-commercially, as long as appropriate credit is given and the new creations are licensed under the identical terms.

For reprints contact: reprint@ipinnovative.com

1. Introduction

Partially edentulous patients for which a successful removable partial denture is being fabricated, there should be a harmony between occlusal pattern of the natural teeth with the temporomandibular joints, and this same occlusal pattern should be incorporated into the artificial teeth. This procedure gives comfort, efficiency, and longevity of the removable partial denture. Denture can be made of acrylic or combination of metal framework and acrylic over it. Many of the patients choose removable partial dentures due to factors like cost and physiology.¹ Recently flexible dentures are introduced made of thermoplastic nylon resin called polyamides. They are used in professional dentistry since 1954. Polymerization shrinkage encountered in conventionally heat cured Poly (methyl methacrylate) led to the development of a special injection-molding technique.² Flexible dentures are fabricated by this

technique and are used to replace one or more missing teeth either in the upper or lower jaw. There are various advantages of nylon dentures which are unique: ultra-thin, light, very flexible and virtually unbreakable. They are more comfortable for chewing and speaking than other materials.

1.1. Material science

The thickness of material varies from 0.6 mm to 1.8 mm. Therefore nylon denture is lighter than standard dental prosthesis and even more lighter if compared to metal cast partials. Flexible dentures make patient forget about the bulky feeling that made wearing partial dentures so uncomfortable. The clasps of flexible dentures are also made up of thermoplastic material with excellent esthetics.³ The nylon base makes the partial denture prosthesis flexible makes it unbreakable if accidental fall to the ground during use. Due to its unbreakable feature, some of the brands (such as Valplast) offer lifetime warranty to the flexible material only. This warranty does not include prosthetic teeth which

* Corresponding author.

E-mail address: surbhisharma12025@gmail.com (S. Sharma).

can be made of resin or porcelain. Thermoplastic nylon resin doesn't contain bisphenol (BPA) which makes it the most biocompatible material for building partial dentures. Polyamides dentures is therefore a valid alternative for patients who are allergic to acrylic resin or metals such as cobalt, chromium and nickel used in framework fabrication of traditional cast partial dentures.

1.2. Patient acceptance

Flexible partial dentures are more comfortable and adapt to the constant movement in the mouth as they are soft materials. Flexible removable partial dentures are better options especially when there are bilateral undercuts or high esthetic requirements.⁴ They do not cause any gingival irritation or inflammation. They are aesthetically acceptable as there are no metal clasps around the natural teeth which make them virtually invisible. This material has translucency which picks up underlying tissue tones, making it almost impossible to detect in the mouth.⁵ The color of the denture base material blends with the underlying natural color of the gums. With these partial denture in mouth chewing and speaking is easier, it prevents the remaining natural teeth from shifting. Due to its flexibility, it helps in ease of insertion and removal from mouth in cases of deep undercuts or tori.⁶

1.3. Care and maintainance

Flexible partial dentures are more resistant odor and to stain than traditional acrylic dentures but they also need to be properly cleaned and maintained on daily basis. Standard partial dentures while not wearing, it is better to put it in a glass of water or in a damp little towel as if denture gets dried, it tends to change the shape. With flexible dentures this risk doesn't exist as they have tendency to go back to their original shape. Anyway, it is always advisable to keep flexible partials hydrated using proper liquid. Sonic denture cleaner can be used to remove food particles from the dentures, alternative to that is to put the prosthesis under the running water to remove food debris.⁷ Although it is said that flexible prosthesis is virtually unbreakable and high impact resistant but the acrylic teeth that attached to it are made of acrylic or porcelain are not. Therefore it should be carefully handled during insertion, removal and cleaning.

2. Case Report

A 51 year old female patient reported to the Department of Prosthodontics, with the chief complaint of difficulty in chewing food. General physical examination was done along with intraoral examination. Intraoral examination showed presence of teeth no. 11, 12, 13, 17, 21, 22, 27, 31, 32, 33, 34, 41, 42, 43, 44 and 48. The teeth were firm with attrition.

2.1. Treatment plan

Partial maxillary flexible denture and mandibular cast partial denture was planned.

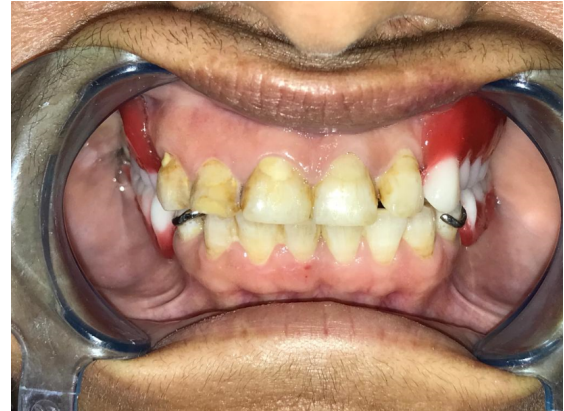

Fig. 1: Try in – frontal.

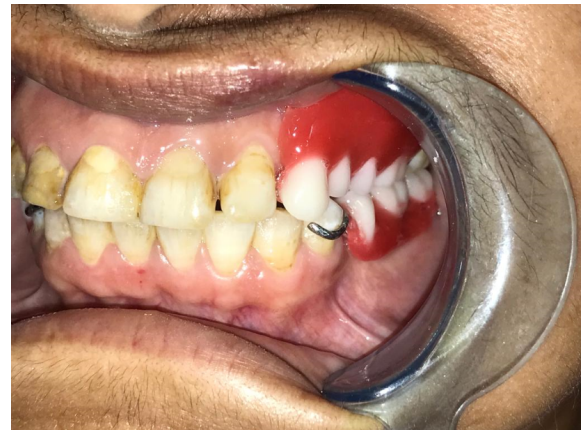

Fig. 2: Try in lateral 1.

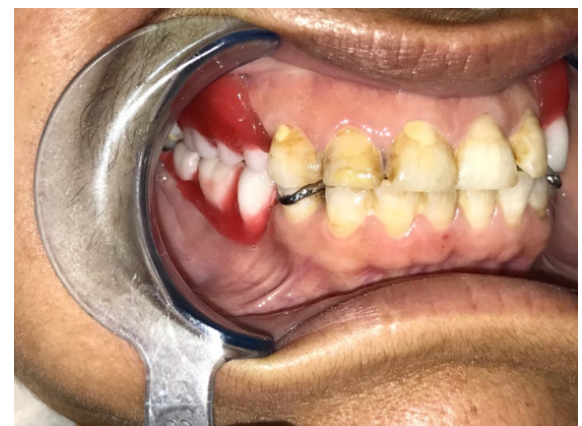

Fig. 3: Try in lateral 2.

2.2. Procedure

Alginate impressions are taken at first appointment and diagnostic casts are prepared. Casts were mounted on surveyor and analyzed for undercuts and marked for further use. The diagnostic casts were then articulated on semi adjustable articulator by facebow transfer and centric relation record inter arch space was evaluated. After considering appropriate treatment plan, amount of time and financial aspect the patient it was decided to fabricate flexible partial denture in maxillary arch and cast partial denture in mandibular arch. After taking consent from the patient, treatment was started and patient was informed about hygiene and maintenance. Primary impressions were made of both the arches with alginate and primary casts were made and special trays were prepared over it with self-cure acrylic resin. Definitive impressions were then made using custom trays, border moulding was done with low fusing compound & final impressions were made using polyvinyl siloxane light body impression material. Final casts were made. Maxillomandibular relationships were then recorded with check bite method. Definitive casts were mounted on semi – adjustable articulator. Shade selection of acrylic teeth was done and artificial teeth were arranged. Dentures were tried in patient's mouth and she was satisfied with esthetics, phonetics and function. After approval by patient upper dentures were processed in injection system and lower denture by lost wax technique. Upper denture is fabricated in valplast material⁸ and lower denture was fabricated in metal and heat cure acrylic resin. Final denture was finished and polished. For insertion of upper denture, place the denture in warm water then insert in patient's mouth so as to increase the flexibility of material. This will permit very smooth initial insertion and good adaptation in patient's mouth.⁹ Occlusion was evaluated and adjusted, denture borders are evaluated and postoperative instructions on how to insert and remove was given. Instruction on adequate oral hygiene maintenance was also given. After minor adjustment during post insertion follow up visits, the patient was placed on one year recall.

3. Conclusion

Removable partial dentures are important part of prosthetic dentistry as they are cheaper option for patients. Modern dentistry is now inclined towards flexible material for removable partial dentures (RPDs) because it is more retentive and have no metallic clasps so that patient acceptance is more. Flexible material eliminates the invasive procedures and provides a prosthesis which is comparatively less bulky, more retentive, more esthetic and to a large extent clinically unbreakable after accidental fall. The partially edentulous arches encountered a special challenge in fabrication of partial dentures due to various paths of placement, tilted teeth and deranged occlusion. Flexible

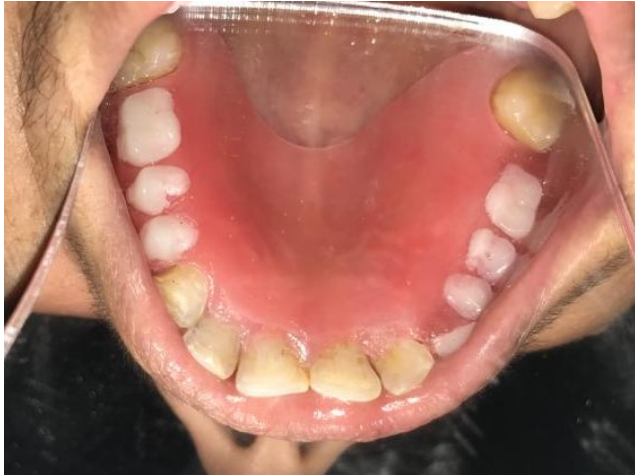

Fig. 4: Intra oral view of flexible partial denture.

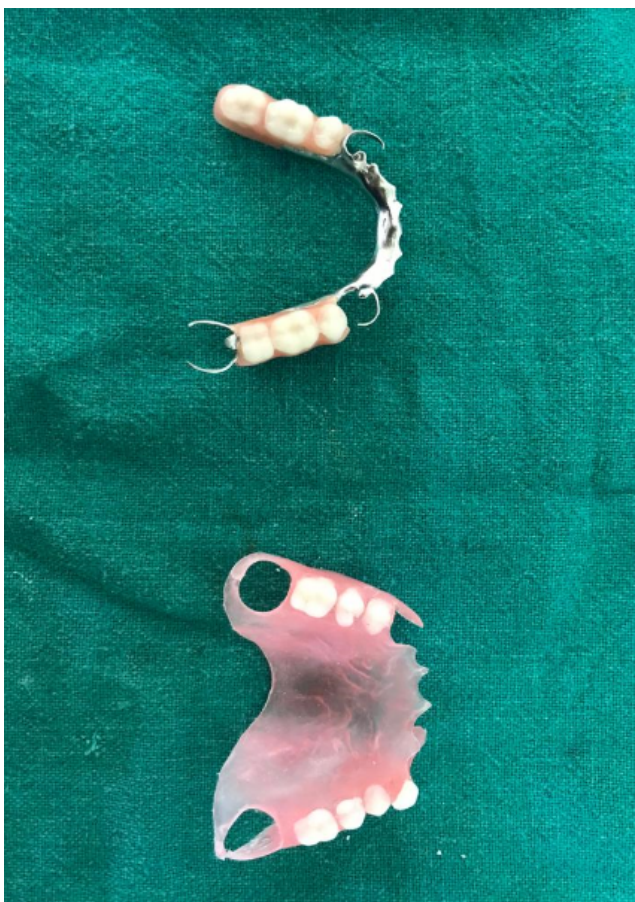

Fig. 5: Final upper flexible and lower cast partial denture.

dentures will stand in a superior option in fulfilling the various patients demand for more retentive and aesthetic treatment needs.

4. Source of Funding

None.


5. Conflict of Interest

None.

References

1. Thakral GK, Aeran H, Yadav B, Thakral R. Flexible partial dentures-A hope for the challenged mouth. *Peoples J Sci Res.* 2012;5(2):55–9.
2. Thumati P, Padmaja S, Raghavendra RK. Flexible dentures in prosthodontics—an overview. *Indian J Dent Advancements.* 2013;5(4):1380–6.
3. Vikhe DM, Saraf V, Gangadhar SA, Bhandari A, Vikhe G, Tambe SD, et al. Flexible denture-a flexible substitute for rigid denture. *Pravara Med Rev.* 2016;8(1):30–2.
4. Sharma A, Shashidhara HS. A review: Flexible removable partial dentures. *J Dent Med Sci.* 2014;13(12):58–62.
5. Prashanti E, Jain N, Shenoy VK, Reddy JM, Shetty BT, Saldanha S, et al. Flexible dentures: A flexible option to treat edentulous patients. *J Nepal Dent Assoc.* 2010;11(1):85–7.
6. Handa M. Flexible dentures: a boon in compromised conditions. *Indian J Dent Advancements.* 2015;7(2):132–6.
7. Mylonas P, Milward P, Mcandrew R. Denture cleanliness and hygiene: an overview. *Br Dent J.* 2022;233(1):20–6.
8. Gaikwad S, Yeshwante B. A Case Report of flexible Denture. *IOSR J Dent Med Sci.* 2018;17(8):44–6.
9. Kaira LS, Dayakara HR, Singh R. Flexible denture for partially edentulous arches. *J Dentofacial Sci.* 2012;1:39–42.

Author biography

Surbhi Sharma, 3rd Year Post Graduate  <https://orcid.org/0000-0003-0891-5806>

Kamaldeep Sharma, 3rd Year Post Graduate

Kirtika, 1st Year Post Graduate

Ashish, 1st Year Post Graduate

Ravudai Singh, Professor

Sumit Chopra, Reader

Cite this article: Sharma S, Sharma K, Kirtika, Ashish, Singh R, Chopra S. Flexible partial denture- material science and a case report. *IP Arch Cytol Histopathology Res* 2022;8(3):189-192.