

Content available at: <https://www.ipinnovative.com/open-access-journals>

IP Annals of Prosthodontics and Restorative Dentistry

Journal homepage: <https://www.aprd.in/>

Case Report

Prosthetic management of flabby ridge using customized prefabricated metal mesh custom tray impression technique: A case report

Arpit Sikri^{1,*}, Jyotsana Sikri²

¹Dept. of Prosthodontics, Crown & Bridge and Oral Implantology, Bhojia Dental College and Hospital, Baddi, Himachal Pradesh, India

²Dept. of Conservative Dentistry & Endodontics, Bhojia Dental College and Hospital, Baddi, Himachal Pradesh, India



ARTICLE INFO

Article history:

Received 08-02-2022

Accepted 22-02-2022

Available online 16-03-2022

Keywords:

Complete denture

Customized metal mesh impression tray

Displaceable tissue

Fibrous ridge

Flabby ridge

Hyperplastic tissue

Impression technique

Individual tray

Modified custom tray

Undisplaced tissue

ABSTRACT

Flabby ridge is defined as an excessive mobile soft or fibrous tissue on the superficial aspect of the residual alveolar ridge. It is usually a common clinical finding affecting the maxillary and mandibular edentulous ridges; in particular, the maxillary anterior region. It can be attributed to a number of reasons i.e. long-term denture wearers, natural teeth opposing an edentulous ridge etc. The treatment options or management of flabby ridges generally include a surgical and a non-surgical approach. The non-surgical approach involves the implant-retained prostheses and fabrication of conventional removable dentures using various modified impression techniques. Prosthetic management of the patients with flabby ridge is a testing situation for the prosthodontist. Although, retention, support, and stability are the important principles defining the success of the complete denture, the same can be affected in unconventional situations like flabby ridge. The incorporation of the conventional impression techniques may lead to an unstable and an unsatisfactory denture. Henceforth, various impression techniques have been proposed in literature to overcome such issues and recording the entire denture bearing area in function along with flabby tissue in an undisplaced form. This case report portrays an innovative and practical yet simple modified impression technique using the incorporation of a customized prefabricated metal mesh into the custom tray i.e. single step impression technique along with the polyvinyl siloxane impression material for managing and minimizing the displacement of a flabby ridge in the maxillary arch and ultimately ensuring a well-fitting prosthesis.

This is an Open Access (OA) journal, and articles are distributed under the terms of the [Creative Commons Attribution-NonCommercial-ShareAlike 4.0 License](#), which allows others to remix, tweak, and build upon the work non-commercially, as long as appropriate credit is given and the new creations are licensed under the identical terms.

For reprints contact: reprint@ipinnovative.com

1. Introduction

The replacement of the missing teeth and associated alveolar structures with a prosthesis helps to primarily achieve the objectives of a complete denture (CD) i.e. restoration of esthetics, function and comfort.¹ The success or performance of the complete denture relies on an accurate impression making and reproduction of the entire functional denture bearing as well as the limiting areas, easily achievable in conventional situations. Such a record helps to achieve maximum retention, support, and stability,

which are the important pillars for a successful complete denture.²

Impression making is the most basic and the most important requirement for a successful CD both esthetically and functionally. The mucosa overlying the residual alveolar ridge is usually around 1.5 – 2 mm in thickness and helps in providing better soft tissue support.³ It can be of variable thickness and mobility and is easily distorted during the impression making. Such distortion can be duplicated causing inflammation and instability and ultimately compromises the function as well as appearance of the complete denture patient.⁴

* Corresponding author.

E-mail address: arpitsikri@gmail.com (A. Sikri).

Unfortunately, in unconventional situations i.e. a flabby or fibrous denture bearing area, certain problems or complications may arise. The problems mainly encountered in patients with flabby ridge are loss of stability or instability of CD during function, poor retention of the dentures, and common complaints of pain or looseness associated with a complete denture.⁵ Such problems can be attributed to easy distortion of the flabby tissues during impression making. This may lead to difficulty in attaining the basic principles of retention, support and stability in CD. This becomes an arduous challenge for the prosthodontist in managing such situations.⁶

Flabby ridge or flabby tissue is an excessive, movable tissue, which becomes displaceable due to deposition of the fibrous tissue.⁷ It is a superficial area of mobile soft tissue and primarily occurs due to replacement of alveolar bone by hyperplastic soft tissue.⁸ Flabby ridge can also be termed as a displaceable, fibrous, and excessively movable ridge. It commonly affects maxillary (upper) and mandibular (lower) anterior edentulous region but frequently observed in the maxillary anterior region¹⁻³. The prevalence of flabby ridge is found to be 24% in the edentulous maxilla and 5% in the edentulous mandible.⁹

A number of reasons may be attributed to the development of the flabby ridges. Historically, flabby ridge in the upper anterior region was a feature of 'combination syndrome', first identified by Kelly in the year 1972.¹⁰ It usually occurs when natural teeth oppose an edentulous ridge i.e. maxillary CD opposing the mandibular anterior natural teeth in the absence of a proper posterior occlusal support. It can also occur in long-term denture wearers i.e. patients not removing the dentures overnight and can even be a result of uncontrolled or unplanned dental extractions.¹¹

Histologically, the flabby tissue is composed of mucosal hyperplasia along with loosely arranged fibrous and denser collagenized connective tissue. Varying amounts of metaplastic cartilage and bone in the soft tissue has been reported in literature.¹²

Management of the flabby ridge involves various treatment approaches or options. Broadly, such modalities may include a surgical and a non-surgical approach.¹³ The surgical approach or the surgical intervention requires surgical removal of the flabby or the fibrous tissue using a scalpel or injection of the sclerosing agent prior to the prosthodontic therapy. The removal of the fibrous ridge reduces the vestibular height and ultimately eliminates the vestibular area leaving a firm ridge but unfortunately reduces the stability of the complete denture. Although, ridge augmentation using bone grafts can be undertaken but the outcome is still questionable.¹⁴ The other treatment approach involves implant retained fixed or removable prosthesis. This involves the dental implant taking support from the underlying bone, which is already minimal in such

situations. The limitations of the surgical as well as implant intervention include patient's will to undergo the surgical treatment, age and medical condition of the patient, time involved in completion of the procedure, inconvenience, discomfort, risk of surgical complications, dental implant failures, predictability of the treatment and economics involved.¹⁵ Moreover, the surgical removal also increases the bulk of the material in construction of CD and reduced thickness of the underlying stress absorbing mucosa leading to trauma to the underlying tissues. This makes conservative management as the treatment of choice. The non-surgical or the prosthodontic approach involves the conventional prosthodontics without the surgical intervention. As per the prosthodontist's approach, a poor ridge is better than no ridge. This involves fabrication of a complete denture over the flabby ridge using appropriate impression materials and techniques. Apart from the various impression approaches, balancing of the occlusal forces is also employed during management of the flabby tissues.¹⁶

A plethora of impression techniques and materials has been discussed in the literature. This involves impression of the flabby tissue taking adequate support from the tissue and at the same time not displacing it.¹⁷

While considering the various impression techniques to record the flabby ridges, it becomes significant to know that impressions in CD can be categorized as – mucostatic, mucocompressive and selective pressure impression. A mucostatic or nondisplacive technique will record the undistorted denture bearing areas at rest. A mucocompressive or the displacive impression technique compresses the underlying tissues. In practice, the selective pressure impression technique is generally followed and involves the use of escape holes, windows and wax relieve to reduce the hydraulic pressure and leads to selective displacement of the denture bearing areas. The ultimate aim of impression making in flabby ridges involves an appropriate impression technique, which will be required to compress the nonflabby tissues to obtain optimal support, and, at the same time, will not displace the flabby tissues.¹⁸

Liddelow¹⁹ advised the use of two different impression materials i.e. plaster over the flabby tissues and zinc oxide eugenol impression paste over the normal tissues with two custom built trays. Osborne²⁰ or the palatal splinting technique involved the use of two different impression materials and impression trays to separately record both the flabby as well as the normal tissues. Watson²¹ described the 'window impression technique' where a custom tray is fabricated with a window or opening over the flabby tissues. Watt and McGregor²² described a technique where impression compound is applied to a modified custom tray. The thermoplastic properties of this material are then manipulated to simultaneously compress the 'normal tissues', while avoiding displacement of the 'flabby tissues' using the same material and impression tray. Over this

manipulated impression compound, a wash impression with zinc oxide eugenol impression paste is made. Lynch and Allen²³ revisited this technique by using polyvinyl siloxane (PVS) impression material. Magnusson et al.²⁴ described a technique where two impression materials are used in a custom tray using zinc oxide eugenol impression paste over the normal tissues and impression plaster over the flabby area. Crawford et al.²⁵ described a two-tray impression technique where two trays are fabricated and impression is recorded with two different materials and is then oriented intraorally. Zafrullah Khan²⁶ came with an idea of using single custom made impression tray with window at the flabby areas and taking impression of the flabby tissue using impression plaster. William H Filler²⁷ described a technique using two trays. The second tray is keyed on the first tray. Light body material is used in the first tray as a corrective wash material. Hobkirk technique²⁸ involved the use of a single custom tray. Border moulding is done in the usual manner and impression is made with heavy bodied addition silicone. The areas of movable tissue are cut out and relief holes are made. Wash impression is made with light body impression material. Jone D Walter²⁹ recorded the healthy denture bearing tissues with zinc oxide eugenol impression paste and the undisplaced fibres of tissue with impression plaster. Allan Mack 'Splint Method' technique³⁰ was taken into account in case of the tissues being excessively and exceptionally flabby. Loosely fitting tray or a special tray made with heavy relief over the flabby area is taken. Plaster is mixed and applied over the flabby area to a thickness of about 3 mm and is allowed to set. Tray is filled with second mix of plaster and the impression is made. The initial coating of the flabby areas thus acts as a 'splint'. It gets removed with the second impression. Some authors³¹ also suggested a modified fluid wax impression technique, which involves a functional impression technique using fluid wax that captures the primary and the secondary load bearing areas without distortion of the residual ridge. Labban N³² enumerated a modified window technique along with polyvinyl siloxane impression material for the management of the flabby tissues.

There has been a lot of controversy about the most suited impression technique for the management of the flabby ridges. A combination of the mucostatic impression technique, double spacer, and multiple relief holes over the flabby ridge area has been discussed in literature.³³

The present case report describes an innovative and practical yet simple modified impression technique using the incorporation of a customized prefabricated metal mesh into the custom tray i.e. single step impression technique along with the polyvinyl siloxane impression material for managing and minimizing the displacement of a flabby ridge in the maxillary arch and ultimately ensuring a well-fitting prosthesis.

2. Case Report

A 60-year old completely edentulous male patient reported to the Department of Prosthodontics, Crown & Bridge and Oral Implantology, with a chief complaint of an ill-fitting upper denture i.e. loose upper denture and difficulty in eating food, since 3 years previously. Patient had insignificant past medical history. Past dental history of the patient revealed that the patient was wearing a complete denture for the past 15 years.

Intraoral examination revealed a flabby maxillary anterior i.e. canine-to-canine edentulous region involving part of rugae and a partially conventional mandibular edentulous ridge [Figure 1]. The flabby ridge was determined by applying pressure over the tissue using a T-burnisher and back of the intraoral mirror. On applying pressure, blanching of the tissue was noticed [Figure 2].

The patient was informed about various treatment options i.e. surgical intervention, implant supported fixed and removable prosthesis, and conventional prosthodontic rehabilitation. After explaining the various prosthetic treatment options to the patient and keeping in view his non-willingness for the surgical modalities along with his financial constraints, it was decided to fabricate the removable complete dentures as the choice of prosthodontic rehabilitation. A treatment plan was designed for fabricating a complete denture involving a modified impression technique for the flabby tissue in the maxillary anterior region and conventional impression technique for the mandibular edentulous ridge. This involved recording the flabby tissue in an undisplaced form and remainder of the basal seat area in a functional form with maximum retention, support, and stability, ultimately leading to minimal displacement of the denture during function. Informed consent was taken from the patient.

2.1. Procedure

The preliminary steps of complete denture fabrication remained the same.

1. Preliminary impressions of the maxillary and mandibular arches were made using medium fusing impression compound (Hiflex Impression Compound, Prevest DenPro Limited, Jammu, India) [Figure 3]. This was followed by arbitrary scraping of the impression compound followed by impression with a thin mix of irreversible hydrocolloid (Zelgan 2002, Dentsply India Pvt. Ltd., Haryana, India) [Figure 4]. The flabby tissue area was marked with an indelible pencil [Figure 5].
2. Beading and boxing of the primary impressions was done (MAARC Dental, Maharashtra, India) to obtain a proper primary cast using type II dental plaster (GypRock plaster, Rajkot, Gujarat, India). The outline of the area of flabby ridge was transferred from the

impression to the preliminary cast [Figure 6].

3. A double thickness wax spacer was applied over the region of flabby tissue to provide proper relief over this area [Figure 7]. After adaptation of the wax spacer (MAARC Dental, Maharashtra, India) [Figure 8], a prefabricated metal mesh (MAARC– CE Reinforcement Golden Mesh, Shiva Products, Thane, India) [Figure 9] was customized (cut into a small section) and adapted over the area of flabby ridge. This was followed by fabrication of a custom (individual) tray using autopolymerizing acrylic resin (DPI RR Cold Cure, Dental Products of India, Mumbai, India) [Figure 10]. The occlusal surface of the maxillary individual tray shows the customized prefabricated metal mesh in place [Figure 11].
4. Border moulding was performed using low fusing green stick compound (Pinnacle Tracing Sticks, Dental Products of India, Mumbai, India) [Figure 12]. Even after the border moulding, the metal mesh was intact without any distortion [Figure 13]. Wax spacers were removed from the individual trays after the final border moulding [Figure 14]. The metal mesh maxillary individual tray was evaluated in the patient's mouth [Figure 15]. Final impressions were made using medium body polyvinyl siloxane elastomeric impression material in maxillary ridge (Aquasil Ultra Medium, Dentsply India Pvt Ltd, Mumbai, India) and using zinc oxide eugenol wash impression (DPI Impression Paste, Dental Products of India, Mumbai, India) as a conventional method in mandibular ridge [Figure 16]. The occlusal surface of the maxillary individual tray signified that the final impression was properly flown from the metal mesh area [Figure 17].
5. Beading and boxing of the final impressions (MAARC Dental, Maharashtra, India) was done to retrieve well-formed master casts.
6. Definitive casts were poured using type III gypsum product i.e. dental stone (GypRock stone, Rajkot, Gujarat, India) [Figure 18].
7. After the definitive casts were obtained, temporary denture bases and occlusal rims were fabricated [Figure 19].
8. Orientation jaw relation was recorded using facebow (Hanau™ Springbow, Whip Mix, Kentucky, USA) followed by transfer to the semiadjustable articulator (Hanau™ Wide-View, Whip Mix, Kentucky, USA).
9. Tentative jaw relations were carried out following the facebow transfer [Figure 20]. After recording the centric relation record, the casts were mounted in a semiadjustable articulator. The artificial teeth were adjusted and teeth arrangement was done following the ideal principles.
10. Waxed-up trial denture was assessed intra-orally, to verify the function, fit, and esthetics, before its

processing [Figure 21]. This was followed by proper sealing of the trial denture base to the definitive casts followed by de-articulation from the articulator [Figure 22].

11. The flasking procedure was carried out for both the arches [Figure 23].
12. The dewaxing process was completed [Figure 24]. After the application of tin foil substitute (DPI Heat Cure Cold Mould Seal, Dental Products of India, Mumbai, India), a prefabricated metal mesh (MAARC – CE Reinforcement Golden Mesh, Shiva Products, Thane, India) [Figure 25] was selected and adapted to the master cast. The already adjusted prefabricated metal mesh was checked on the maxillary cast for any last minute corrections in its adaptation [Figure 26]; and the denture was packed, pressed, and processed in the conventional manner (DPI Heat Cure, Dental Products of India, Mumbai, India)
13. The processed dentures were retrieved and cleaned using an ultrasonic cleaner.
14. The dentures were finished, polished and tried in the patient's mouth for evaluation of appropriate esthetics and occlusion [Figure 27]. After the necessary occlusal corrections, the prostheses i.e. removable maxillary & mandibular complete dentures were delivered. [Figure 28]
15. Patient was given instructions following the insertion of the complete dentures. Patient was evaluated after 3 recall visits i.e. after 24 hours, 1 week, and 1 month, respectively. Patient was satisfied with the esthetics, phonetics & function of the removable complete dentures [Figure 29].

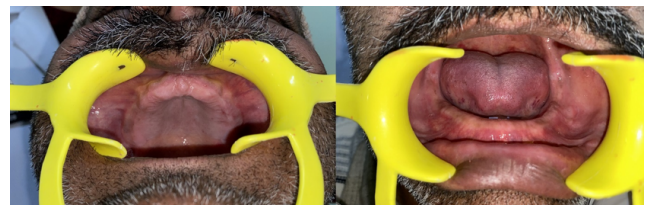

Fig. 1: Edentulous maxillary & mandibular edentulous ridge

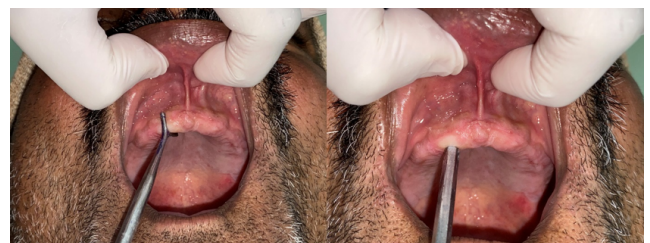

Fig. 2: Flabby anterior maxillary edentulous ridge – pressure application using T-burnisher & back of the intraoral mirror

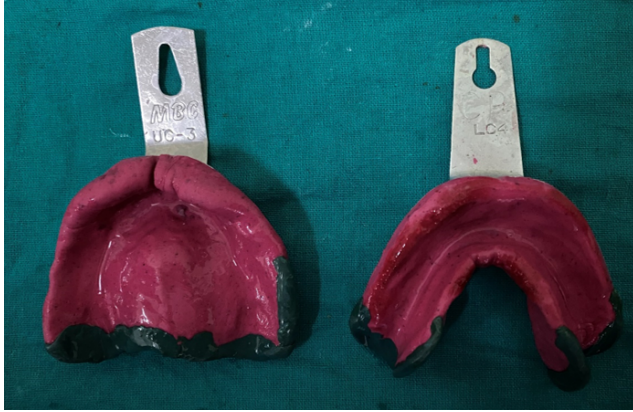

Fig. 3: Preliminary impressions – maxillary & mandibular

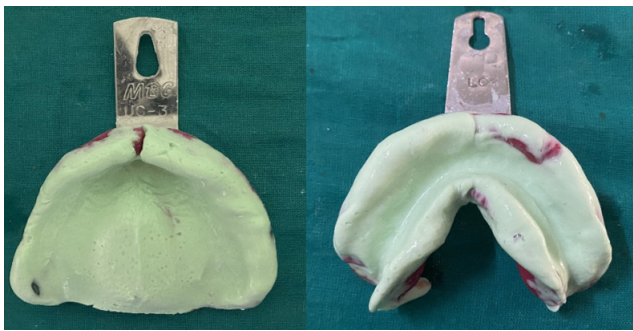

Fig. 4: Corrective impressions – maxillary & mandibular

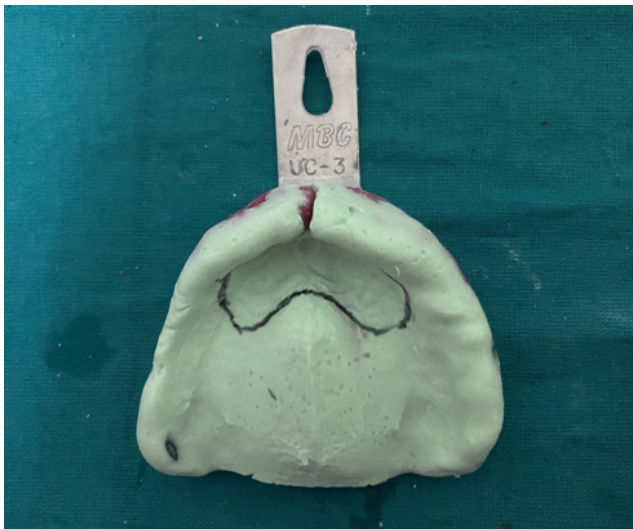


Fig. 5: Outline of the flabby ridge area – maxillary corrective impression

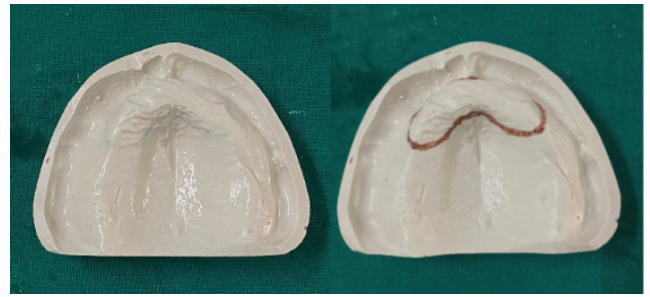


Fig. 6: Preliminary cast & outline of the flabby ridge area - maxillary

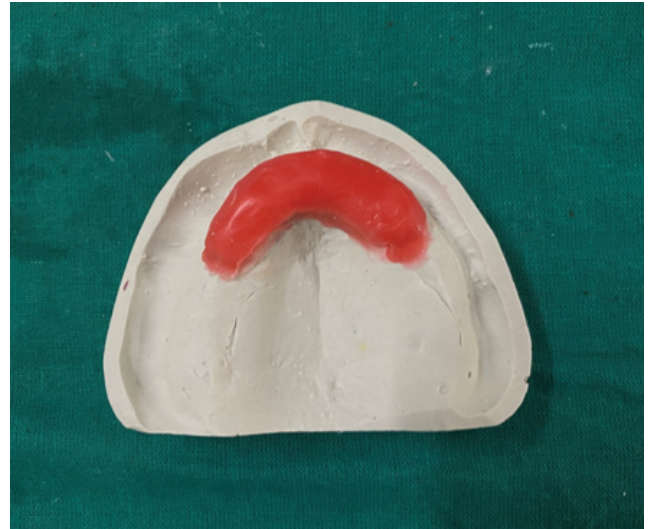

Fig. 7: Double thickness wax relief – maxillary

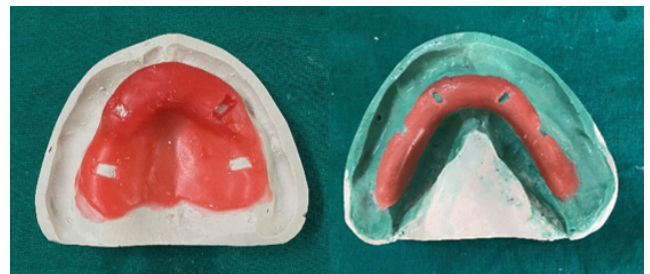

Fig. 8: Wax spacer adaptation – maxillary & mandibular

3. Discussion

The main objectives of complete denture rehabilitation involves the restoration of function, appearance, comfort, and maintenance of the health of the patient. An accurate impression making is an important factor determining the stability and retention of the prosthesis. This can be very well achieved in the conventional situations.³⁴

In unconventional situations like in case of flabby ridge, the residual alveolar bone or the edentulous ridge becomes resilient and replaced by a hyperplastic, fibrous or

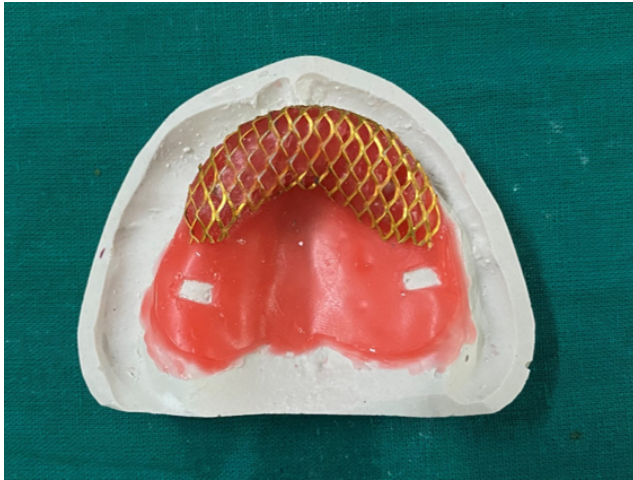


Fig. 9: Prefabricated metal mesh (customization & adaptation) – maxillary

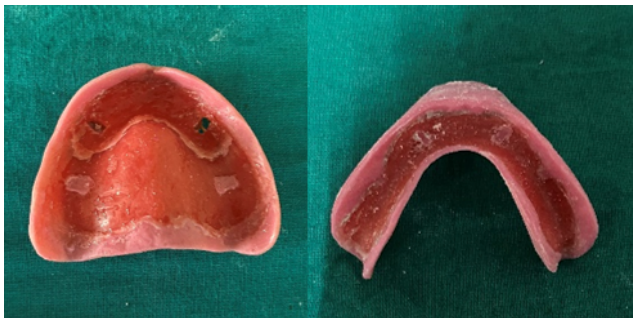


Fig. 10: Custom trays – maxillary & mandibular

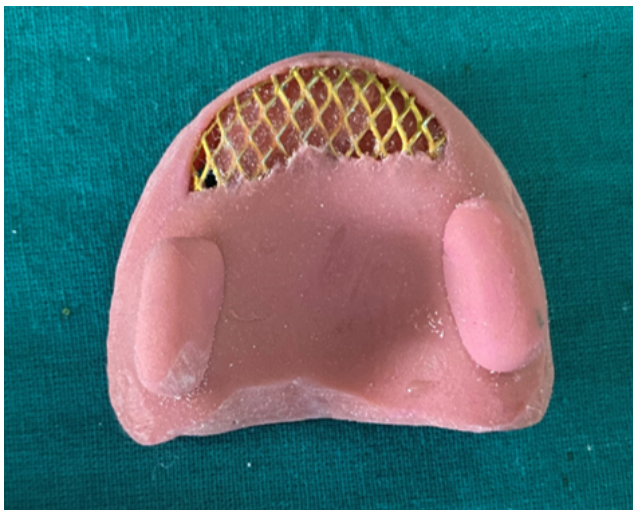


Fig. 11: Custom tray (maxillary) – customized prefabricated metal mesh in place

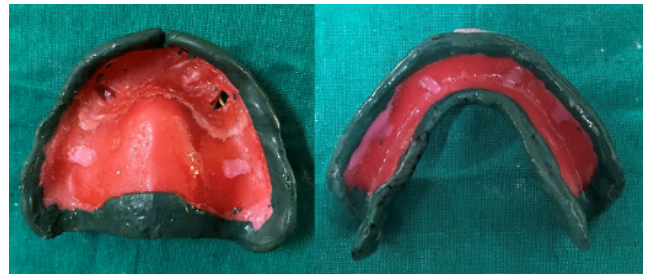

Fig. 12: Border moulding – maxillary & mandibular

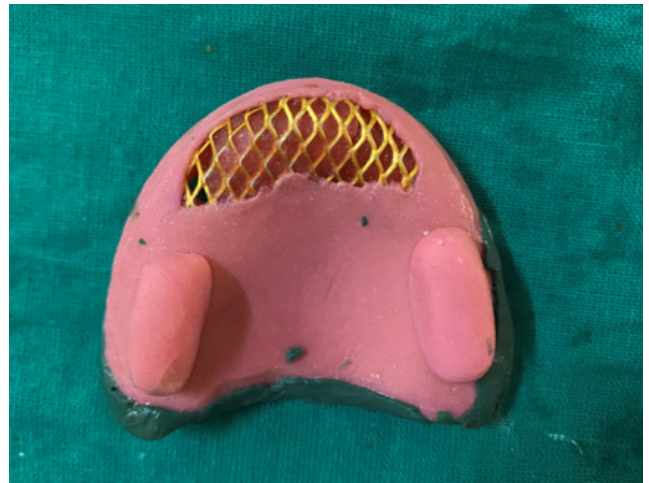


Fig. 13: Border moulding (maxillary) - customized prefabricated metal mesh in place

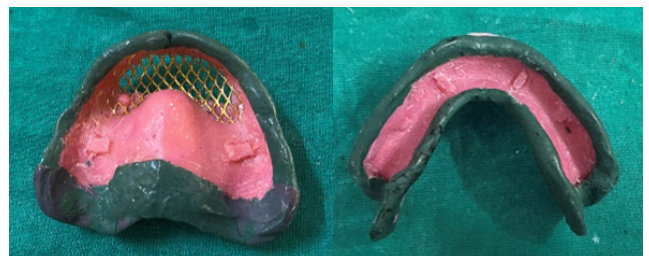

Fig. 14: Wax spacer removal after completion of border moulding

excessively movable soft tissue with limited bone support. Flabby tissue or the hypermobile ridge tissue is commonly seen in the edentulous maxillary anterior region or can overly an atrophic knife-edge mandibular ridge. A couple of reasons are linked to the fibrous tissue i.e. excessive occlusal loading on the residual maxillary ridge due to an unstable occlusal relationship or an unusual arrangement in the mouth. This leads to resorption of the residual alveolar bone followed by development and replacement of the bone with the flabby tissue. Such areas provide limited support for the complete denture. In addition to this, the forces of mastication can displace the flabby tissue, leading to change in the denture positioning and loss of peripheral seal.³⁵

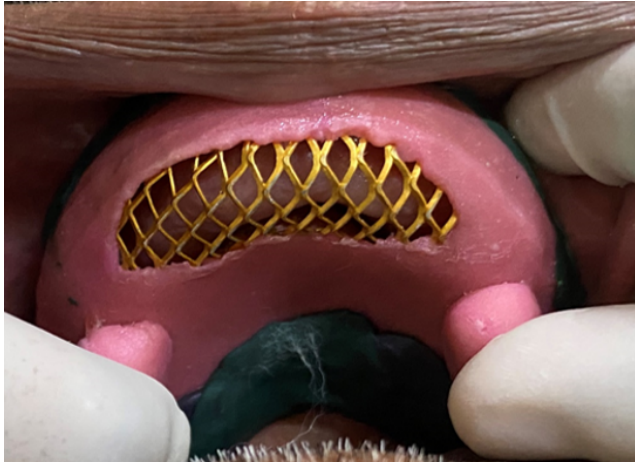


Fig. 15: Metal mesh custom tray – evaluation in patient’s mouth

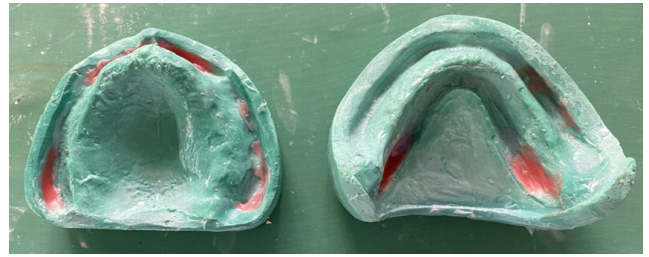


Fig. 18: Definitive casts – maxillary & mandibular

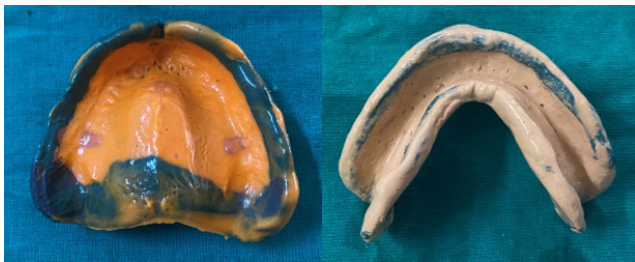

Fig. 16: Final impressions – maxillary & mandibular

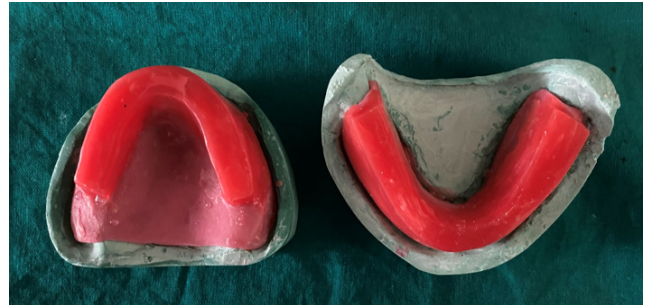

Fig. 19: Occlusal rims – maxillary & mandibular

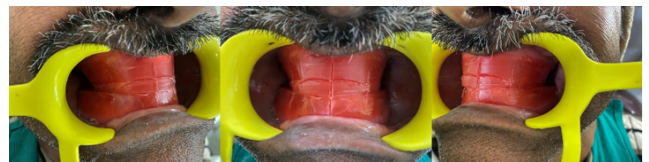

Fig. 20: Jaw relations

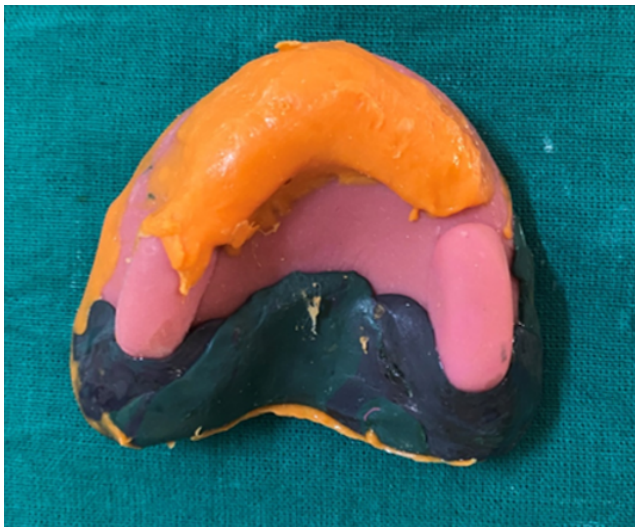

Fig. 17: – Final impression (maxillary) – occlusal aspect of the individual tray

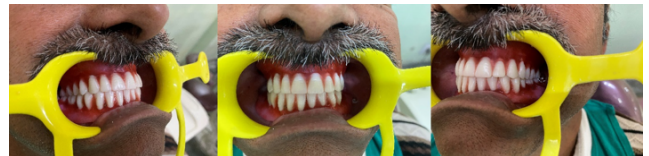

Fig. 21: Waxed-up try in

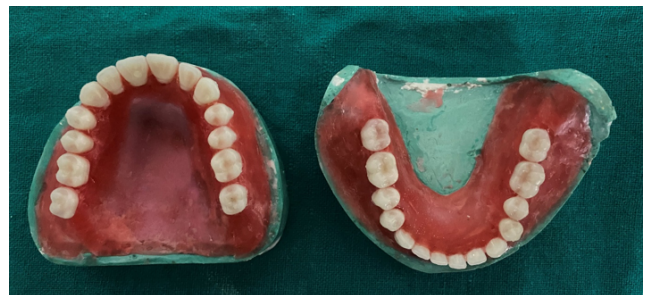

Fig. 22: Dearticulation - Dearticulated definitive casts

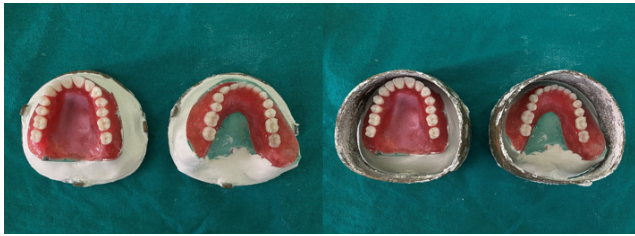

Fig. 23: – Flasking procedure

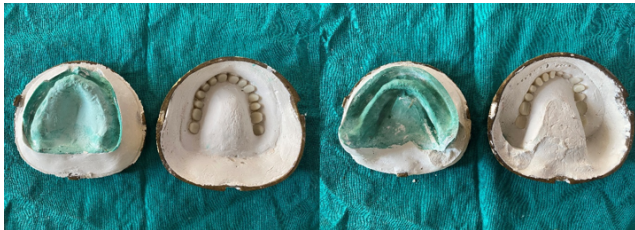

Fig. 24: – Dewaxing procedure




Fig. 25: Selection of a prefabricated metal mesh

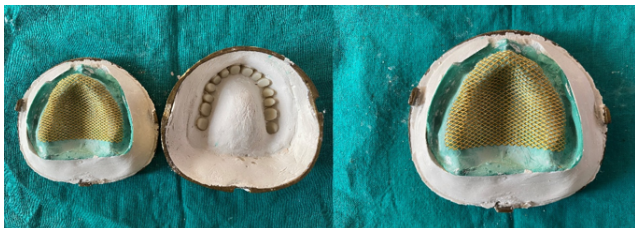

Fig. 26: Adaptation of prefabricated metal mesh

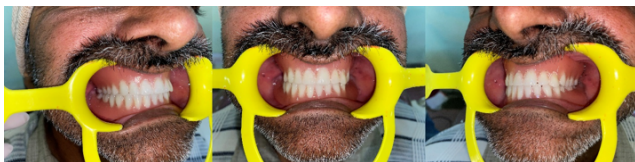

Fig. 27: Complete dentures – in patient’s mouth

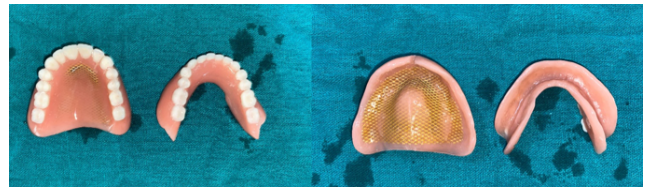


Fig. 28: – Complete dentures – occlusal surface & intaglio surface

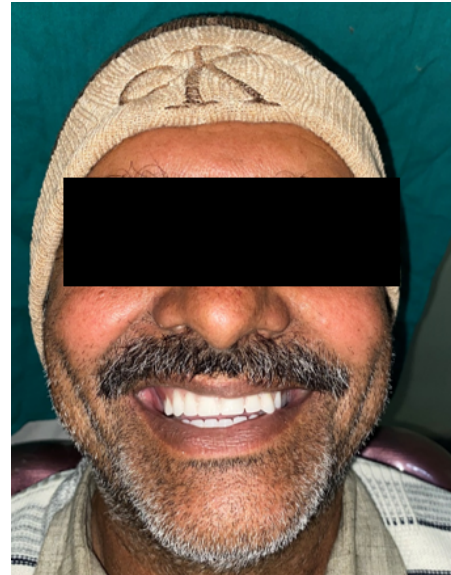

Fig. 29: Patient follow up

Various treatment modalities can be used to manage the flabby tissues. These include surgical and the non-surgical approach. The surgical approach includes the ‘surgical debulking’ involving the removal of hypermobile soft or flabby tissue resulting in a normal compressible denture bearing area. This was a historical concept and is not commonly followed due to elderly patients with compromised medical status. Further, the excision of the flabby tissue results in a shallow ridge providing little resistance to the lateral forces in complete denture. The replacement of the bone with the soft tissue leads to limited availability of the bone; hence, will not be a good option for dental implant placement and rehabilitation. Ridge augmentation using bone grafts can be used as an additive measure both during surgery as well as during dental implant placement but the treatment outcome is still unpredictable and questionable.

This makes the non-surgical or the prosthodontic approach as the choice of treatment modality. According to M.M. DeVan, “the preservation of what remains is important rather than the meticulous replacement of what has been lost”. The management of poor denture bearing area becomes a herculean task for the prosthodontist. Appropriate impression technique and material needs to

be selected by a prosthodontist to record the flabby tissue in an undisplaced form with maximum retention, support, and stability. In addition to the impression making, it is critical to properly orient the occlusal plane, select a suitable occlusal scheme, and provide balanced occlusion in the patient. This can be achieved using face-bow transfer followed by arrangement of the teeth in a semi-adjustable articulator. The incorporation of improperly oriented occlusal plane along with the deflective occlusal contacts will lead to instability of the complete denture.³⁶

The conventional impressions in such situation may lead to the compression, displacement, and distortion of the flabby tissues. This can further lead to elastic recoil of the tissue during function, further leading to instability, dislodgement, and loss of denture retention. This becomes the chief or the presenting complaint of the patient that the denture is 'loose'. A common approach to solve this problem is application of chairside soft reliner for relining the loose dentures. Unfortunately, the existing loose denture acts a custom tray and would further compress and displace the flabby tissues. The tissues will recoil and denture still remains 'loose'.³⁷ Appropriate impression techniques and materials need to be incorporated for managing such situations.

A plethora of impression techniques have been discussed in literature for overcoming the problem of the flabby ridge. To simplify and overcome the limitations of the existing impression techniques, a novel impression technique was developed. This involved the incorporation of a customized prefabricated metal mesh into the maxillary custom tray and impression making using a single step impression technique with polyvinyl siloxane impression material. This was done to eliminate the excessive displacement of the soft tissues at the secondary impression stage and to attain the physiologic and anatomic registration of the attached and the unattached tissues of the denture-bearing areas. The main objective was to record the flabby tissue in an undistorted form with the reproduction of more intricate details and remainder of denture foundation in functional form.³⁸

The main aim of using the customized prefabricated metal mesh in the custom tray was avoidance of multiple escape holes by the operator. There may be a significant error associated with the creation of escape holes depending on the operator. Further, the dimensions of the escape holes may vary; hence, disrupts the standardization of the impression technique. Metal mesh itself acts as a standardized approach to create multiple escape holes in providing relief, and acts as a scaffold for supporting the impression material while setting and pouring the cast. The present technique also employed a single stage impression technique involving a single customized impression tray, which can be easily fabricated. Such a technique can be easily executed. Conversely, a two-tray impression technique is more time consuming and may lead to step

formation during impression making.

The impression material used in the present technique was polyvinyl siloxane because of its shorter setting time, easy mix, adequate tear strength and viscosity, extremely high accuracy, absence of any distortion on removal, ready availability, and good dimensional stability. It is definitely better over the other contemporary materials. The limitations of the impression plaster include the material properties affected by operator's handling technique, taste, and roughness of the material, which may cause the patient to vomit. The limitations associated with zinc oxide eugenol impression material are messiness and a variable setting time due to temperature and humidity. Eugenol is irritating to the soft tissues. This material is nonelastic and may fracture if undercuts are present

The technique described in this paper is not very complex i.e. it is easy to master and is easily completed and well managed even by a general dental practitioner. Moreover, neither extra time nor additional clinical visits are needed for this specialized impression technique and further the construction of a complete denture. The chairside time is minimum and the number of appointments are similar to a conventional complete denture. No extra armamentarium and auxiliary personnel is required for the impression technique. It is definitely an economical procedure.

Certain issues may be associated with this technique. This involves the tricky adaptation of the customized prefabricated metal mesh, difficulty in controlling the thickness of the impression material, and difficult removal of the wax spacer from the metal mesh; particularly, when a tin foil barrier is not used between the wax spacer and the metal mesh.

The advantages of the current impression technique definitely outweigh its limitations. This technique can also be employed in other unconventional edentulous ridge situations; in particular, the knife-edge ridge area. The modified tray design is a patient friendly approach and offers an undisplaced impression of the flabby area with convenience.

Recently, Ștefănescu C-L et al.³⁹ proposed a classification system for flabby ridge based on its various locations and structures. Depending on location, the classification is upper frontal edentulous ridge (very often), upper fronto-lateral edentulous ridge (often), maxillary tuberosity (rare), lower frontal edentulous ridge (very often), lower fronto-lateral edentulous ridge (rare), and retromolar pad (often). Based on the structure, the classification is hyperplastic, keratinized, with high antero-posterior and supero-inferior thickness; atrophic, thin, small antero-posterior thickness and increased supero-inferior length; apparently histological normal appearance at inspection, but with an increased mobility in all the directions.

4. Conclusion

Management of a patient with flabby ridge is an arduous task and presents difficulty in fabrication of a complete denture. The other treatment options i.e. surgery and implants may be effective but not always feasible in the elderly. Conventional impression-taking techniques pose a great challenge to the prosthodontist resulting in fabrication of a prosthesis with compromised retention and stability. The incorporation of the unconventional impression techniques i.e. modified impression techniques and relatively newer impression materials helps to effectively record the flabby tissues in an undistorted fashion. Fortunately, with the inclusion of the digital modalities i.e. CAD-CAM technology or digital dentures, the issues related to the proper recording of the flabby mucosa may become history. Conclusively, the use of the modified impression technique using customized prefabricated metal mesh single custom tray and polyvinyl siloxane impression material provides an alternative, effective and promising approach for the management of patients with flabby ridges.

5. Acknowledgement

The authors would like to acknowledge Vritti Piplani & Tarini Mahajan (BDS final year students) for their immense contribution and support in the publication.

6. Conflict of Interest

The authors declare that there are no conflicts of interest in this paper.

7. Source of Funding


None.


References

- Allen PF, McCarthy F. Complete Dentures from Planning to Problem Solving. London: Quintessence. Publishing; 2003. p. 123–33.
- Appelbaum EM, Rivetti HC. Wax base development for complete denture impressions. *J Prosthet Dent.* 1985;53:663–7.
- Ahmed F, Yunus N, Mccord F. A new presentation of combination syndrome. *Annal Dent Univ Malaya.* 2008;15(2):94–9.
- Allen F. Management of flabby ridge in complete denture construction. *Dent Update.* 2005;32(9):524–6. doi:10.12968/denu.2005.32.9.524.
- Bansal R, Kumar M, Garg R, Saini R, Kaushala S. Prosthodontic rehabilitation of patient with flabby ridges with different impression techniques. *Indian J Dent.* 2014;5(2):110–3.
- Bindhoo YA, Thirumurthy VR, Kurien A. Complete mucostatic impression: a new attempt. *J Prosthodont.* 2012;21(3):209–14. doi:10.1111/j.1532-849X.2011.00810.x.
- The Glossary of Prosthodontic Terms: Ninth Edition. *J Prosthet Dent.* 2017;117(5S):e1–e105. doi:10.1016/j.prosdent.2016.12.001.
- Pai UY, Reddy VS, Hosi RN. A single step impression technique of flabby ridges using monophasic polyvinyl siloxane material: a case report. *Case Rep Dent.* 2014;p. 104541. doi:10.1155/2014/104541.
- Lynch CD, Allen PF. Quality of written prescriptions and master impression for fixed and removable prosthodontics: a comparative study. *Br Dent J.* 2005;198(1):17–20. doi:10.1038/sj.bdj.4811947.
- Kelly E. Changes caused by a mandibular removable partial denture opposing a maxillary complete denture. *J Prosthet Dent.* 1972;27(2):140–50. doi:10.1016/0022-3913(72)90190-4.
- Boucher CO. A critical analysis of mid-century impression techniques for full dentures. *J Prosthet Dent.* 1951;1(4):472–91. doi:10.1016/0022-3913(51)90032-7.
- Carlsson GE. Clinical morbidity and sequelae of treatment with complete dentures. *J Prosthet Dent.* 1998;79(1):17–23. doi:10.1016/s0022-3913(98)70188-x.
- Desjardins RP, Tolman DE. Etiology and management of hypermobile mucosa overlying the residual alveolar ridge. *J Prosthet Dent.* 1974;32(6):619–38. doi:10.1016/0022-3913(74)90071-7.
- Devan MM. Basic principles in impression making. *J Prosthet Dent.* 2005;93(6):503–8. doi:10.1016/j.prosdent.2005.02.007.
- Fokkinga WA, Witter DJ, Bronkhorst EM, Creugers NH. Clinical fit of partial removable dental prostheses based on alginate or polyvinyl siloxane impressions. *Int J Prosthodont.* 2017;30(1):33–7. doi:10.11607/ijp.4977.
- Hyde TP, Craddock H, Brunton P. The effect of seating velocity on pressure within impressions. *J Prosthet Dent.* 2008;100(5):384–9. doi:10.1016/S0022-3913(08)60241-3.
- Imbery TA, Evans DB, Koeppen RG. A new method of attaching cast gold occlusal surfaces to acrylic resin denture teeth. *Quintessence Int.* 1993;24(1):29–33.
- Klein IE, Broner AS. Complete denture secondary impression techniques to minimize distortion of ridge and border tissues. *J Prosthet Dent.* 1985;54(5):660–4. doi:10.1016/0022-3913(85)90245-8.
- Lawson WA. The prosthetic treatment of the elderly. *J Ir Dent Assoc.* 1964;19(2):10–21.
- Osborne J. Two impression methods for mobile fibrous ridges. *Br Dent J.* 1964;117:392–4.
- Watson RM. Impression technique for maxillary fibrous ridge. *Br Dent J.* 1970;128(11):552. doi:10.1038/sj.bdj.4802492.
- Watt D, Roy M, Macgregor A. Designing complete dentures. IOP Publishing. P, Bristol; 1986. p. 21–34.
- Lynch CD, Allen PF. Case report: management of the flabby ridge: re-visiting the principles of complete denture construction. *Eur J Prosthodont Restor Dent.* 2003;11(4):145–8.
- Magnusson BC, Engstrom H, Kahnberg KE. Metaplastic formation of bone and chondroid in flabby ridges. *Br J Oral Maxillofac Surg.* 1986;24(4):300–5. doi:10.1016/0266-4356(86)90097-5.
- Crawford RW, Walmsley AD. A review of prosthodontic management of fibrous ridges. *Br Dent J.* 2005;199(11):715–9. doi:10.1038/sj.bdj.4812968.
- Khan Z, Jagers JH, Shay JS. Impression of unsupported movable tissues. *J Am Dent Assoc.* 1981;103(4):590–2. doi:10.14219/jada.archive.1981.0292.
- Filler WH. Modified impression technique for hyperplastic alveolar ridge. *J Prosthet Dent.* 1971;25(6):609–621.
- Hobkirk JA. Bristol: Wright. In: Complete Dentures da Dental Practitioner Hand book; 1986. p. 44–5.
- Walter JD. Composite impression procedures. *J Prosthet Dent.* 1973;30(4):385–90.
- Grant AA, Johnson W. Removable denture prosthodontics. 2nd Edn. Edinburgh: Churchill Livingstone; 1992. p. 61.
- Macentee MI. The Complete Denture. A Clinical Pathway. Quintessence, Chicago; 1996.
- Labban N. Management of the flabby ridge using a modified window technique and polyvinyl siloxane impression material. *Saudi Dent J.* 2018;30(1):89–93.
- Mccord JF, Grant AA. Impression making. *Br Dent J.* 2000;188(9):484–92. doi:10.1038/sj.bdj.4800516.
- Polychronakis N, Zissis A, Sotriou M. The management of flabby ridge in impression making for a complete denture. *Stomatologis.* 2010;67:171–6.

35. Xie Q, Narhi TO, Nevalainen JM, Wolf J, Ainamo A. Oral status and prosthetic factors related to residual ridge resorption in elderly subjects. *Acta Odontol Scand.* 1997;55(5):306–13. doi:10.3109/00016359709114969.
36. Zinner ID, Sherman H. An analysis of the development of complete denture impression techniques. *J Prosthet Dent.* 1981;46(3):242–9. doi:10.1016/0022-3913(81)90208-0.
37. Lynch CD, Allen PF. Management of the flabby ridge: using contemporary materials to solve an old problem. *Br Dent J.* 2006;200:258–61.
38. Lynch CD, Allen PF. The ‘combination syndrome’ revisited. *Dent Update.* 2004;31(7):410–2. doi:10.12968/denu.2004.31.7.410.
39. Ștefănescu CL, Zaharia A, Murineanu RM, Pușcașu CG, Sachelarie L, Grigorian M, et al. Flabby Ridge, a Challenge for Making Complete Dentures. *Appl Sci.* 2021;11(16):7386.

Author biography

Arpit Sikri, Associate Professor and Post Graduate Teacher
 <https://orcid.org/0000-0002-6273-8882>

Jyotsana Sikri, Associate Professor and Post Graduate Teacher
 <https://orcid.org/0000-0002-0911-1829>

Cite this article: Sikri A, Sikri J. Prosthetic management of flabby ridge using customized prefabricated metal mesh custom tray impression technique: A case report. *IP Ann Prosthodont Restor Dent* 2022;8(1):50-60.