

Content available at: <https://www.ipinnovative.com/open-access-journals>

IP Annals of Prosthodontics and Restorative Dentistry

Journal homepage: <https://www.aprd.in/>

## Case Report

# Complete procedure for custom ocular prosthesis for enucleated eye-Case report

Poonam Wakure<sup>1,\*</sup>, Manu Rathee<sup>1</sup>, Sanju Malik<sup>1</sup>, Maqbul Alam<sup>1</sup>, Sandeep Singh<sup>1</sup>

<sup>1</sup>Dept. of Prosthodontics, Post Graduate Institute of Dental Sciences, Rohtak, Haryana, India



### ARTICLE INFO

#### Article history:

Received 17-12-2021

Accepted 15-01-2022

Available online 16-03-2022

#### Keywords:

Custom made ocular prosthesis

Enucleation

Eye prosthesis

### ABSTRACT

The loss of an eye causes significant functional and cosmetic disfigurement, leads to physical and emotional problems. Rehabilitation of ocular defects is a difficult task that necessitates careful planning of particular case. The patient can return to a state of social and psychological normalcy with a well-built custom prosthesis. This article explains how to make a custom ocular prosthesis for an enucleated eye.

This is an Open Access (OA) journal, and articles are distributed under the terms of the [Creative Commons Attribution-NonCommercial-ShareAlike 4.0 License](https://creativecommons.org/licenses/by-nc-sa/4.0/), which allows others to remix, tweak, and build upon the work non-commercially, as long as appropriate credit is given and the new creations are licensed under the identical terms.

For reprints contact: [reprint@ipinnovative.com](mailto:reprint@ipinnovative.com)

## 1. Introduction

Ocular loss leads to functional disability, facial disfigurement which is extremely stressful and effects overall quality of life. The patient's psychological impairment frequently outweighs his or her physical disability. Rehabilitation of ocular prosthesis should be started soon after healing.<sup>1</sup>

Exenteration is the removal of the complete orbit whereas enucleation is the removal of only the eyeball. Enucleation is often considered treatment of choice for primary intraocular malignancy because it permits histopathologic examination of intact globe.

Each case presents with certain unique characteristics and presence of undercuts, extents of defect which pushes the clinicians to come up with innovative treatment plan. Impression technique and material choice plays a pivotal role in the success of fabrication of ocular prosthesis.<sup>2</sup> This article describes the complete procedure for custom ocular prosthesis for enucleated eye.

## 2. Case Report

A 65 years old male patient reported to the Department of Prosthodontics with the complain of missing left eye and associated unaesthetic appearance since 4 years. The patient gave history of getting operated for glaucoma four and half year before. Following surgery within six-month eye bed got infected and he went for several surgical exploration but wound did not heal and the patient lost his eye. On clinical examination, a completely healed socket was present which is reddish in color with intact surrounding muscle activity. The size of defect from inner canthus to outer canthus approximately was 2.5 cm and depth was 1.5 cm. Partially opening of eye and drooping of upper eyelid was seen. There was slight undercut present with respect to upper eyelid. Treatment objective was made to restore the unesthetic appearance, improve social and psychological confidence of the patient. Fabrication of custom ocular prosthesis is planned using external ocular impression techniques with characterization of corneal shell.

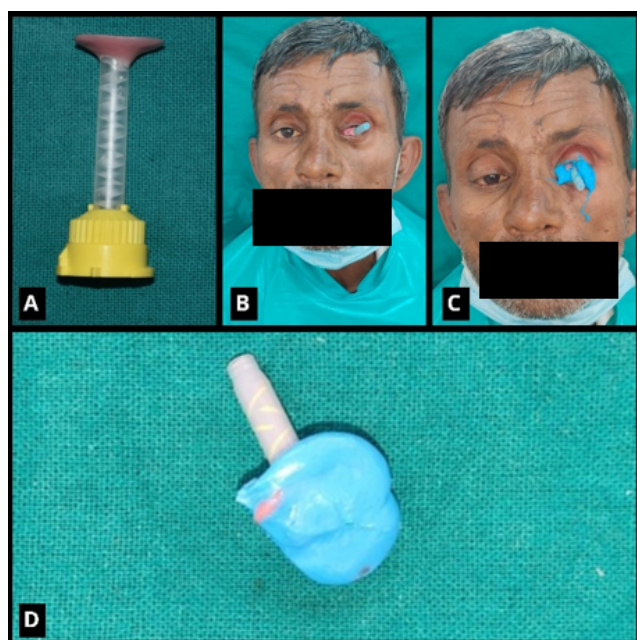
### 2.1. Impression making

The patient's eye socket was coated with vaseline and primary impression was made using the irreversible hydrocolloid (Zelgan, Dentsply) impression material. Oval

\* Corresponding author.

E-mail address: [drpoonamwakure@gmail.com](mailto:drpoonamwakure@gmail.com) (P. Wakure).

shaped perforated acrylic tray attached to the light body dispensing gun was made to record the custom impression. Patient was instructed to seat upright with head supported at the head rest of the dental chair and instructed to hold his gaze in a straight forward position. The custom tray was placed in the socket and impression was made by injecting the light body impression material (Reprosil, Dentsply) through the dispensing gun tip into the custom tray filling the whole eye socket with the material. Patient was asked to close his eye to perform various eye movements to record a functional impression. This will facilitate the functional flow of the impression material to all aspects of the socket. After the material was set, surrounding area of eye were massaged to break the seal. Impression was retrieved and checked for accuracy and excess material was trimmed. Final impression was poured with type III Gypsum (Kalrock, Kalabhai Dental, India) dental stone. Cast was prepared, slight undercut was seen on upper side of cast (Figure 1).

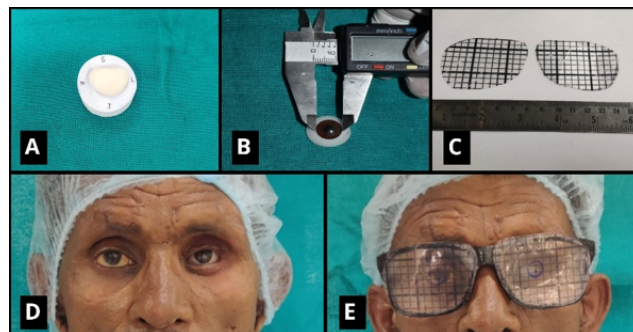


**Fig. 1:** A: Custom tray; B: Placement of custom tray; C: Impression Making; D: Final Impression

## 2.2. Selection and Positioning the Iris

A wax pattern was made by pouring white pattern wax (Maarc, Shiva product, Palghar, India) into the functional defect area of the final cast. Try-in of the wax pattern was done to verify size and support from the tissues in order to achieve ease of simulation of eye movement and eyelid coverage. Vernier calliper was used for measurement of size of contralateral eye's iris. Similar size of the iris approximately 11mm was chosen from the stock eye available. The iris disc was trimmed off from the stock eye

shell to the size of the patient's natural iris. The position of contralateral eye's iris was used as a guide, to mark expected position of iris on a wax pattern. Final positioning of the iris on wax pattern was done using the grided spectacle. Try in was done and any deficits were filled and contoured with wax (Figure 2).



**Fig. 2:** A: Final cast; B: Measurement of iris size using vernier calliper; C: Armamentarium used for orientation, grid sheet and scale; D: Wax Pattern try-in; E: Final iris orientation using Wax pattern try-in along with grided spectacle.

## 2.3. First Flasking, dewaxing and curing

During flasking, the iris disk was secured in its determined position using an acrylic stent. After dewaxing procedure, packing and curing were done with the selected shade of heat cure tooth colored acrylic resin (DPI Heat polymerised tooth colored acrylic resin, Mumbai, India).

## 2.4. Characterization

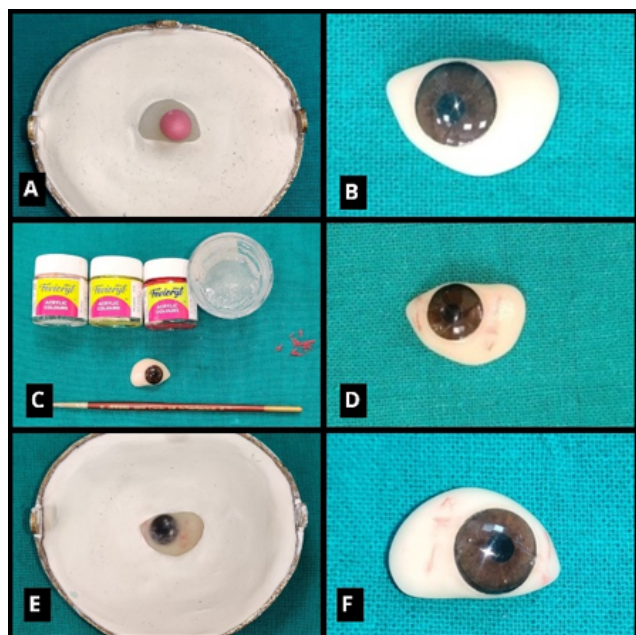
Artist's oil paint colours were mixed with the monopoly syrup and painted on the rough anterior surface of the sclera to match with the patient's eye. Fine threads of red cotton fibres were placed on the sclera on medial and lateral of iris to mimic the blood vessels.

## 2.5. Second Flasking, dewaxing and curing

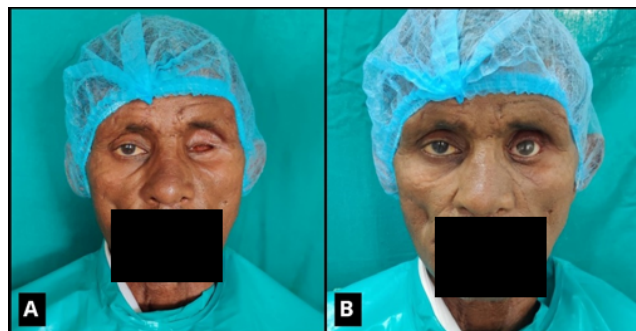After the monopoly syrup was set, 0.5 mm wax was adapted on the eye prosthesis. Flasking, dewaxing and packing was carried out. The flask was closed and kept under bench press and processed. After heat curing of the clear acrylic resin, the prosthesis was finished and polished to obtain a smooth shiny surface (Figure 3).

## 2.6. Insertion

Prosthesis was inserted into the socket, and checked for any areas requiring adjustment. Esthetics and comfort of the patient was evaluated. The patient was educated to insert and remove the prosthesis. Ophthalmic lubricant was advised for lubrication. A pair of plain glasses was advised to make prosthesis more inconspicuous (Figure 4).



**Fig. 3:** A: Flasking with wax pattern mounted with acrylic stent; B: Prosthesis before characterization; C: Armamentarium used for characterization; D: Prosthesis after characterization; E: Second flasking for layer of heat cure clear acrylic on top surface of prosthesis; F: Final prosthesis.



**Fig. 4:** A: Pre-treatment photograph; B: Post-treatment photograph

### 3. Discussion

Ocular defects can be congenital, irreparable trauma, a painful blind eye or tumour.<sup>3</sup> Various treatment options available for missing eye are autogenous surgical reconstruction, prosthetic reconstruction using implants and ocular prosthesis. Ocular prosthesis can be prefabricated or custom made. The techniques for the fabrication of the custom-made ocular prosthesis have several variations particularly in manufacturing of the iris disc and impression technique.<sup>4-6</sup>

Digital images of the contralateral eye or oil paint and the monopoly iris painting technique are used to create the iris. The disadvantages of these procedures include the need for specialised digital photographic equipment

and settings, as well as computer software that allows for picture modifications, and the painting of the paper iris. These techniques are time consuming and requires artistic talents to match the contralateral eye.<sup>7</sup> Advantages of stock iris disk are like more simplicity in fabrication, durable and less time consuming. Prefabricated prosthesis carries potential disadvantages of poor fit, poor esthetics and poor eye movements. A custom ocular prosthesis has advantage of close adaptation to the tissue bed, provides maximum comfort and restores full physiological function to the accessory organs of the eye.<sup>8</sup>

### 4. Conclusion

A person who has lost an eye due to injury or disease can benefit from a prosthetic eye. Patients with ocular abnormalities need to be rehabilitated as soon as possible to help them cope with the stress of losing their eyesight. Custom-made ocular prostheses are the most esthetic and comfortable to this patient.

### 5. Conflict of Interest

The authors declare that there is no conflict of interest.

### 6. Source of Funding

None.

### References

1. Cain JR. Custom ocular prosthetic. *J Prosthet Dent.* 1982;48(6):690–4. doi:10.1016/s0022-3913(82)80030-9.
2. Swarup N. Eye for an Eye: Ocular Prosthesis - A Case Report. *IOSR J Dent Med Sci.* 2018;17(7):36–43.
3. Raflo GT. Enucleation and evisceration. Duane's. *Clin Ophthalmol.* 1995;5:1–25.
4. Taicher S, Steinberg HM, Tubiana I, Sela M. Modified stock-eye ocular prosthesis. *J Prosthet Dent.* 1985;54(1):95–103. doi:10.1016/s0022-3913(85)80079-2.
5. Benson P. The fitting and fabrication of a custom resin artificial eye. *J Prosthet Dent.* 1977;38(5):532–8. doi:10.1016/0022-3913(77)90029-4.
6. Beumer J, Zlotolow I. Restoration of facial defects: Etiology, disability, and rehabilitation. *Maxillofacial Rehabilitation: Prosthodontic and Surgical Considerations.* St. Louis: Mosby; 1979. p. 311–71.
7. Artopoulou II, Montgomery PC, Wesley PJ, Lemon JC. Digital imaging in the fabrication of ocular prostheses. *J Prosthetic Dent.* 2006;95(4):327–30. doi:10.1016/j.prosdent.2006.01.018.
8. Pun SN, Shakya R, Adhikari A, Parajuli PK, Singh RK, Suwal P, et al. Custom Ocular Prosthesis for Enucleated Eye: A Case Report. *J Common Market Study Nepal.* 2016;12(3):127–30. doi:10.3126/jcmns.v12i3.16018.

### Author biography

**Poonam Wakure**, Post Graduate Student

**Manu Rathee**, Senior Professor and Head

**Sanju Malik**, Senior Resident

**Maqbul Alam**, Post Graduate Student

**Sandeep Singh**, Post Graduate Student

**Cite this article:** Wakure P, Rathee M, Malik S, Alam M, Singh S. Complete procedure for custom ocular prosthesis for enucleated eye-Case report. *IP Ann Prosthodont Restor Dent* 2022;8(1):46-49.