

Content available at: <https://www.ipinnovative.com/open-access-journals>

IP Annals of Prosthodontics and Restorative Dentistry

Journal homepage: <https://www.aprd.in/>

Case Report

Amputation to rehabilitation' - silicone finger prosthesis: A case report

Harsh Rathee¹, Parag Dua^{1,*}, Saurav Kumar¹

¹Dept. of Dental Surgery and Oral Health Sciences, Armed Forces Medical College, Pune, Maharashtra, India



ARTICLE INFO

Article history:

Received 16-01-2022

Accepted 27-01-2022

Available online 16-03-2022

Keywords:

Silicone Finger prosthesis

Anatomical undercuts

Mechanical mode of retention

ABSTRACT

In patients where surgical reconstruction of amputated finger is not possible, a finger prosthesis provides psychological, functional and esthetic rehabilitation. The success of the prosthesis depends on the meticulous planning, precise impression procedures, designing of prosthesis and selection of appropriate materials. This clinical report presents a case of rehabilitation of a patient with three amputated fingers due to trauma by the chaff machine. The amputation was at different digit levels. The patient was successfully rehabilitated with a custom made silicone finger prosthesis fabricated from room temperature vulcanizing (RTV) silicone utilizing anatomical and mechanical modes of retention.

This is an Open Access (OA) journal, and articles are distributed under the terms of the [Creative Commons Attribution-NonCommercial-ShareAlike 4.0 License](https://creativecommons.org/licenses/by-nc-sa/4.0/), which allows others to remix, tweak, and build upon the work non-commercially, as long as appropriate credit is given and the new creations are licensed under the identical terms.

For reprints contact: reprint@ipinnovative.com

1. Introduction

Paraoral defects may be congenital or acquired due to traumatic injuries.^{1,2} Rehabilitation of paraoral deformities resulting due to loss of ear, eye, nose or fingers presents a pertinent challenge to the prosthodontist.

The loss of finger has a tremendous physical and emotional impact on the individual. A high-quality aesthetic prosthesis with passive function goes a long way in providing psychological comfort to the patient.³ This case describes about rehabilitation of patient with amputated digits with a custom made silicone finger prosthesis fabricated from RTV silicone.

2. Case Report

This report describes the rehabilitation of a 28 years old male patient whose index, middle and ring fingers of the right hand were partially severed, one year back while operating a chaff machine. There was loss of basic functions such as difficulty in holding objects as well as writing.

The patient presented to the division for the replacement of his amputated fingers. Clinical examination revealed that the remaining stumps of the index, middle and ring fingers were approximately 19mm, 14mm and 16mm respectively (Figure 1). The surrounding region had healed satisfactorily. Various treatment options were presented to patient like implant retained finger prosthesis and customized silicone prosthesis. Since patient was not consenting for any surgical procedure, treatment plan for customized silicone prosthesis was formulated.

A thin layer of petroleum jelly was applied, to the patient's amputated finger stumps and the adjacent area to prevent the adherence of impression material to the skin as well as hair. Impression of stumps was made using irreversible hydrocolloid (Alginate, Zelgan plus) (Figure 2). Patient was instructed to keep the hand in an unstretched, resting position during the impression procedure. The impression was poured in type-III gypsum product (Kalstone, Kalabhai, Mumbai: India) and the working cast obtained (Figure 3). This was scored to enable precise adaptation of the wax pattern at a later stage.

* Corresponding author.

E-mail address: duaparag@gmail.com (P. Dua).

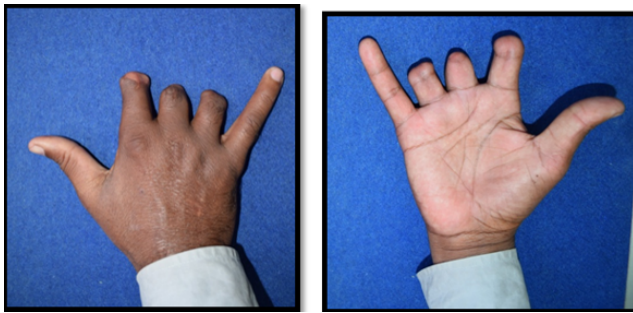


Fig. 1: Preoperative dorsal and ventral of right hand with amputated digits

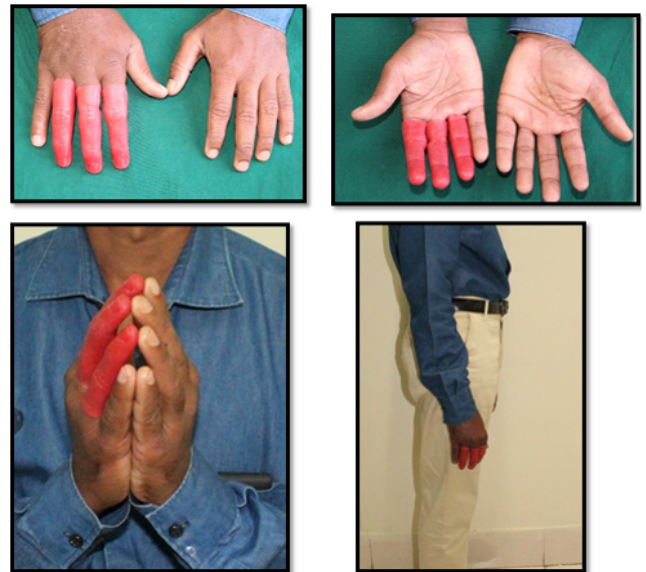


Fig. 4: Wax pattern trial after hollowing out of wax pattern fabricated using donor impression



Fig. 2: Impression with irreversible hydrocolloid impression material



Fig. 5: Putty index for fabrication of artificial nails.

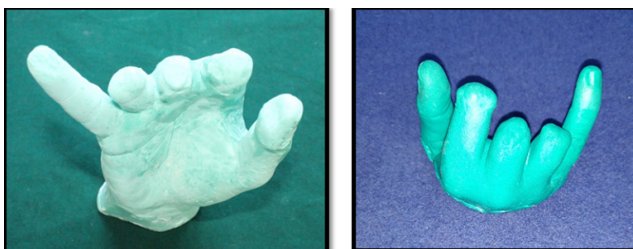


Fig. 3: Master cast of amputated digits

A donor with almost same size and shape as that of patient's fingers was selected. Donor's impressions were made using similar procedure and wax pattern was fabricated. Wax pattern was then hollowed out and adapted to patient's scored working cast. Sculpting and characterization was done and the finalized pattern was tried onto patient and checked for medial, lateral, dorsal as well as ventral aspects of the index finger, middle finger and ring finger (Figure 5). Retention and fit was checked during wax pattern try in. A slit in nail bed region of wax pattern




Fig. 6: Processing of RTV silicone prosthesis dorsal and ventral aspect



Fig. 7: Processed prosthesis dorsal and ventral aspect

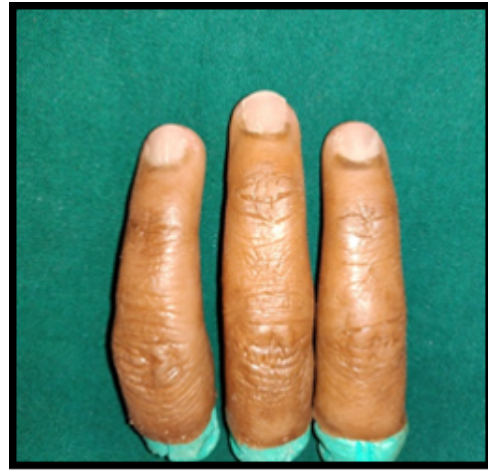

Fig. 10: Final finger prosthesis post nails attachment

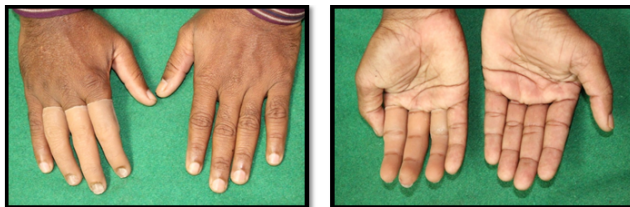

Fig. 8: Trial of final silicone prosthesis dorsal and ventral aspect

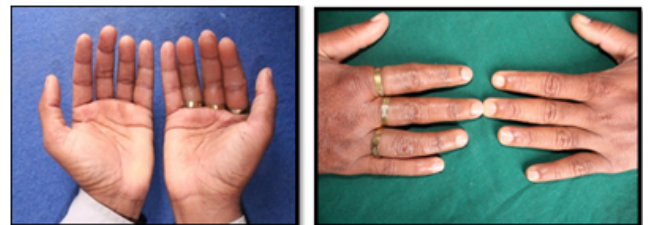

Fig. 11: Final prosthesis in situ

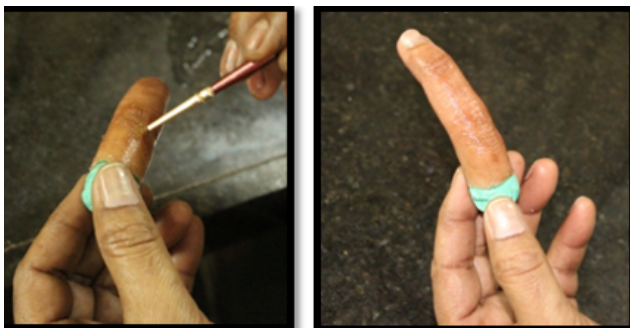

Fig. 9: Characterization of prosthesis



Fig. 11: Final prosthesis in situ




Fig. 12: Restoration of function.

was incorporated to accommodate artificial nails. Artificial fingernails were fabricated with clear autopolymerizing acrylic resin using putty index of patient's unaffected left hand. They were characterized using extrinsic pigments and were attached to the final silicone prosthesis prior to delivery (Figure 5).

After achieving satisfactory results at try-in, pattern was flaked using conventional steps. The first pour was done until the junction of the dorsal and ventral surfaces which would enable us to give demarcating line between dorsal and ventral halves of the prosthesis.

Shade matching of the dorsal and ventral surface was done separately under natural light. Medical grade RTV silicone was mixed and base colour using intrinsic stains

was achieved. Dorsal and ventral surfaces was layered separately onto the negative mold and were packed. Trial closure was done using clamp and flask. Silicone was processed at room temperature (24°C) and bench cured overnight (Figures 6 and 7).

Final prosthesis was retrieved flash was trimmed using a sharp BP knife. The prosthesis was inserted onto amputated fingers to check the shade as well as the fit. Characterization was carried out for dorsal surface of the prosthesis. Customized acrylic nails were attached using commercially available cyanoacrylate adhesive. It was positioned so that edges of nail fit precisely inside the “slit” along crease of nail bed area. Final finishing of prosthesis was accomplished using silicone finishing burs (Figures 8, 9 and 10). Rings of appropriate size and diameter were chosen to mask the prosthesis margins at the skin surface. These aided in mechanical retention as well. The prostheses was inserted and evaluated for fit and retention (Figure 11). There being no complaints, it was finally delivered to the patient.

Home care instructions included correct technique of insertion and removal of prosthesis, cleaning of amputated site and the prostheses. Patient was reviewed after 3 months, skin was healthy and retention of prosthesis was unchanged. Patient was able to accomplish minor basic functions, such as holding of light objects and minor writing procedures. Patient was highly satisfied with the prosthesis in terms of retention and colour match. (Figure 12).

3. Discussion

Prosthetic rehabilitation of amputated digits using customized RTV silicone prosthesis is a conservative and viable treatment option. Various materials such as wood, clay, leather, acrylic resin, and silicone elastomers have been used for fabrication of extraoral prosthesis. Among these, acrylic resin and silicone are most commonly used materials for rehabilitation.^{4,5}

Acrylic resin is hard and does not provide any mobility, thus giving a more artificial appearance. Silicone is more flexible and compatible with intrinsic and extrinsic staining, thus providing a more life-like appearance. However, due to environmental factors, silicones are prone to discoloration and may need frequent replacement.^{6,7}

Mechanical retention is another factor that should be considered while fabricating finger prosthesis. Adhesives, ring, magnets and mini implants are the various modes of mechanical retention for silicone prosthesis. Implants provide good retention and are more durable. However, they need surgical intervention and are expensive.⁸ Apart from being highly esthetic and easy to handle, silicone finger prosthesis provides excellent wearer comfort.

Anatomically retained silicone prosthesis was chosen for this patient since patient was unwilling for any surgical intervention. Silicone was preferred over acrylic prosthesis as it is flexible and provided more life like appearance to the prosthesis.

4. Conclusion

Anatomically retained silicone prosthesis is a cost effective, aesthetically acceptable, easy to insert and retrieve. Customized silicone finger prosthesis provided a good alternative treatment option for rehabilitation of amputated digits providing near normal function and life-like appearance to an individual. Incorporation of intrinsic pigments improved the esthetics. Attaching rings provided mechanical retention and was also helpful in masking prosthesis margins. Rehabilitation of patient with customized silicon finger prostheses yielded excellent results thereby restoring form, partial function, esthetics and psychological well being of patient.

5. Conflict of Interest

The authors declare that there is no conflict of interest.

6. Source of Funding

None.

References

- Shelly S, Pooran C, Saumyendra VS, Shuchi T. Modifications to simplify fabrication of finger prosthesis: a case series. *J Prosthet Orthot.* 2011;23(1):30–3.
- Chalian VA, Drane JB, Standish SM. Maxillofacial prosthetics: multidisciplinary practice, 1st edn. Baltimore: Williams & Wilkins Co; 1971. p. 286–8.
- Mackin EJ, Skiwen T, Callahan AD, Scheider L, Osterman L. Rehabilitation of the hand and upper extremity, 5th edn. St. Louis: Mosby Co; 2002. p. 1469–72.
- Gary JJ, Smith CT. Pigments and their application in maxillofacial elastomers: A literature review. *J Prosthet Dent.* 1998;80(2):204–8. doi:10.1016/s0022-3913(98)70111-8.
- Raghu KM, Gururaju CR, Sundaresh KJ, Mallikarjuna R. Aesthetic finger prosthesis with silicone biomaterial. *BMJ Case Rep.* 2013;p. bcr2013010385. doi:10.1136/bcr-2013-010385.
- Kini AY, Byakod PP, Angadi GS, Pai U, Bhandari AJ. Comprehensive prosthetic rehabilitation of a patient with partial finger amputations using silicone biomaterial: A technical note. *Prosthet Orthot Int.* 2010;34(4):488–94. doi:10.3109/03093646.2010.486391.
- Beumer J, Curtis TA, Firtell DN. Maxillofacial Rehabilitation. St. Louis: The C.V. Mosby Co; 1979.
- Reddy R, Bandela V, Bharathi M, Reddy G. Acrylic finger prosthesis: A case report. *J Clin Diagn Res.* 2014;8(8):ZD07–8. doi:10.7860/JCDR/2014/8800.4658.

Author biography

Harsh Rathee, Resident

Parag Dua, Associate Professor and Instructor

Saurav Kumar, Assistant Professor and Instructor

Cite this article: Rathee H, Dua P, Kumar S. Amputation to rehabilitation' - silicone finger prosthesis: A case report. *IP Ann Prosthodont Restor Dent* 2022;8(1):42-45.